

«ICSI Procedure and advanced techniques in medically-assisted procreation»

Second-Cycle Degree Course in “REPRODUCTIVE BIOTECHNOLOGIES”

A.Y. 2021- 2022

Teramo, 28-30Marzo 2022

Ilaria Listorti
Head of Villa Mafalda ART lab
ilistorti@unite.it

MAIN TOPICS


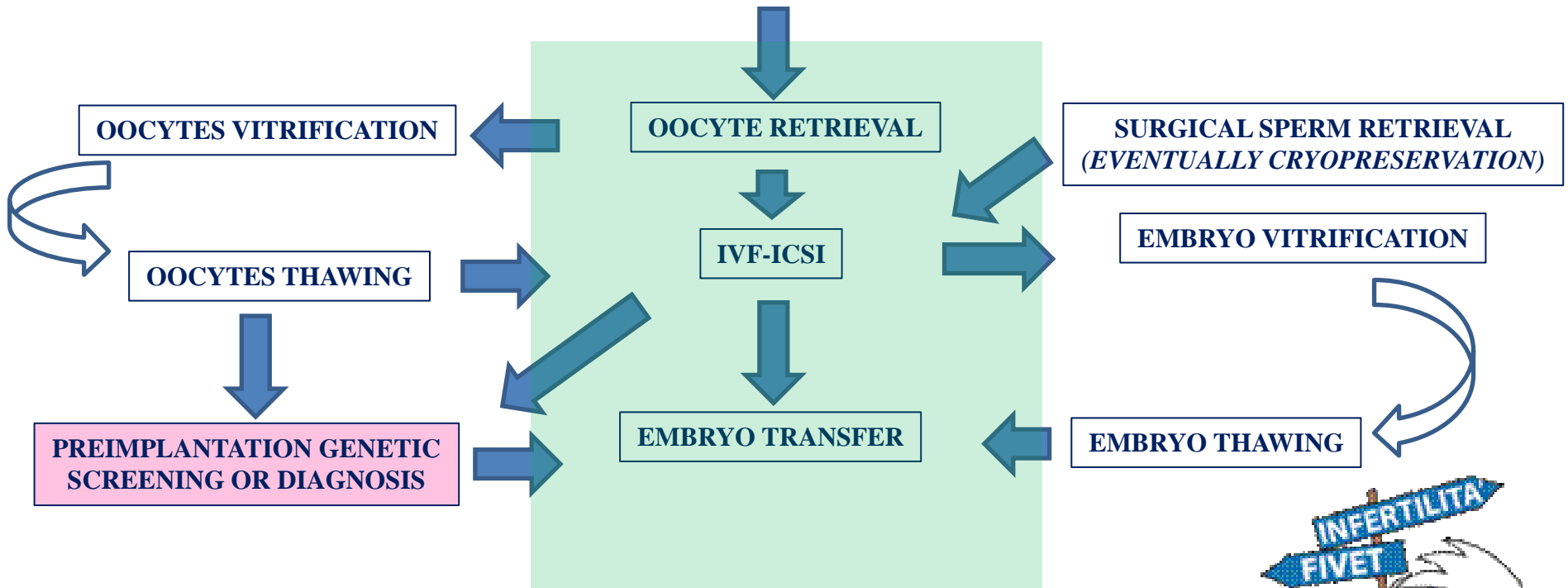
- ASSISTED REPRODUCTIVE TECHNIQUES

- The oocyte retrieval (*Pick-Up*);
- In-vitro* insemination;
- Intracytoplasmatic Sperm Injection (*ICSI*);
- Assisted zona hatching;
- Blastocyst biopsy;
- Pre-implantation genetic diagnosis and embryo screening;
- Vitrification of oocytes and embryos.

THEROICAL LESSON

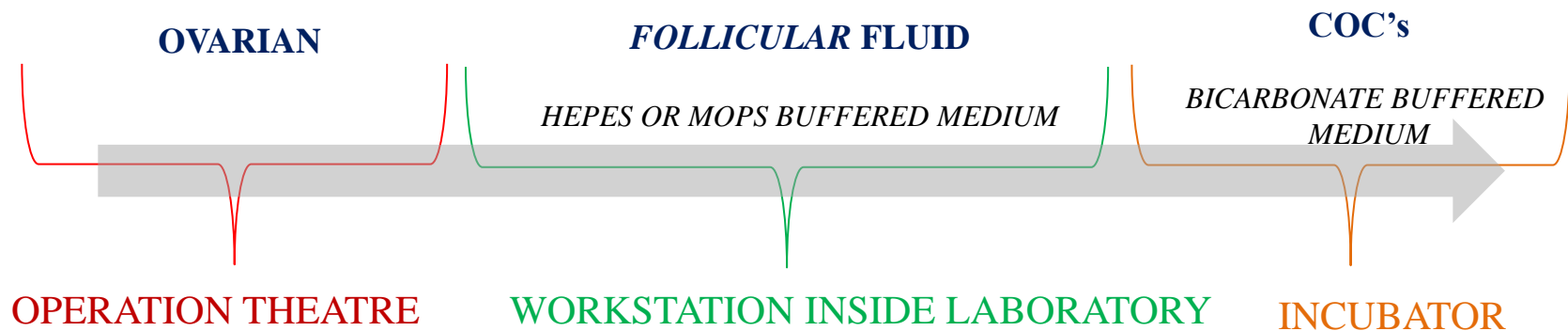
FOLLICULAR GROWTH MONITORING

**INTRA-UTERINE
INSEMINATION (IUI)**



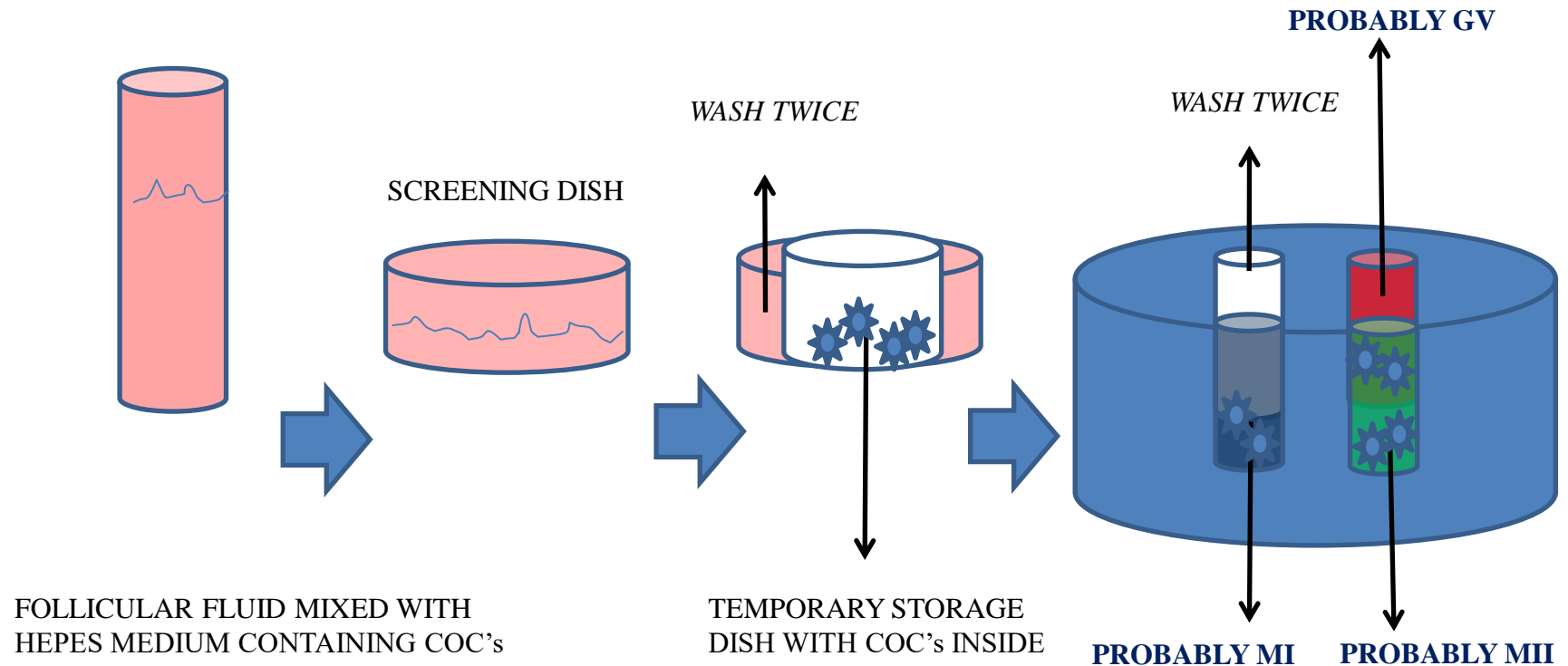
“PICK-UP”: THE OOCYTE RETRIEVAL

- PERFORMED INSIDE THE THEATRE UNDER ANESTHESIA (PROPOFOL) IN PRESENCE OF ANESTHESIST, GYNECOLOGYST, NURSE AND BYOLOGYST
- ULTRASOUND-GUIDED WITH 17 GAUGE NEEDLE (FOLLICULAR PUNCTURE)
- PERFORMED 35 (URINARY HCG) OR 36-38 (RECOMBINANT HCG OR GNRH-AGONIST) HOURS AFTER HCG ADMINISTRATION



“PICK-UP”: THE OOCYTE RETRIEVAL

The cumulus-oocyte-complexes are *retrieved from follicular fluid*, washed and *stored temporary in a clean dish* filled of Hepes Buffered Medium. At the end of pick-up, COC's are *sorted by nuclear stage maturity* in a new 4 well dish (bicarbonate buffer medium filled) and left in a CO₂/O₂ incubator for 3 hours.




Medium utilized:

HTF/wHEPES

HTF

“PICK-UP”: THE OOCYTE RETRIEVAL



**COC's WHASHING
AREA**

**COC's STORAGE
AREA**


TEMPORARY STORAGE CENTER WELL DISH
FOR COC's PRIOR TO INCUBATION



4 WELL DISH FOR COC's INCUBATION
AFTER OOCYTE RETRIEVAL

“PICK-UP”: THE OOCYTE RETRIEVAL

Keep attention: working temperature and timing of COC's outside incubator.



←
**“PASS BOX” (IN
ORDER TO
MAINTAIN
ASEPTIC
CONDITIONS)**


TERMOBLOCK

**WORKSTATION
HEATED STAGE**

**(..TO MANTAIN THE CORE BODY
TEMPERATURE)**

IN-VITRO INSEMINATION

3 hours after retrieval: we have to choose the technique!



CONVENTIONAL *IN-VITRO* INSEMINATION (FIVET)

- TUBAL OBSTRUCTION
- NORMAL TO MODERATE OAT SEMEN SAMPLE
- ENDOMETRIOSIS
- PREVIOUS FAILURE WITH I.U.I.

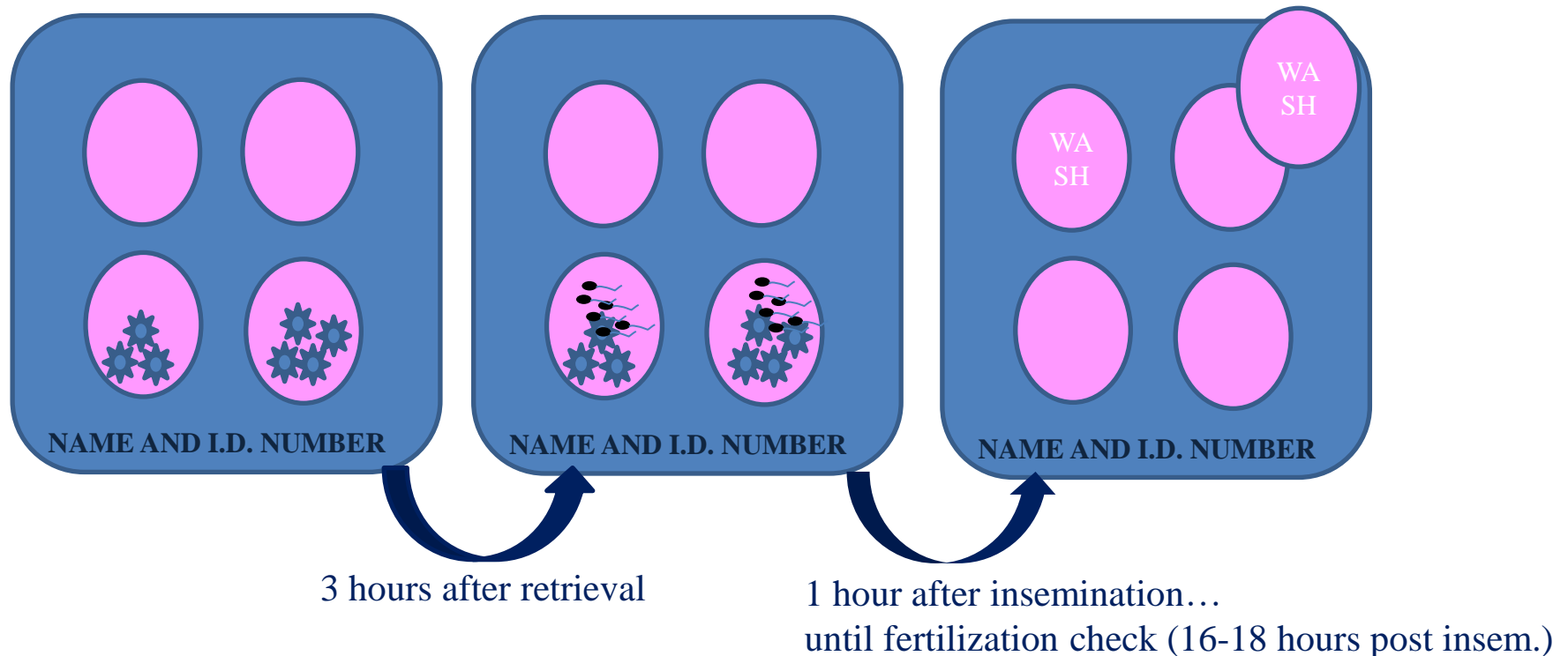
INTRACYTOPLASMATIC SPERM INJECTION (ICSI)

- MODERATE TO SEVERE OAT SEMEN SAMPLE
- CHIRURGIC SPERM RETRIEVAL (TESE/TESA/MESA)
- OOCYTE THAWING
- NO TO LOW FERTILIZAION RATE AFTER FIVET

CONVENTIONAL *IN-VITRO* INSEMINATION


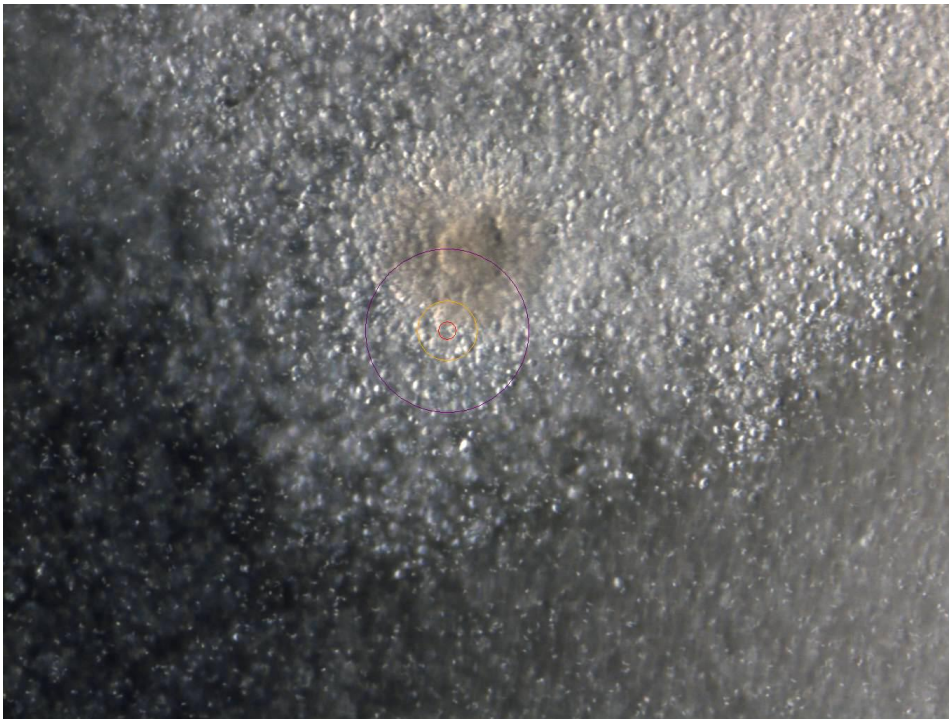
FIVET must be performed after 3 hours of incubation. The COC's are able to reach the cytoplasmic and nuclear maturity.

Optimal sperm concentration inside each well is 100.000 motile spz/COC.



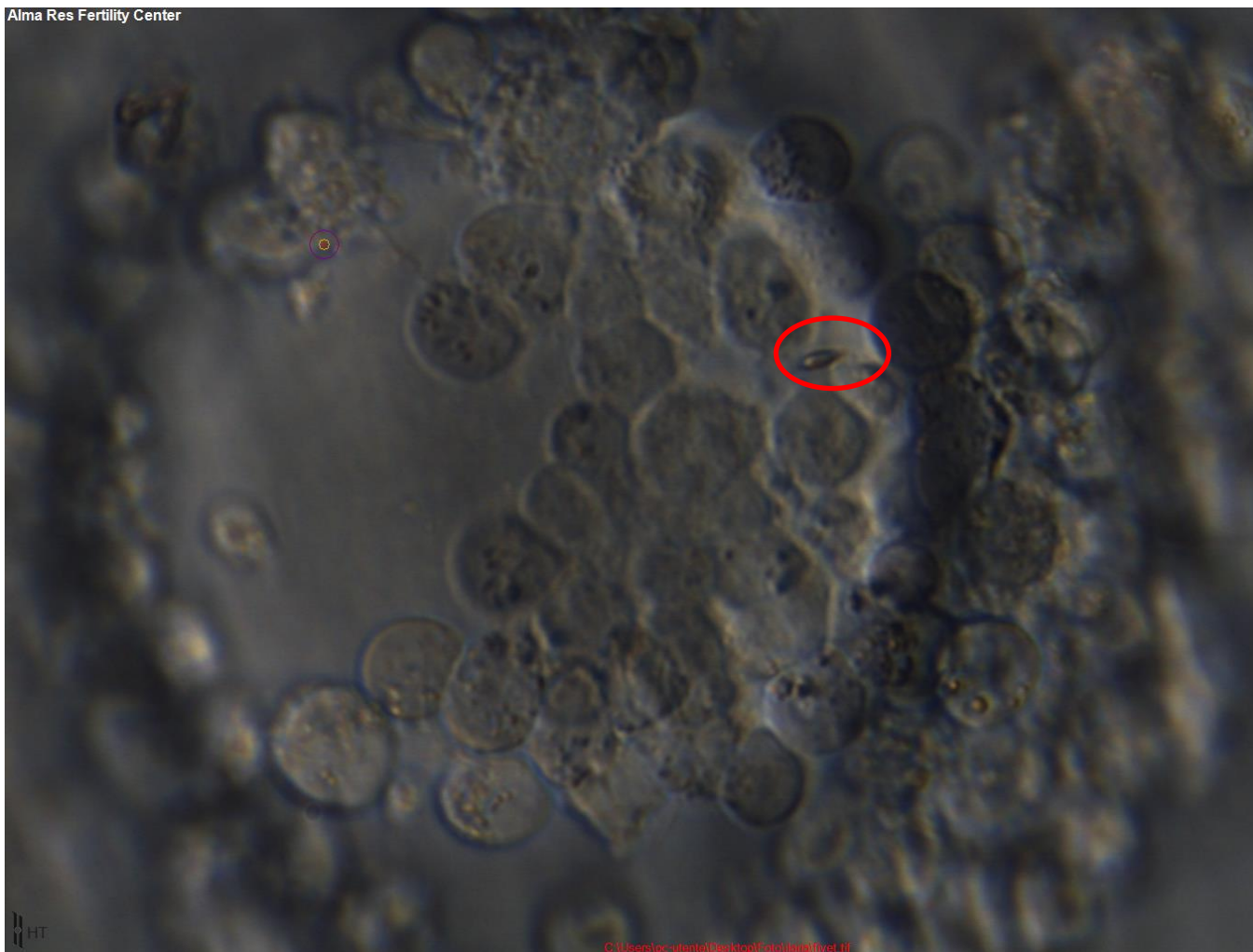
Medium utilized: **HTF** ("Human Tubal Fluid") (*Quinn, P.*)

CONVENTIONAL IN-VITRO INSEMINATION



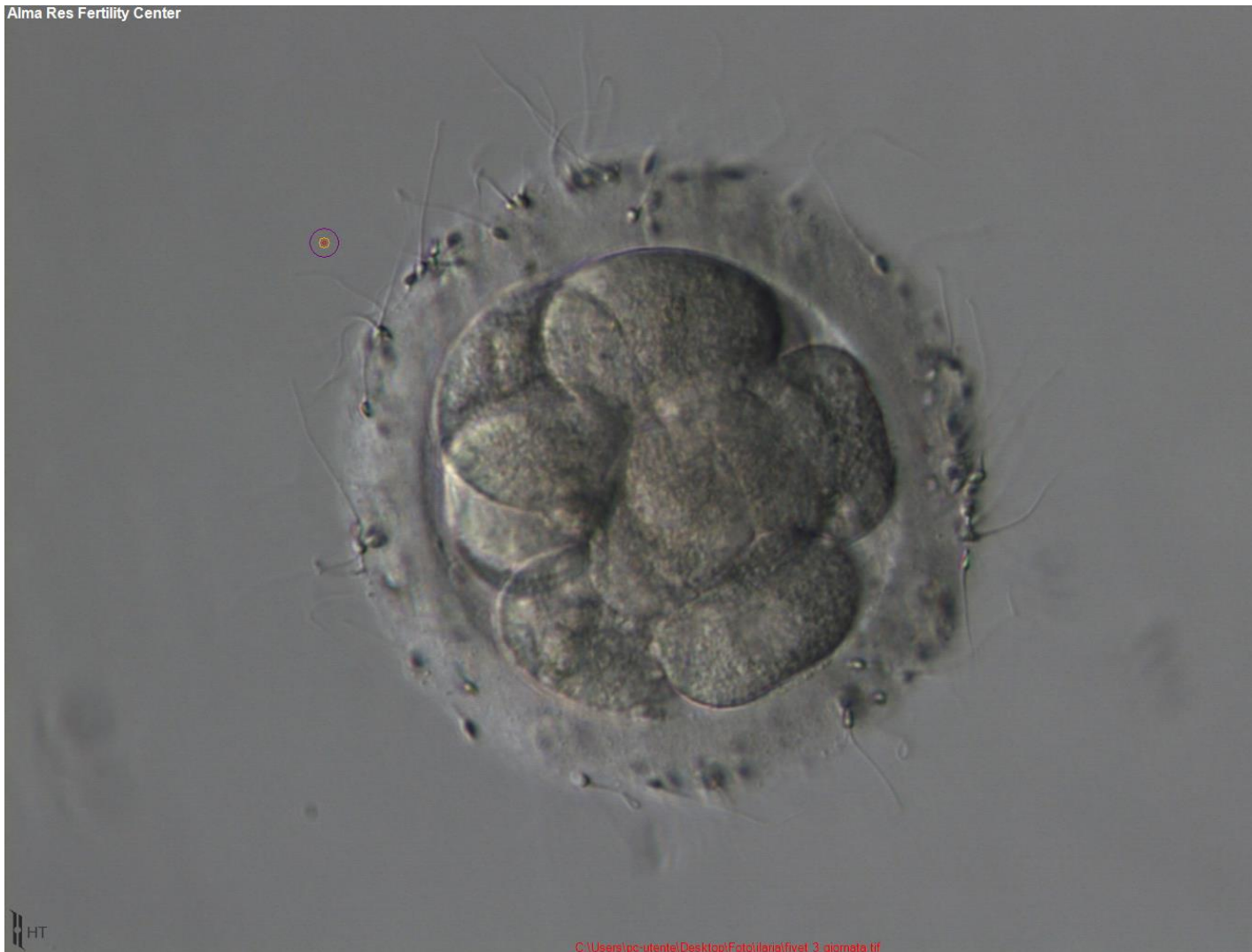
CONVENTIONAL IN-VITRO INSEMINATION

Alma Res Fertility Center



CONVENTIONAL IN-VITRO INSEMINATION

Alma Res Fertility Center

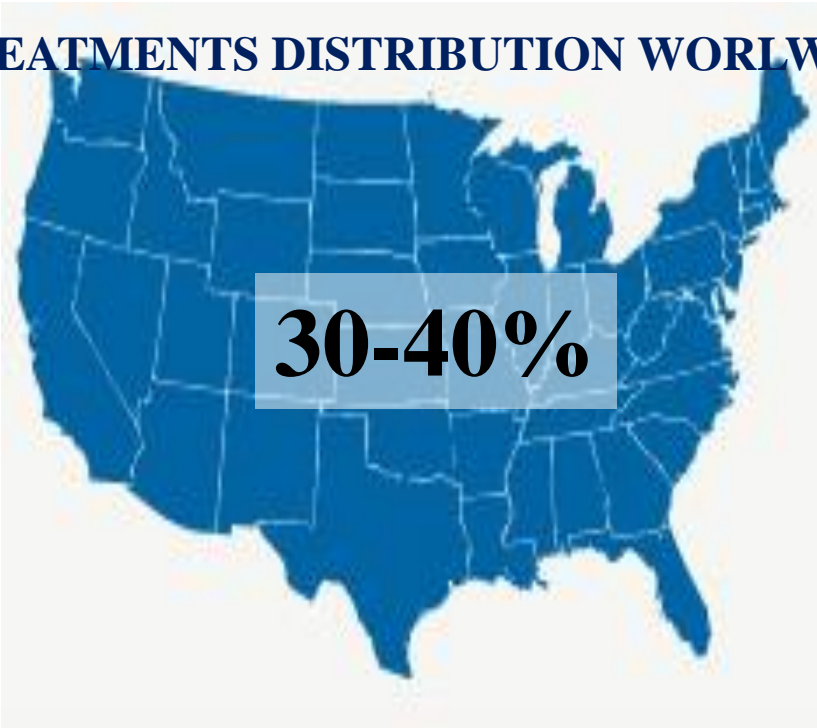


CONVENTIONAL IN-VITRO INSEMINATION

FIVET TREATMENTS DISTRIBUTION WORLDWIDE



10-20%



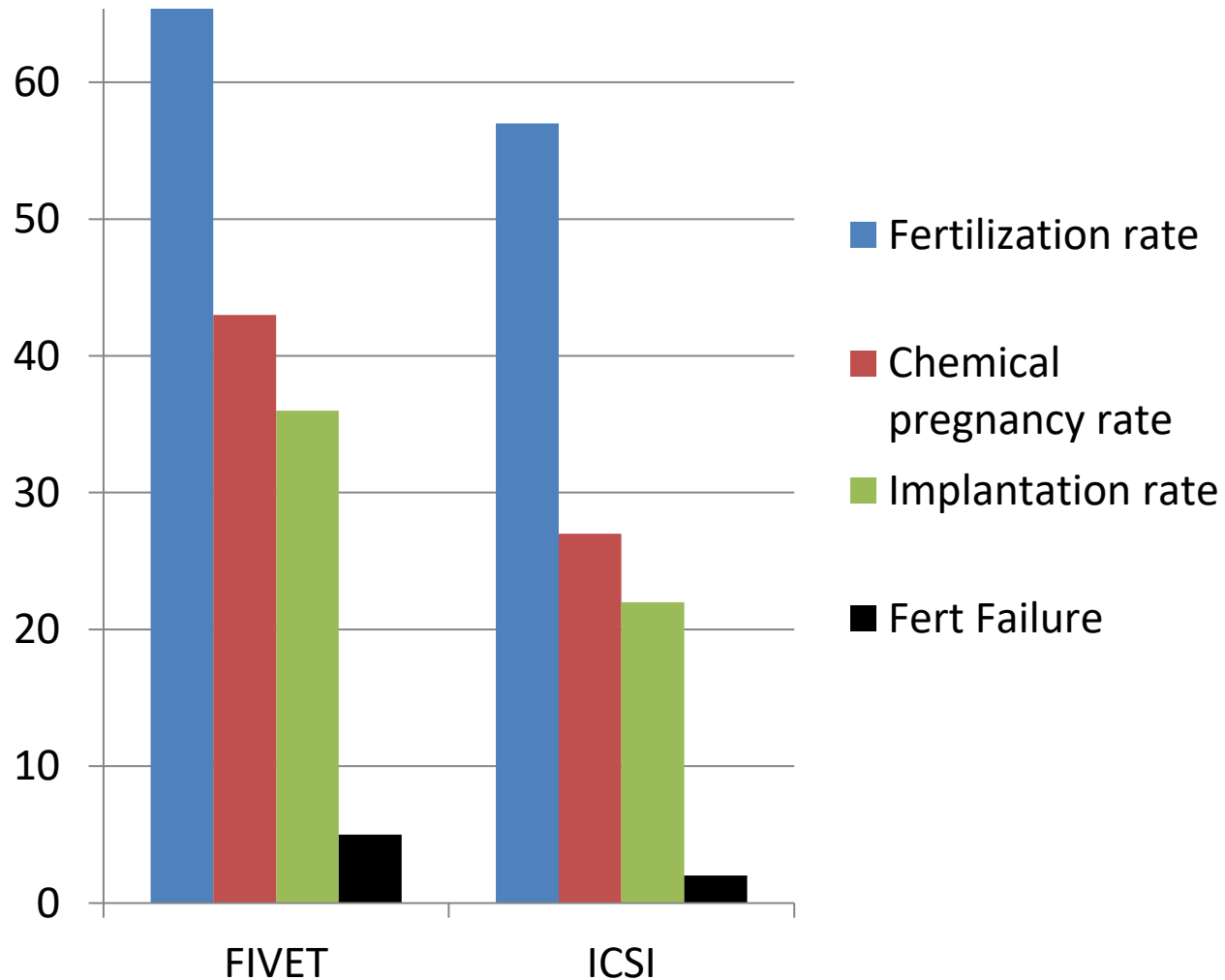
30-40%



> 50%

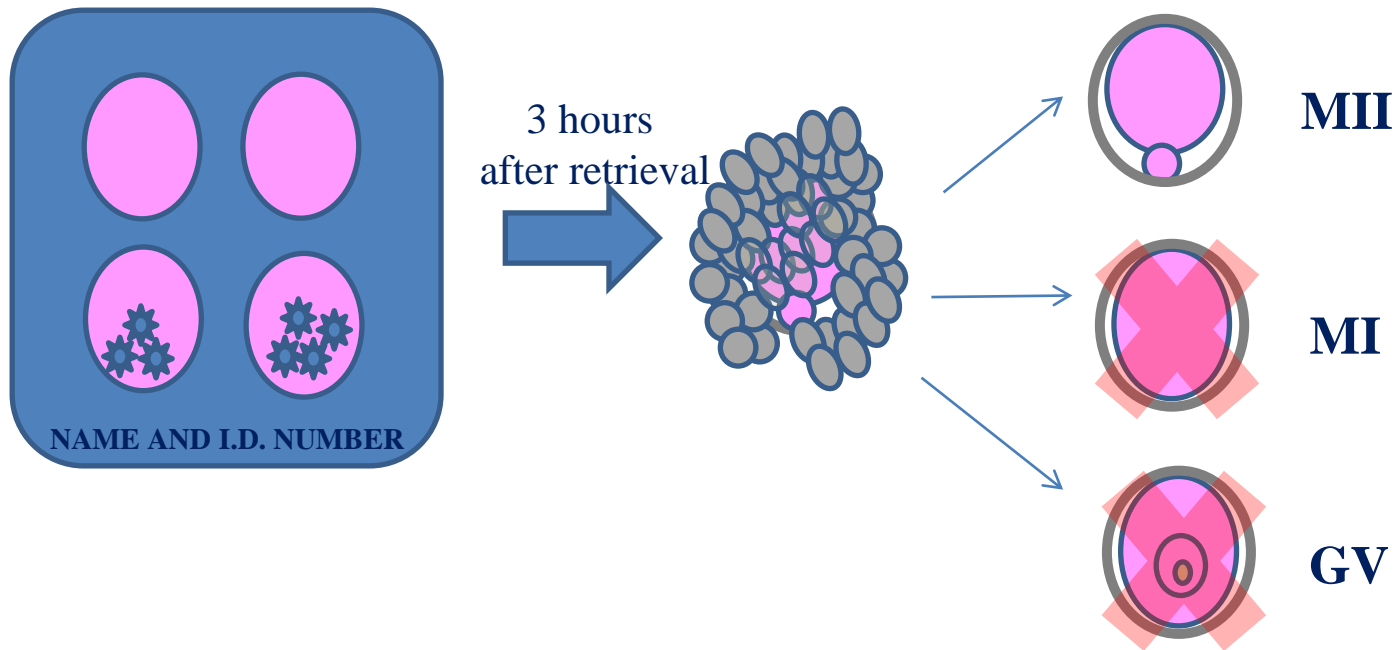
Due to the mean age of the patients and the mean percentage of oocytes harvested, in Europe biologist perform ICSI also when unnecessary.

CONVENTIONAL IN-VITRO INSEMINATION



INTRA- CYTOPLASMATIC SPERM INJECTION (ICSI)

ICSI must be performed after 3 hours of incubation: during washing of sperm and capacitation, the COC's are able to reach also the cytoplasmic maturity. But, differently to fivet, we must to remove the cumulus cells and check for the nuclear maturity of each oocytes harvested. Immediately, we have to perform ICSI only on MII oocytes.



Keep attention: oocyte denuding can be performed in HTF without hepes for skilled embryologist. During training, it's better to use HTF with hepes in ordet to avoid the pH rise outside incubator.

CUMULUS-ENCLOSED OOCYTES

During the preovulatory growth, within the follicle, the oocyte is surrounded by two different somatic cell layers: *granulosa* and *thecal cells* that sustain oocyte nutrition and maturation providing essential metabolites, hormones, and growth factors.

The outer CCs separated from each other by extracellular matrix



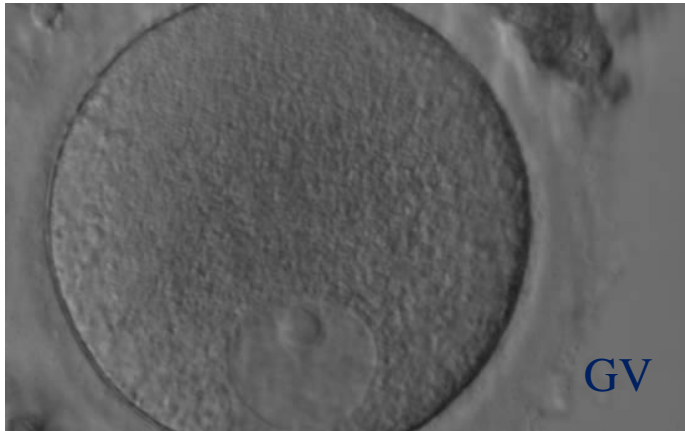
The corona cells (granulosa) immediately adjacent to the oocyte becoming less compact and radiating away from the ZP.

OOCYTE DENUDING

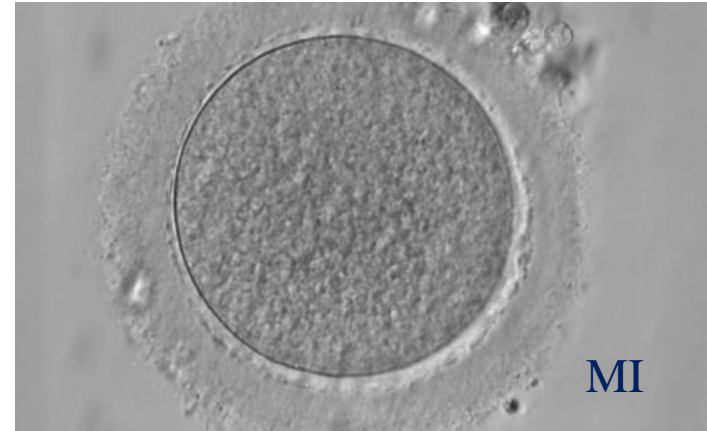

<https://www.youtube.com/watch?v=xl1Hd8CZxnM>

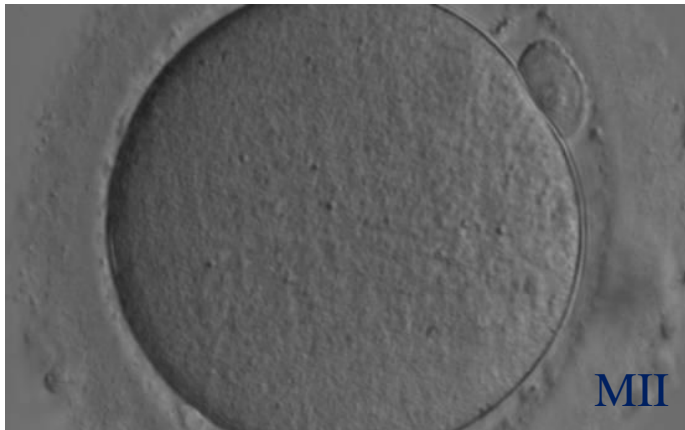
OOCYTE MATURATION STAGE



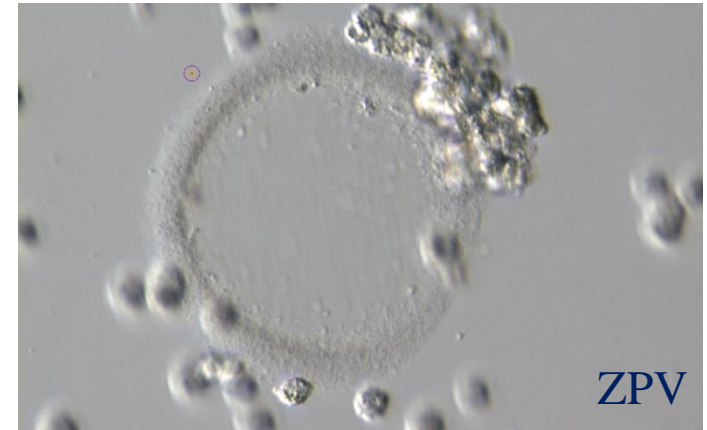
GV oocyte with an eccentrically placed nucleus and a prominent single nucleolus



MI oocyte. This oocyte has no visible nucleus and has not as yet extruded the PBI

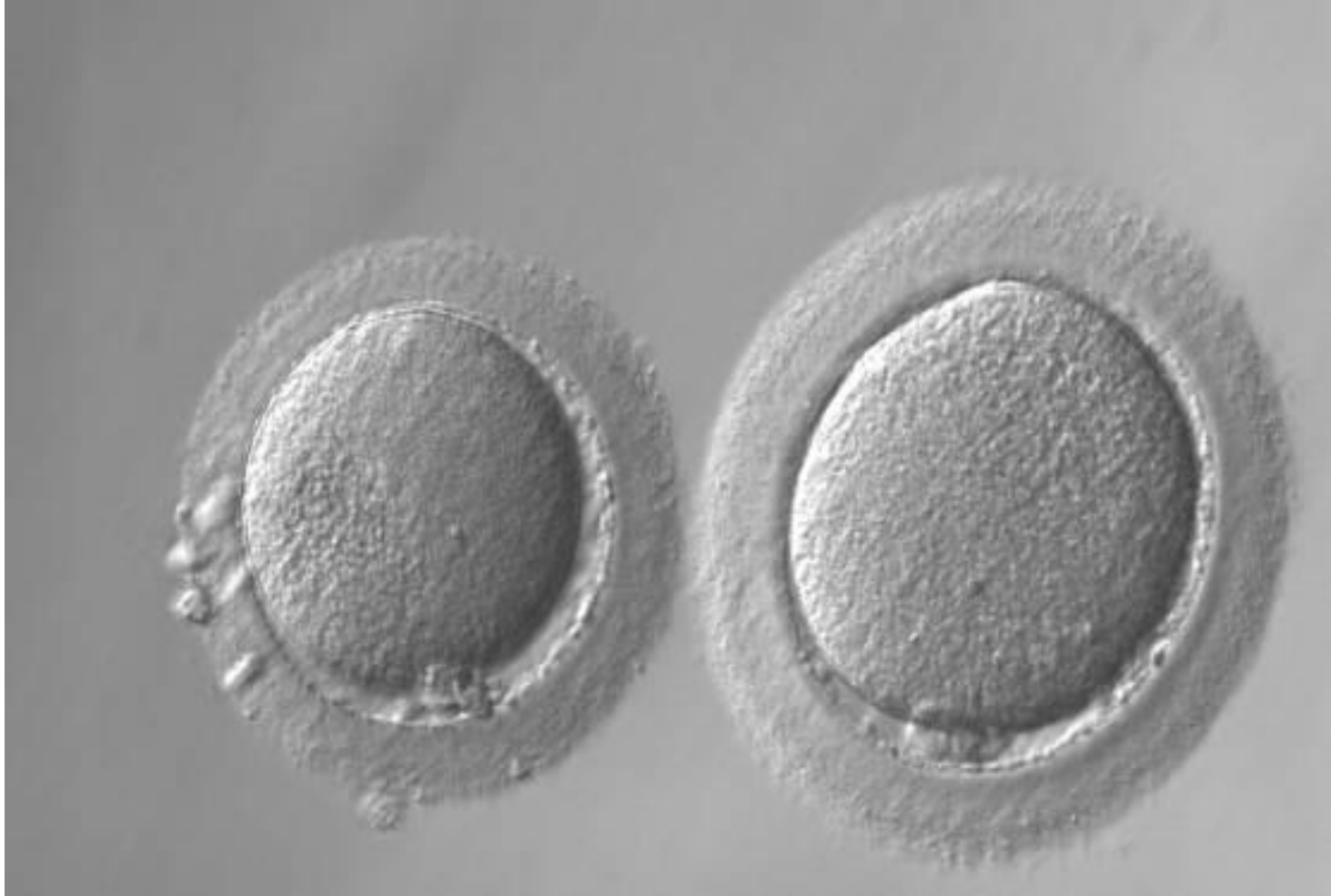

Denuded MII oocyte; an intact PBI is clearly visible in the PVS



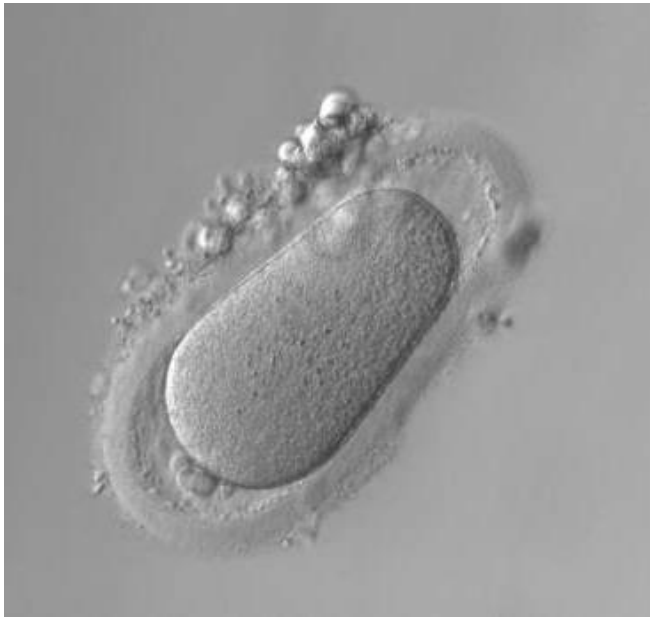An empty zona pellucida

OOCYTE SIZE AND SHAPE

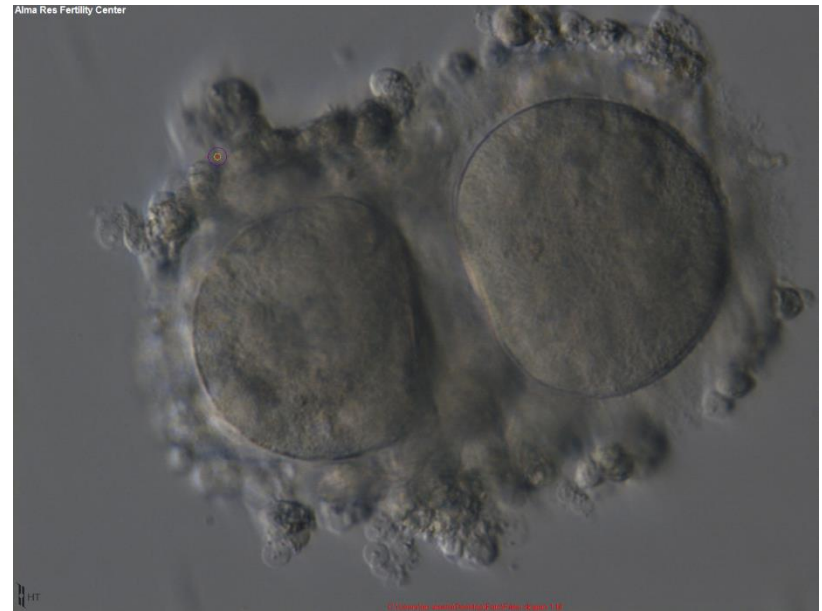


Normal-sized oocyte next to giant oocyte (right)

OOCYTE SIZE AND SHAPE

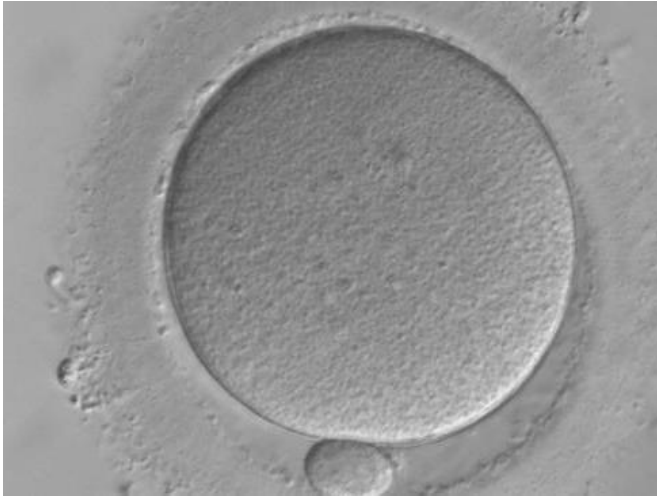


Note the ZP is ovoid in appearance and the PVS is enlarged at both poles

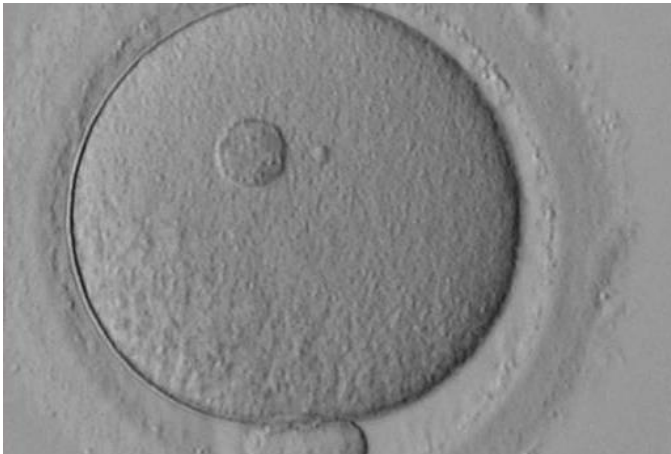


Twin oocytes in a single zona pellucida

CYTOPLASMIC FEATURES

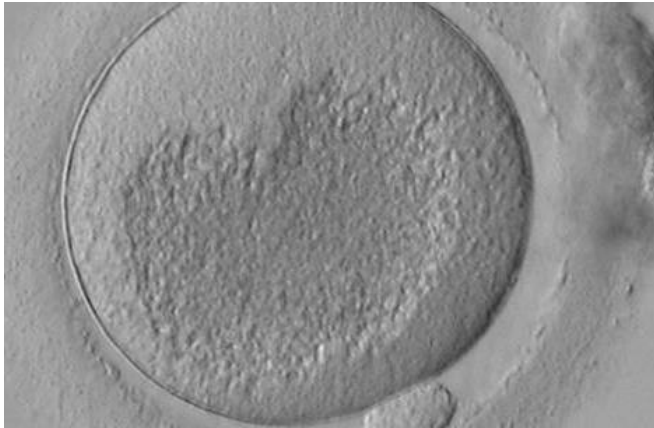


Normal homogenous cytoplasm in an MII oocyte

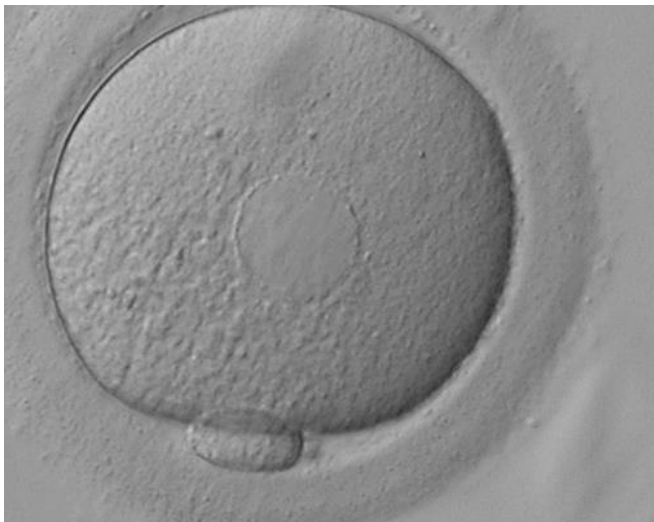

MIII oocyte showing a large refractile body

CYTOPLASMIC FEATURES

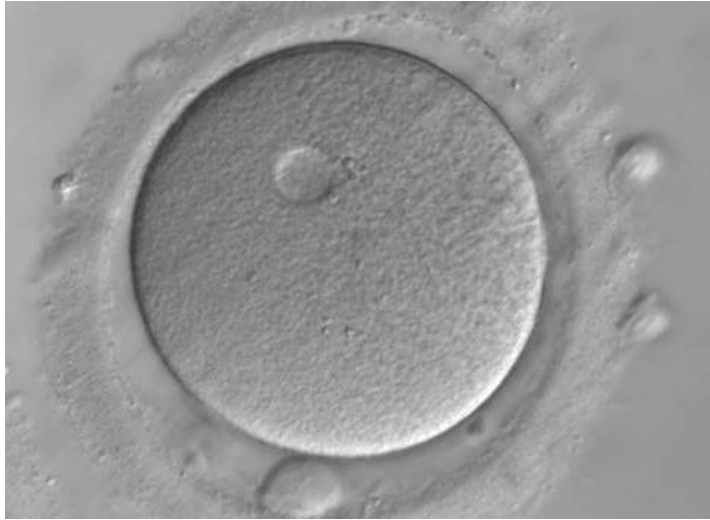


MI I oocyte showing a very large centrally located granular area

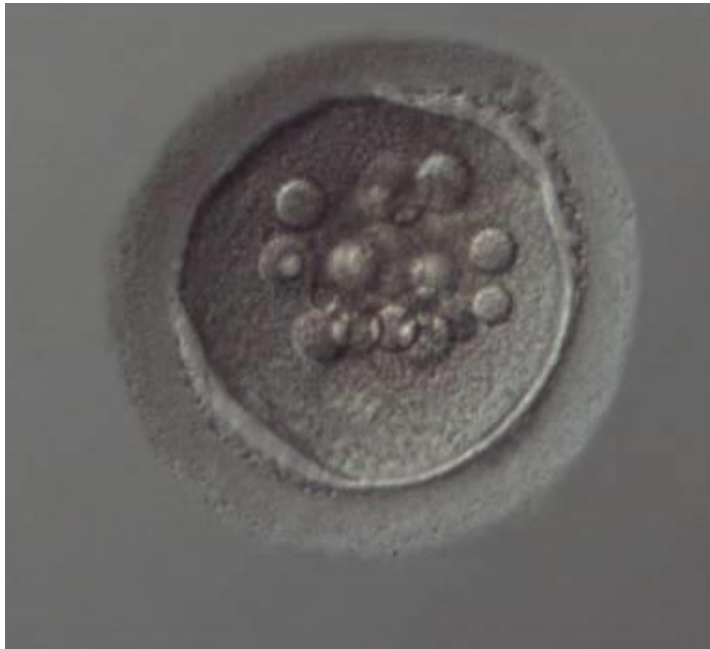

MI I oocyte showing plaques of dilated SER discs in the cytoplasm

CYTOPLASMIC FEATURES

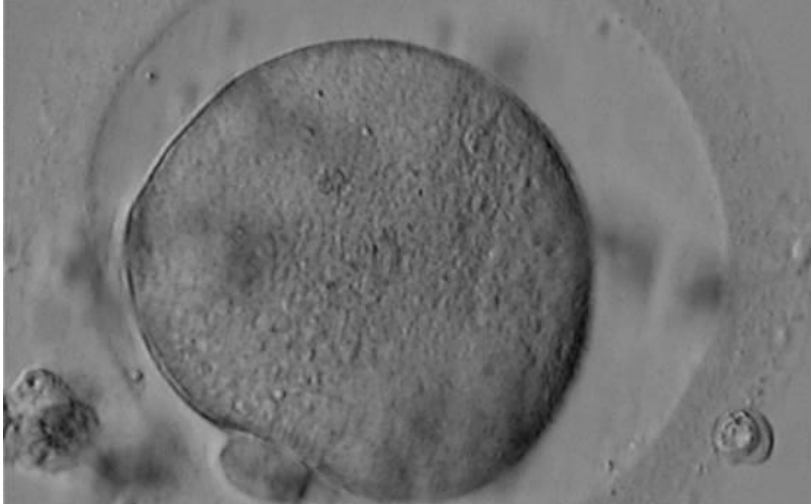

Vacuolated oocyte

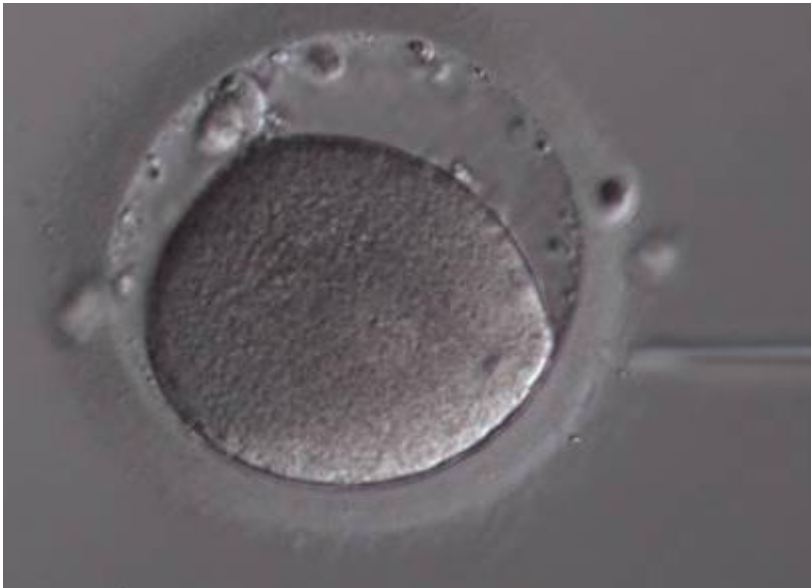

Vacuolated oocyte

PERIVITELLINE SPACE




Oocyte with a large PVS and a granular cytoplasm.

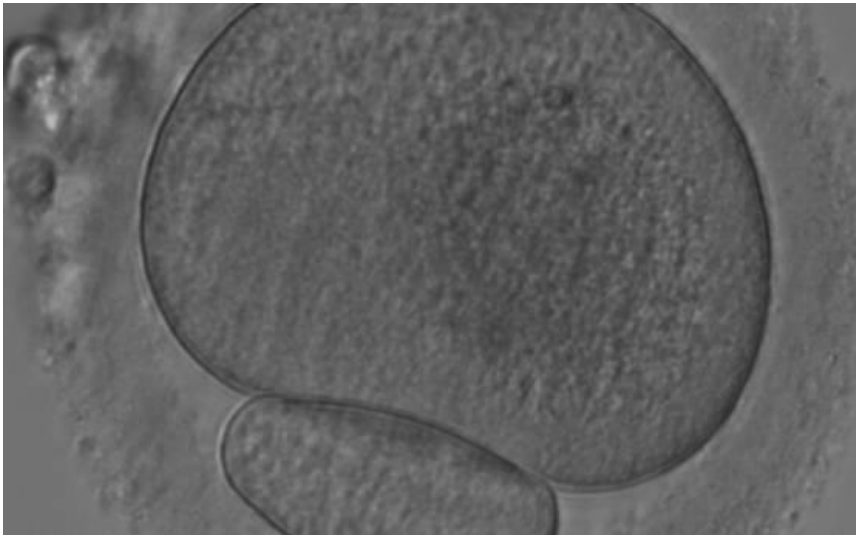


Oocyte with a large PVS.
Several fragments are present in the PVS.

POLAR BODY



A normal-sized PBI.



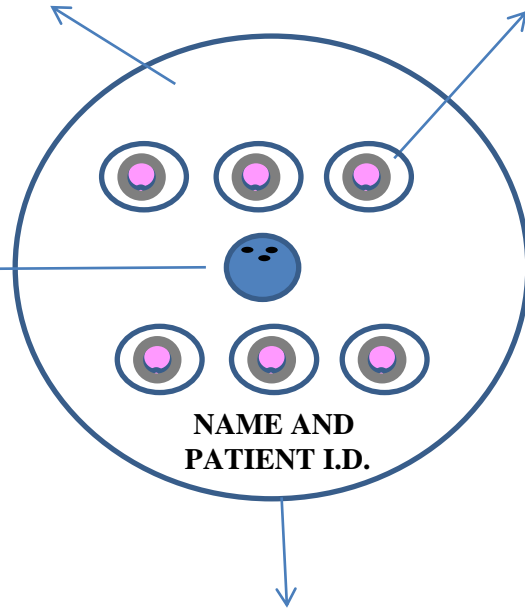
A giant PBI.

THE ICSI DISH

The drops must to be covered with 5 ml of light mineral oil

10 μ l HEPES-HTF + oocyte


5 μ l PVP + 1-2 μ l of treated sperms



The lid of a 65 x 10 mm Petri dish has the optimal refringence at the inverted microscope



SET UP OF THE MICROMANIPULATION STATION



HOLDING PIPETTE

30-35° BEVEL
PARALLEL WALL
20-25 μM OF ID

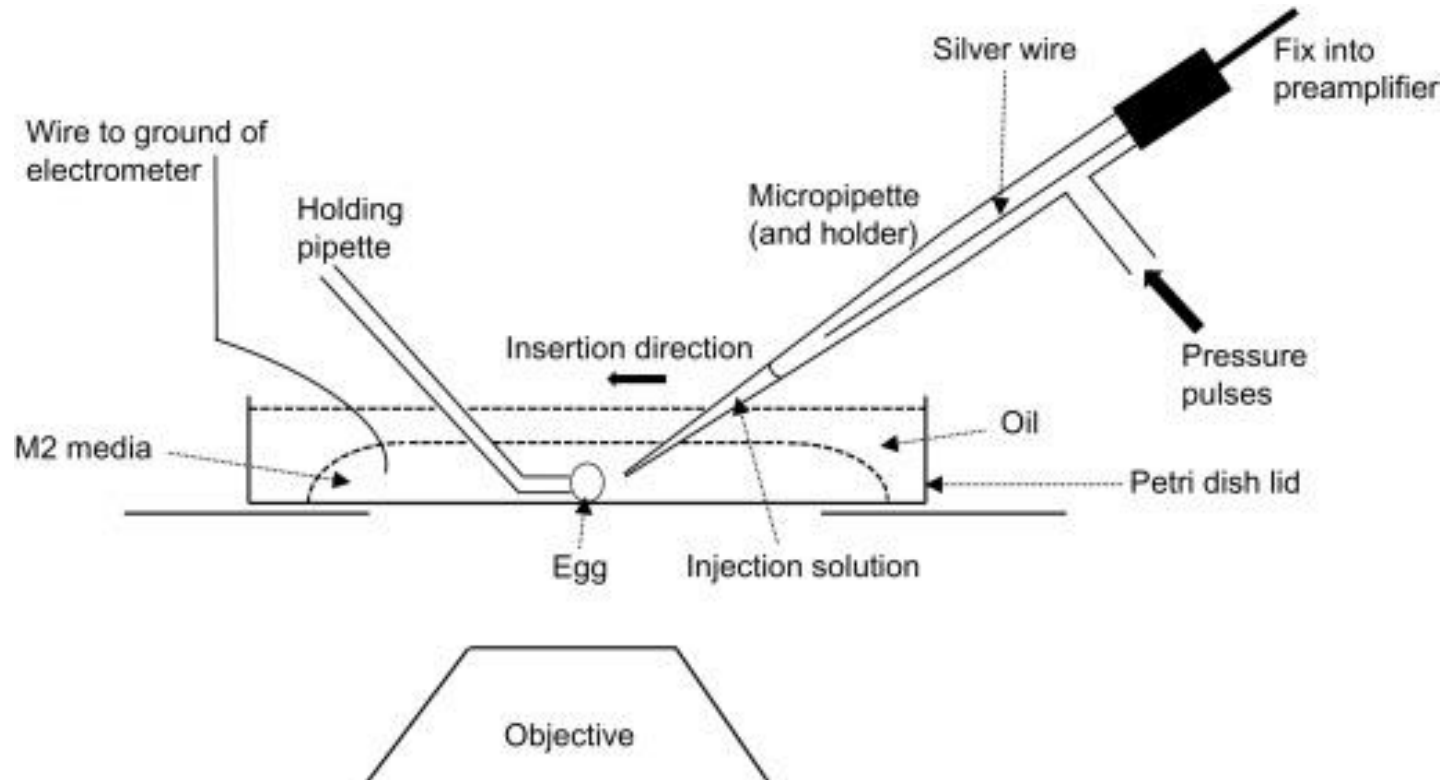
INJECTION PIPETTE

30-35° BEVEL
PARALLEL WALL
4-5 μM OF ID

MAGNIFICATION

40 X FOR BETTER SPERM SELECTION

SET UP OF THE MICROMANIPULATION STATION



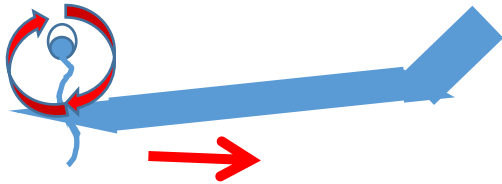
<https://www.youtube.com/watch?v=bd442apDyus>

SPERM SELECTION AND IMMOBILIZATION (INSIDE PVP DROP)

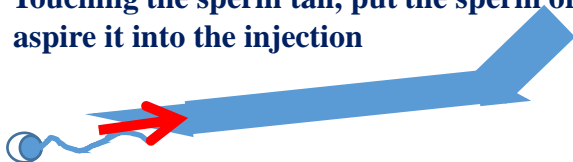
1. Select the sperm and immobilize it going down to the sperm tail



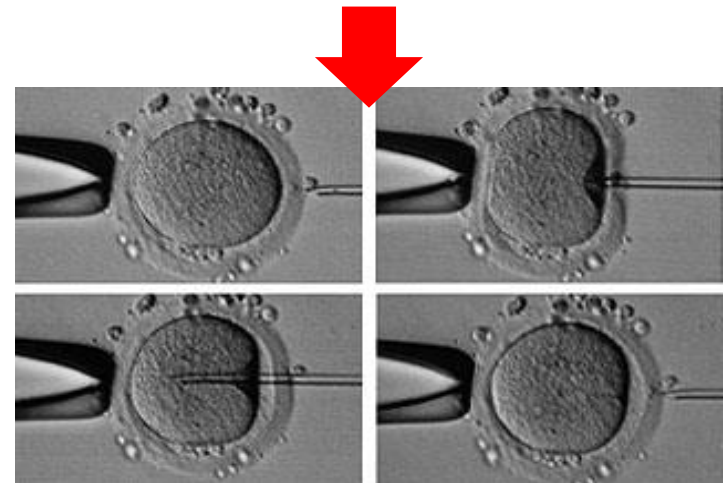
2. Move the injection to right: the sperm head become to swirl



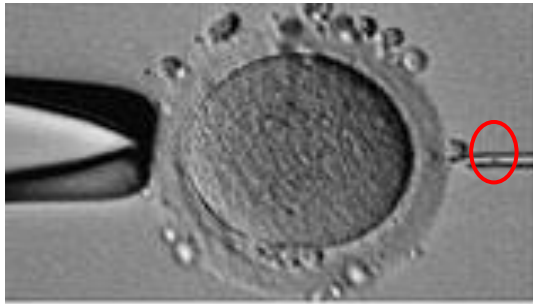
3. Touching the sperm tail, put the sperm orizzontally and aspirate it into the injection



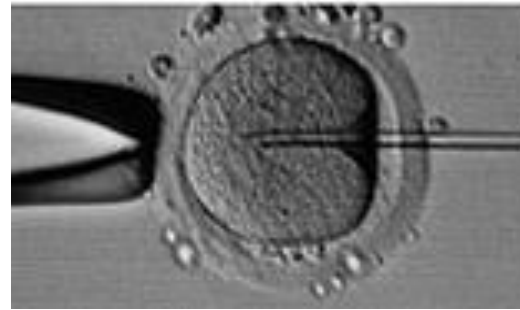
4. With the sperm inside, move the injection to the drop of the oocyte



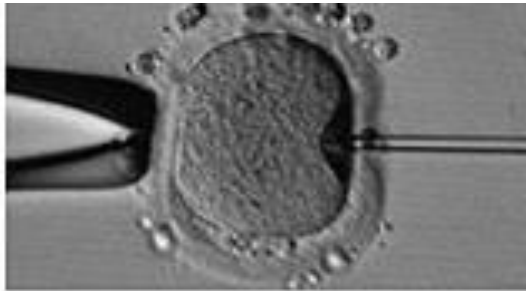OOCYTE INJECTION (INSIDE OOCYTE DROP)



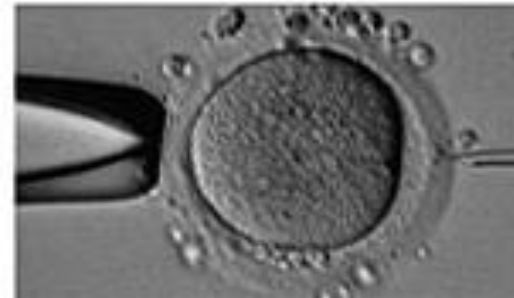
1. Hold the oocyte with a gentle suction putting the pb at 6 or 12 hrs. Focus on the inner layer of ZP and oolemma. The sperm is at the tip of injection.



3. Perform a vigorous cytoplasm aspiration until the membrane of the oocyte brake down. Immediately, invert the direction in order to release the sperm.



2. Move the injection trough the ZP and oolemma. Stop the moviment at $\frac{3}{4}$ of the oocyte cytoplasm.



4. Release the sperm inside the cytoplasm and move back the injection pipette. Gently, release the oocyte from the holding suction.

<https://www.youtube.com/watch?v=uvmBRTFG7Vo&t=220s>

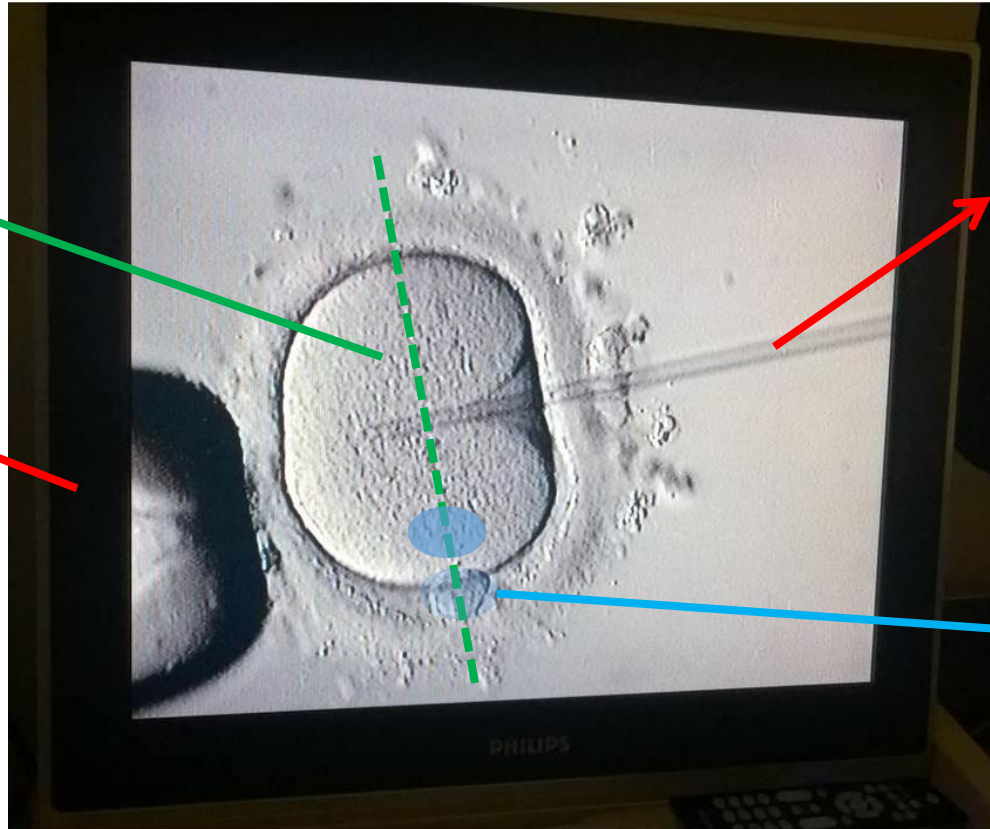
INTRACYTOPLASMATIC SPERM INJECTION (ICSI)

SPERM RELEASE

TIP OF INJECTION
AT $\frac{3}{4}$ OF THE OOCYTE

HOLDING PIPETTE

30-35° BEVEL
PARALLEL WALL
20-25 μM OF ID



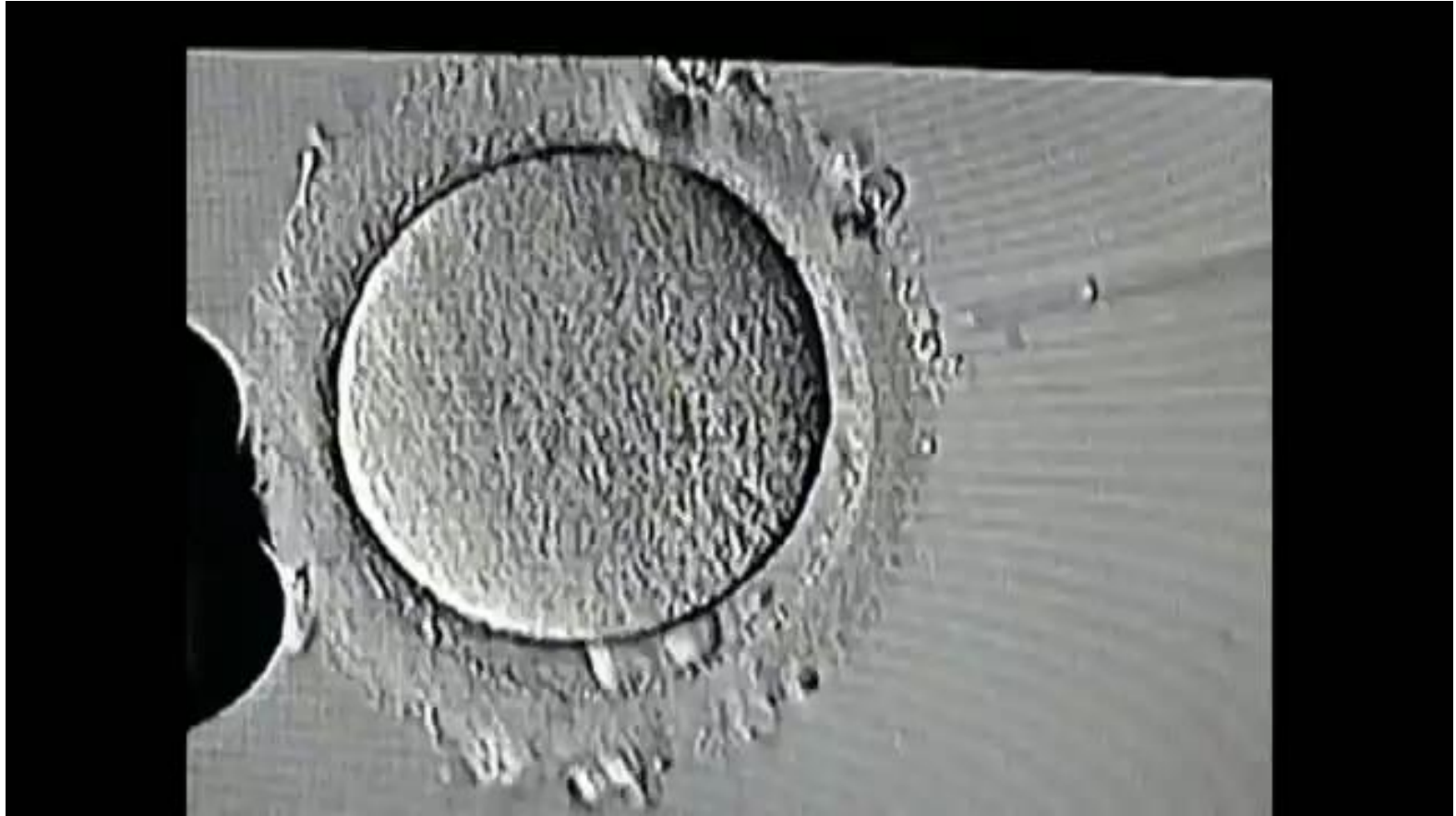INJECTION PIPETTE

30-35° BEVEL
PARALLEL WALL
4-5 μM OF ID

POLAR BODY

12 OR 6 O'CLOCK
PRESERVE MEIOTIC
SPINDLE

INTRACYTOPLASMATIC SPERM INJECTION (ICSI)

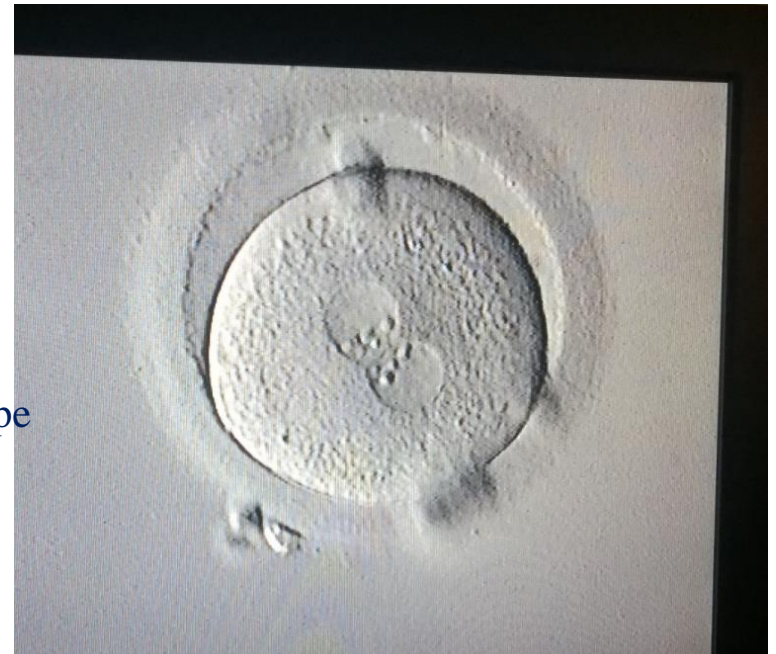

INTRACYTOPLASMATIC SPERM INJECTION (ICSI)

- The occurrence of fertilization has to be checked between 16 and 18 hours after insemination
- In case of FIVET insemination, the oocyte must be denuded from the corona cells eventually attached
- In case of ICSI, the oocyte has already been denuded, so the check can be done directly at the inverted microscope

CULTURE ONLY FOR 2PN ZYGOTE !!!

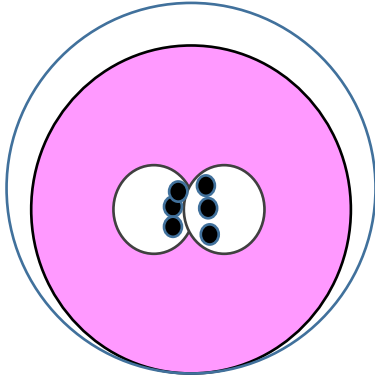
DESCARD: 1 PN ZYGOTE; 3 OR MORE PN ZYGOTE; 0
PN
ZYGOTE WITH ONLY 1 CLEARLY VISIBLE PB



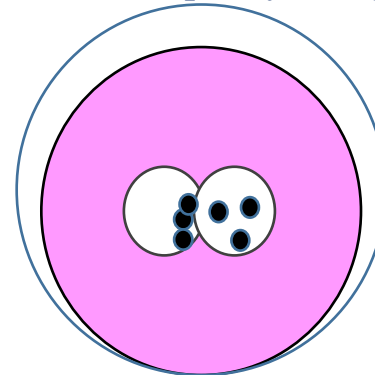
Grade 1 zygote: 2 distinct pronucleous with nucleolus aligned and ready to singamy.

ZYGOTE SCORING

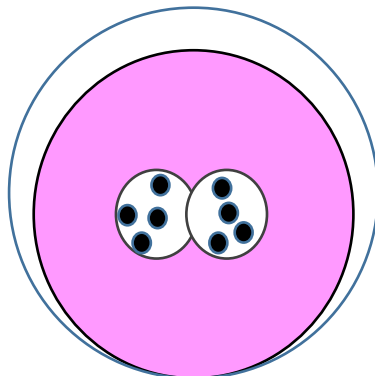
Grade 1: aligned, equality in NPB's



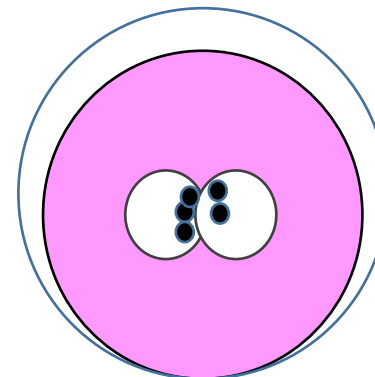
Grade 3: non equality in alignment

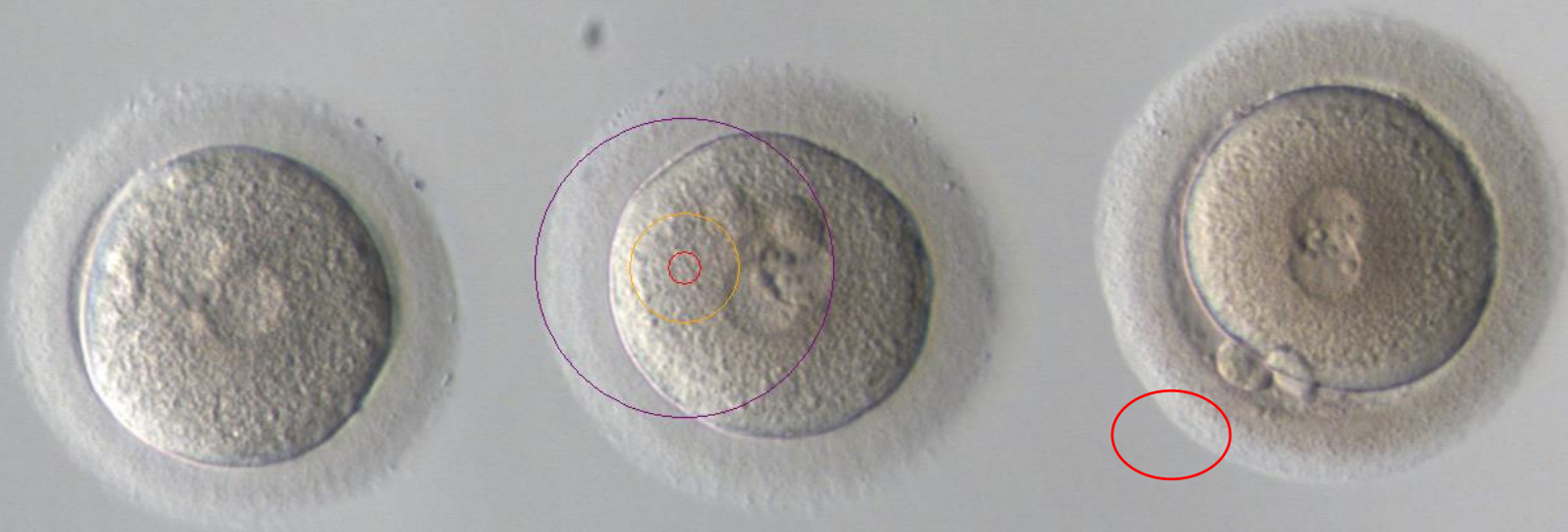

Grade 2: scattered, equality in NPB's

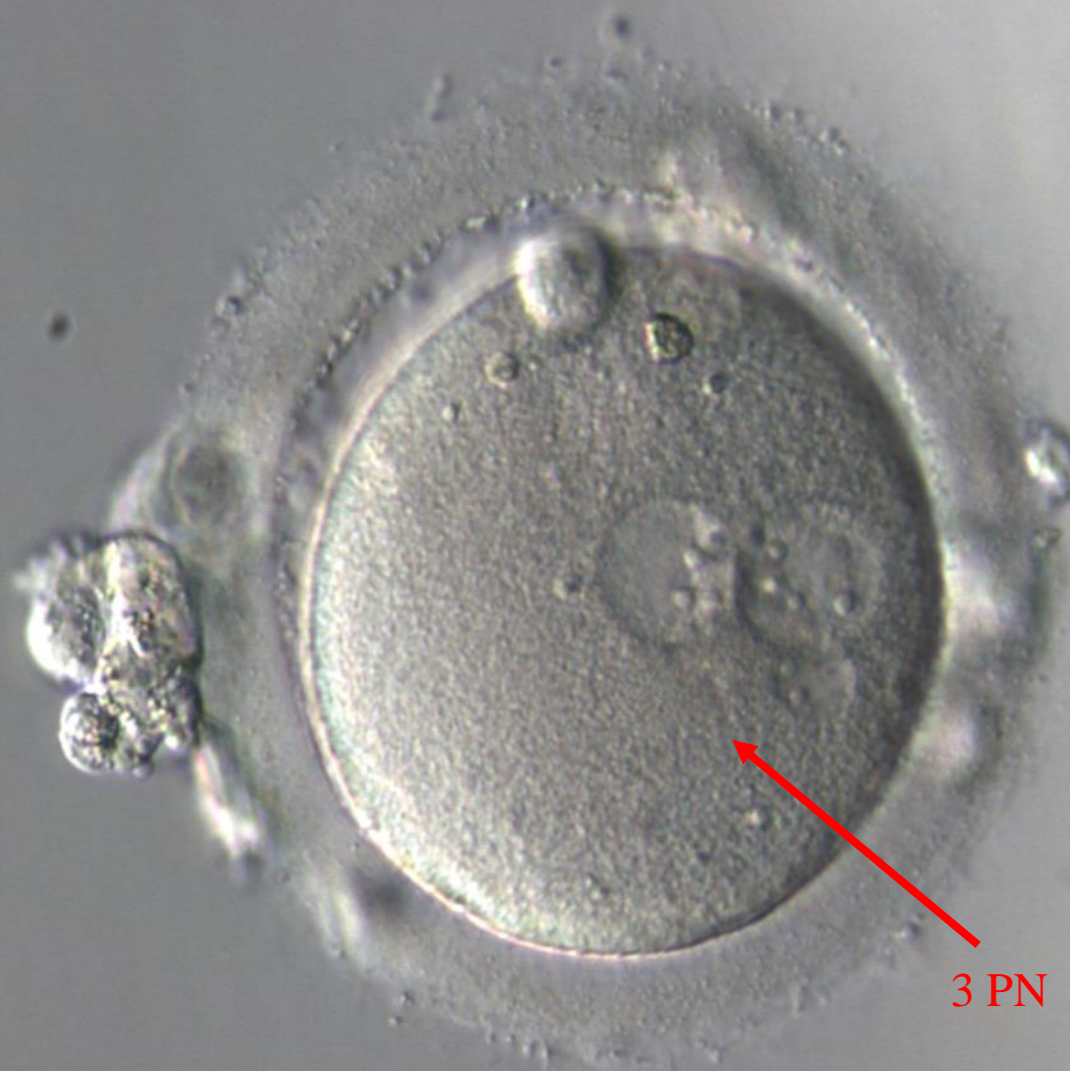

Grade 4: non equality in numbers

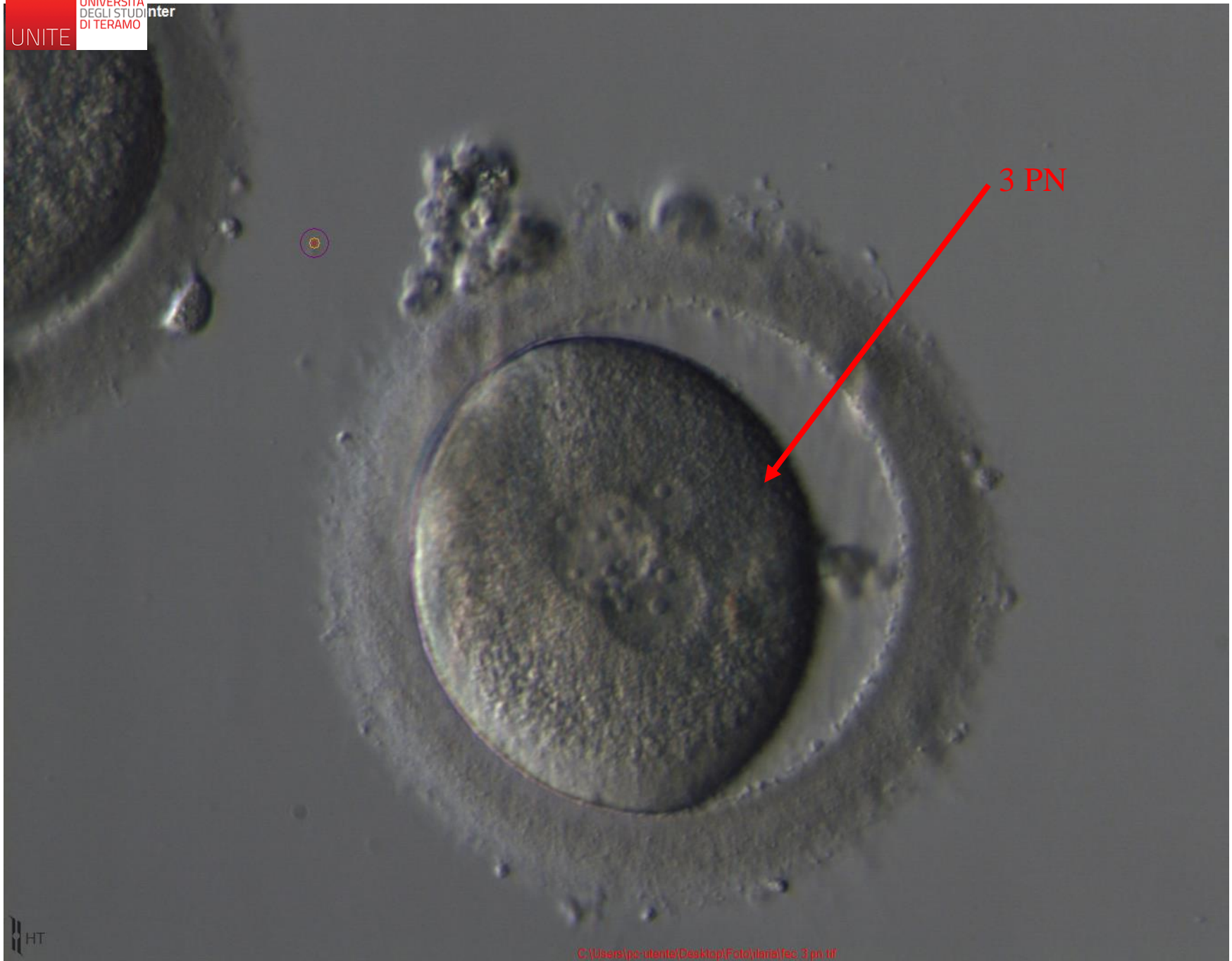



Bad quality grade 4 zygote



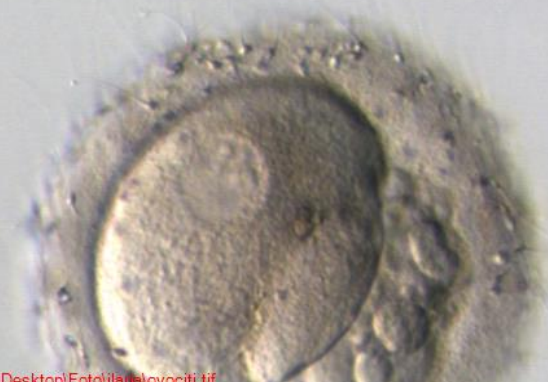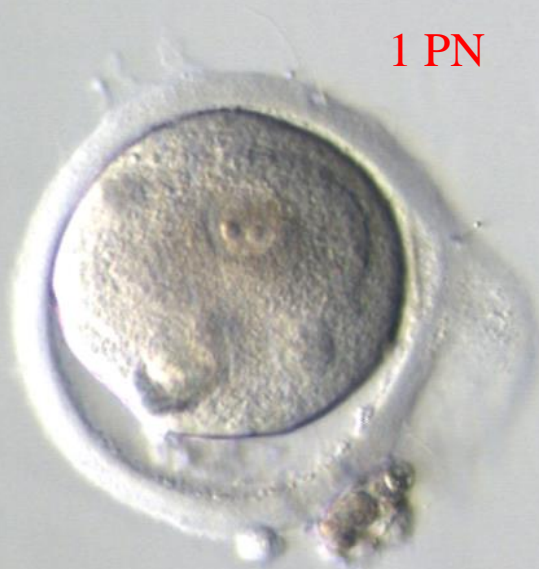3 PN



3 PN



1 PN



Grade 3 Zygote

