




OSPEDALE VETERINARIO
UNIVERSITARIO DIDATTICO FACOLTÀ MEDICINA VETERINARIA

Normal and Cryptorchid Castration




**Servizio di medicina e chirurgia
del cavallo UNITE**



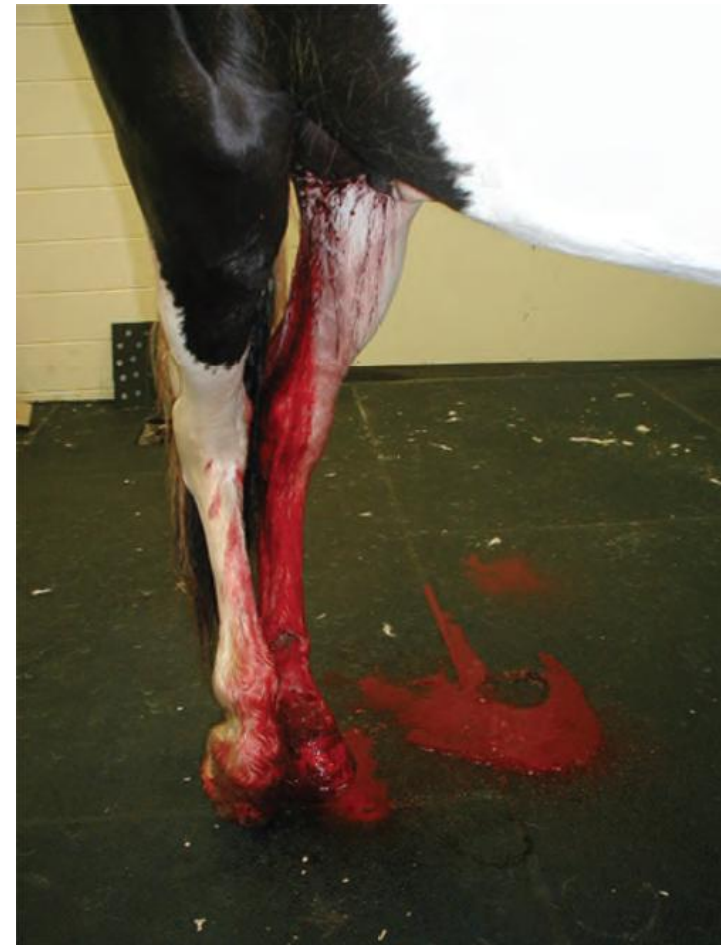Castration: Surgical Removal of Testes


- One of the **most commonly** performed equine **surgical procedures**
- Its **complications** are among the most common causes of **malpractice** claims against **veterinarians**
- **Synonyms** for castration include:
 - Orchidectomy
 - Orchiectomy
 - Castration
 - Emasculation
 - Gelding
 - Cutting



Postoperative Complications of Castration

- Hemorrhage
- Swelling
- Infection
- Septic Peritonitis
- Hydrocele
- Intestinal Evisceration
- Omentum Eventration (Prolapse)
- Continued Stallion-like Behavior





Testis Anatomy

■ Scrotum

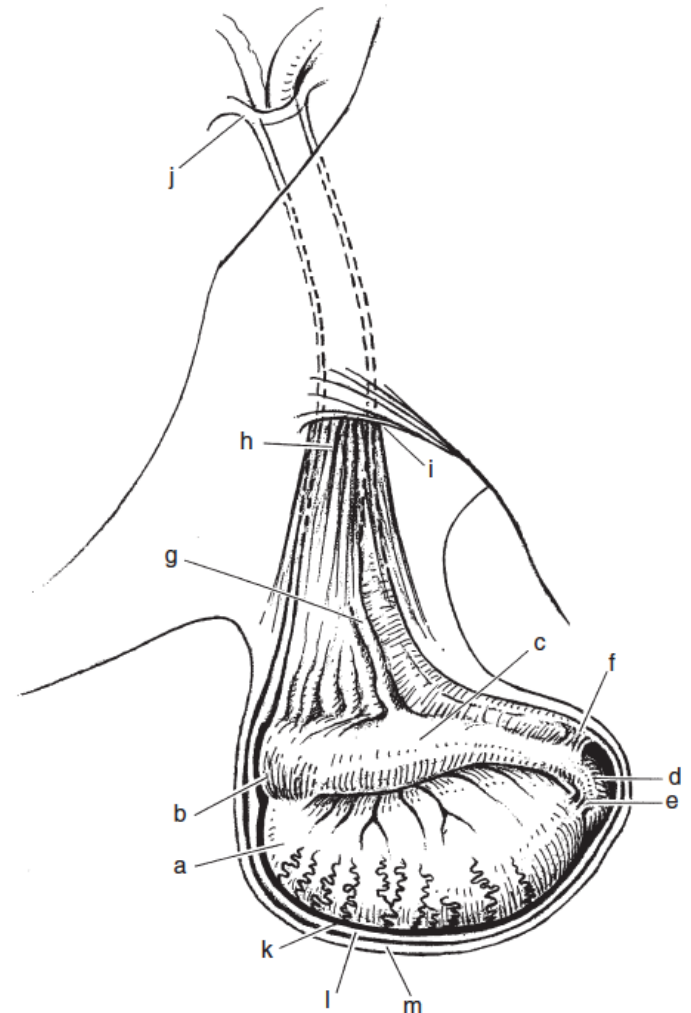
- skin
- *tunica dartos*


■ *Tunica vaginalis*

- visceral tunic (*tunica vaginalis propria*)
- parietal tunic (*tunica vaginalis communis*)
- vaginal process o vaginal sac
- vaginal ring
- vaginal cavity

■ Epididymis

- head (caput)
- body (corpus)
- tail (cauda)

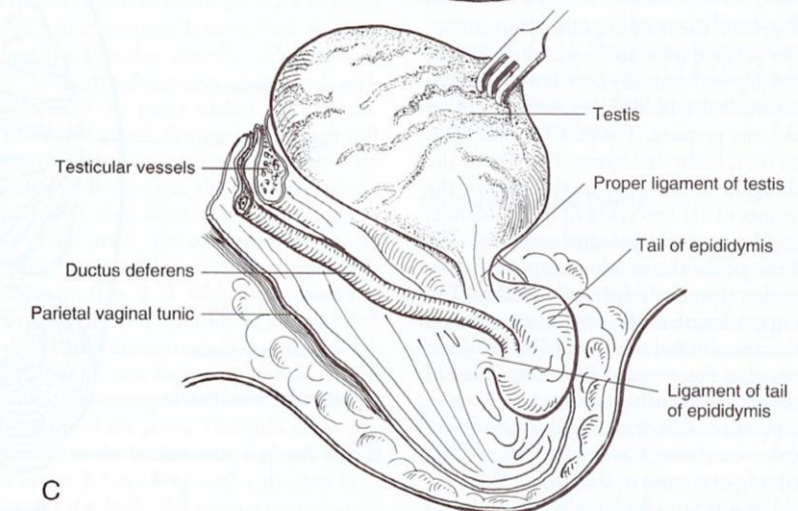
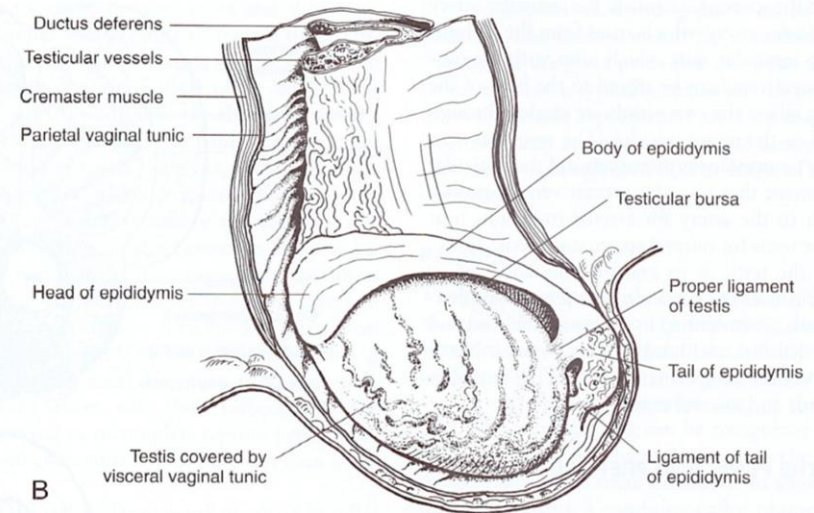





Testis Anatomy

■ Ligamentous structures

- ***proper ligament of testis***
 - between the caudal pole of the mature testis and the tail of epididymis
- ***ligament of tail of epididymis***
 - between the tail of epididymis and parietal tunic of the vaginal process
- ***scrotal ligament***
 - between the parietal tunic of the vaginal process and the bottom of the scrotum

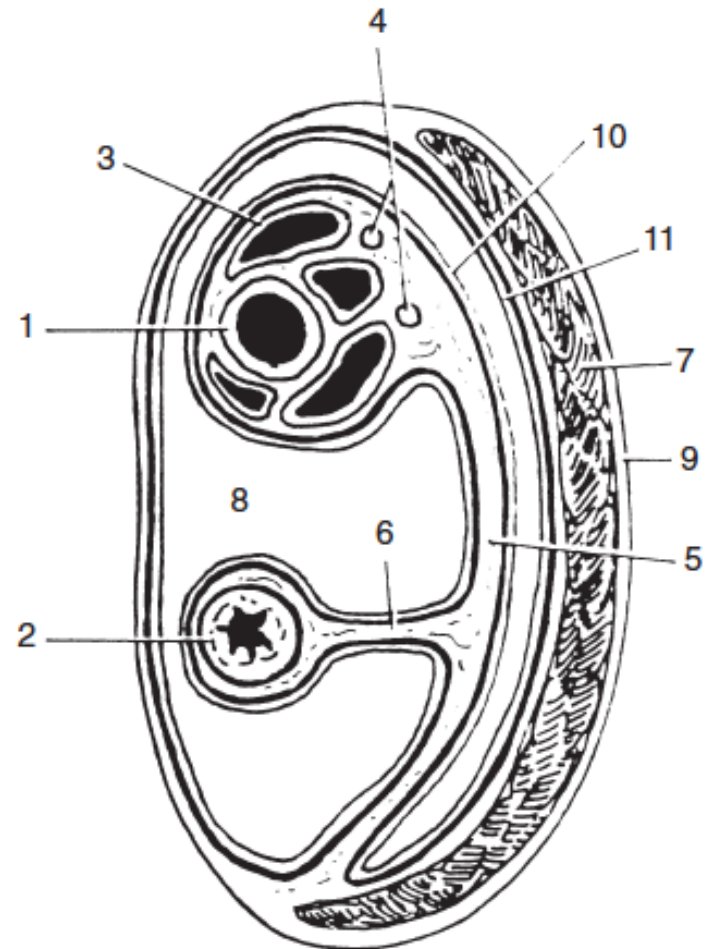





Testis Anatomy

■ Spermatic cord

- *tunica vaginalis*
- *ductus deferens*
- *testicular artery* (a branch of the abdominal aorta)
- *testicular veins (pampiniform plexus)*
- *lymphatic vessel*
- *testicular plexus* (autonomic and visceral sensory nerve)

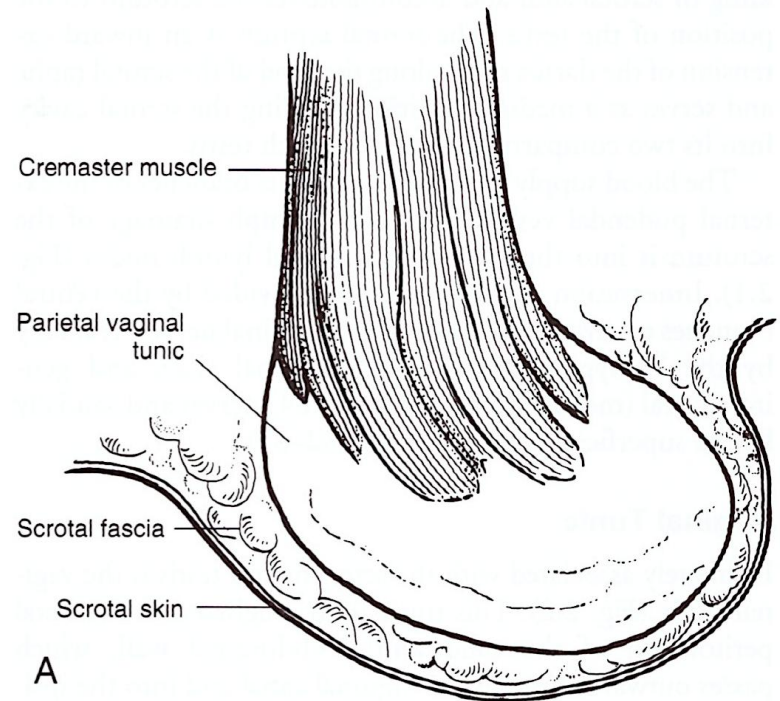





Testis Anatomy

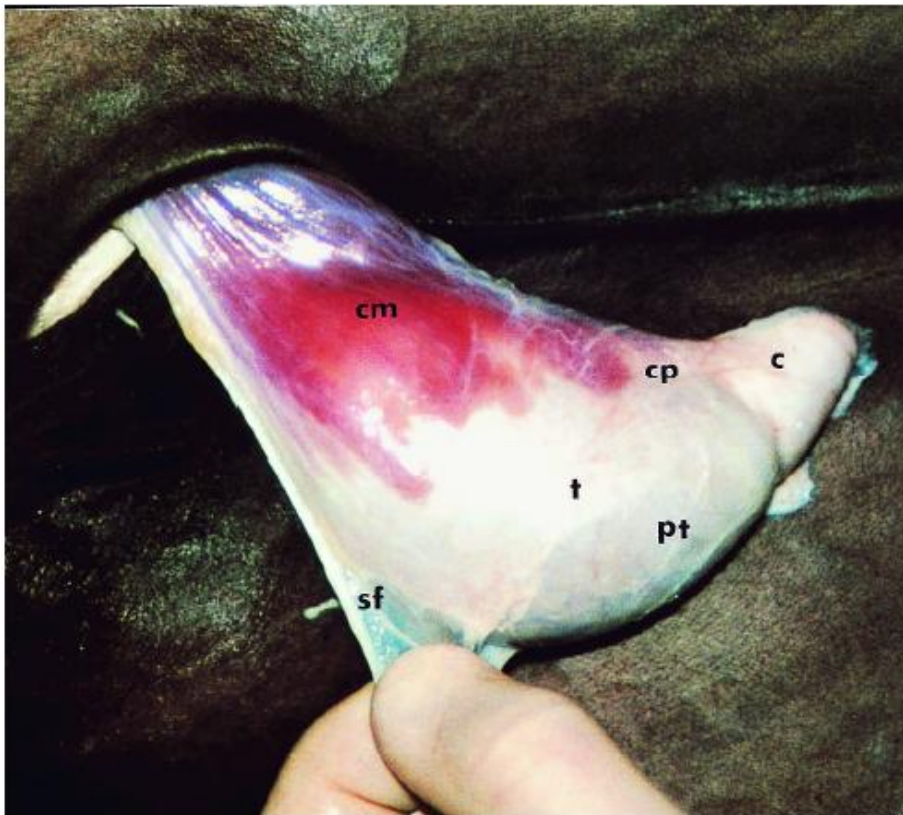
■ Cremaster muscle

- a slip of the internal abdominal oblique muscle
- is not included as a component of the cord because it lies external to the parietal tunic
- lies on the caudolateral surface of the parietal tunic and attaches to this tunic at the caudal pole of the testis
- contraction of the cremaster muscle retracts the testis

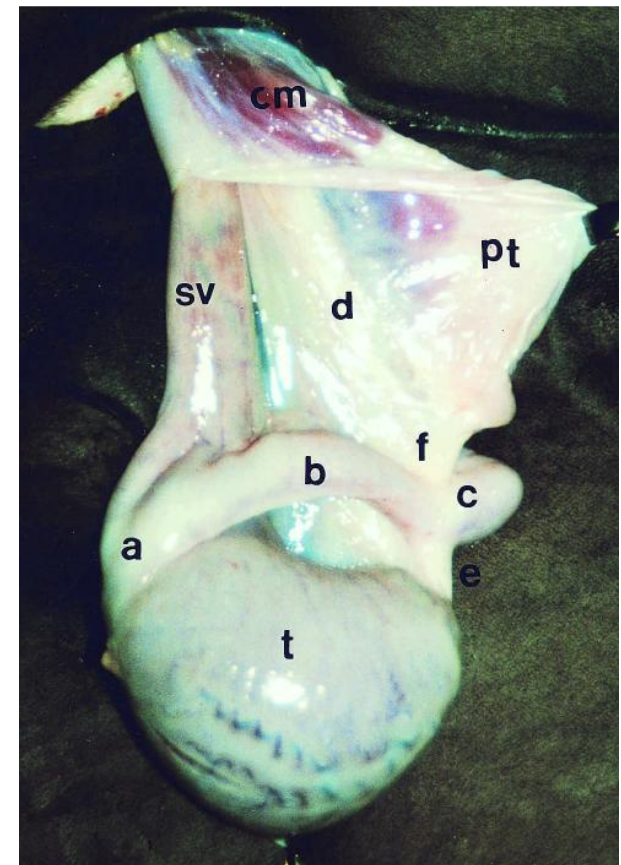





Testis Anatomy



parietal tunic is not incised but is freed from the scrotal ligament and scrotal fascia




parietal tunic and cremaster muscle have been incised and are partially retracted



Castration

■ Indications


- Reduce or prevent **sexual behavior** and **aggressive temperament**
- **Sterilize** horses unsuitable for contributing to the genetic pool
- Orchitis, epididymitis, testicular neoplasia, hydrocele, varicocele, testicular damage caused by trauma, torsion of the spermatic cord or inguinal herniation (**unilateral** or sometimes **bilateral**)



Castration

- **Preoperative consideration**


- Full **physical examination**
- Scrotal/inguinal areas should be palpated and inspected for the **absence of inguinal herniation** and for the **presence of both testes**
- **Sedation** permits safe palpation and occasionally facilitates palpation of an inguinal testis by causing the cremaster muscles to relax



Castration


■ Preoperative consideration

- **Tetanus** prophylaxis (tetanus toxoid booster or tetanus antitoxin)
- **Antimicrobial** use to prevent postoperative infections is questionable and generally based on clinician preference
- Preoperative and postoperative administration of **NSAID** may help control pain and swelling




Castration

- **Surgical techniques** of orchiectomy are
 - **OPEN**
 - **CLOSED**
 - **HALF-** or **SEMI-** or **MODIFIED-CLOSED**
- Castration can be performed (**surgeon's preference and experience**)
 - In **STANDING** sedated horses using local anesthesia
 - In **RECUMBENT** position (lateral or dorsal) with the horse under general anesthesia



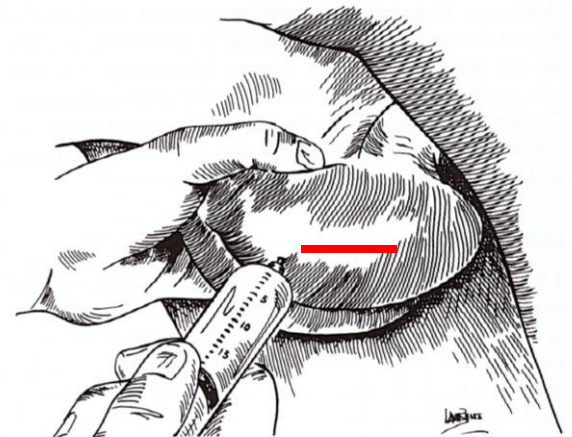
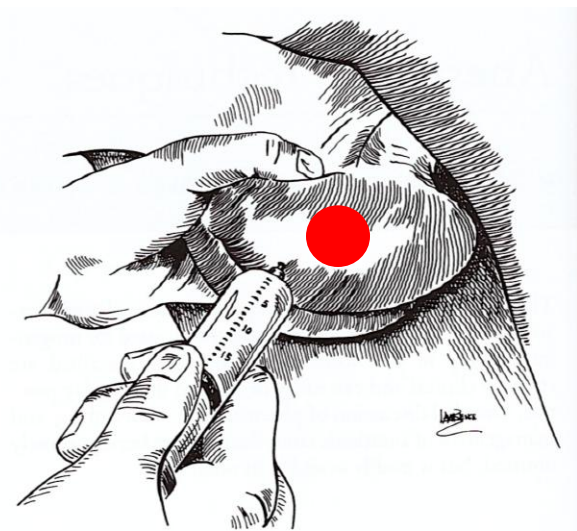
Castration


- **Approach**
 - **Scrotal** incision
 - **Inguinal** incision (horse is anesthetized and positioned in dorsal recumbency)
- **Closure of the skin incision**
 - **Primary** intention **healing** (sutured castration)
 - **Secondary** intention **healing** (unsutured castration)



Standing Castration with an Open Technique

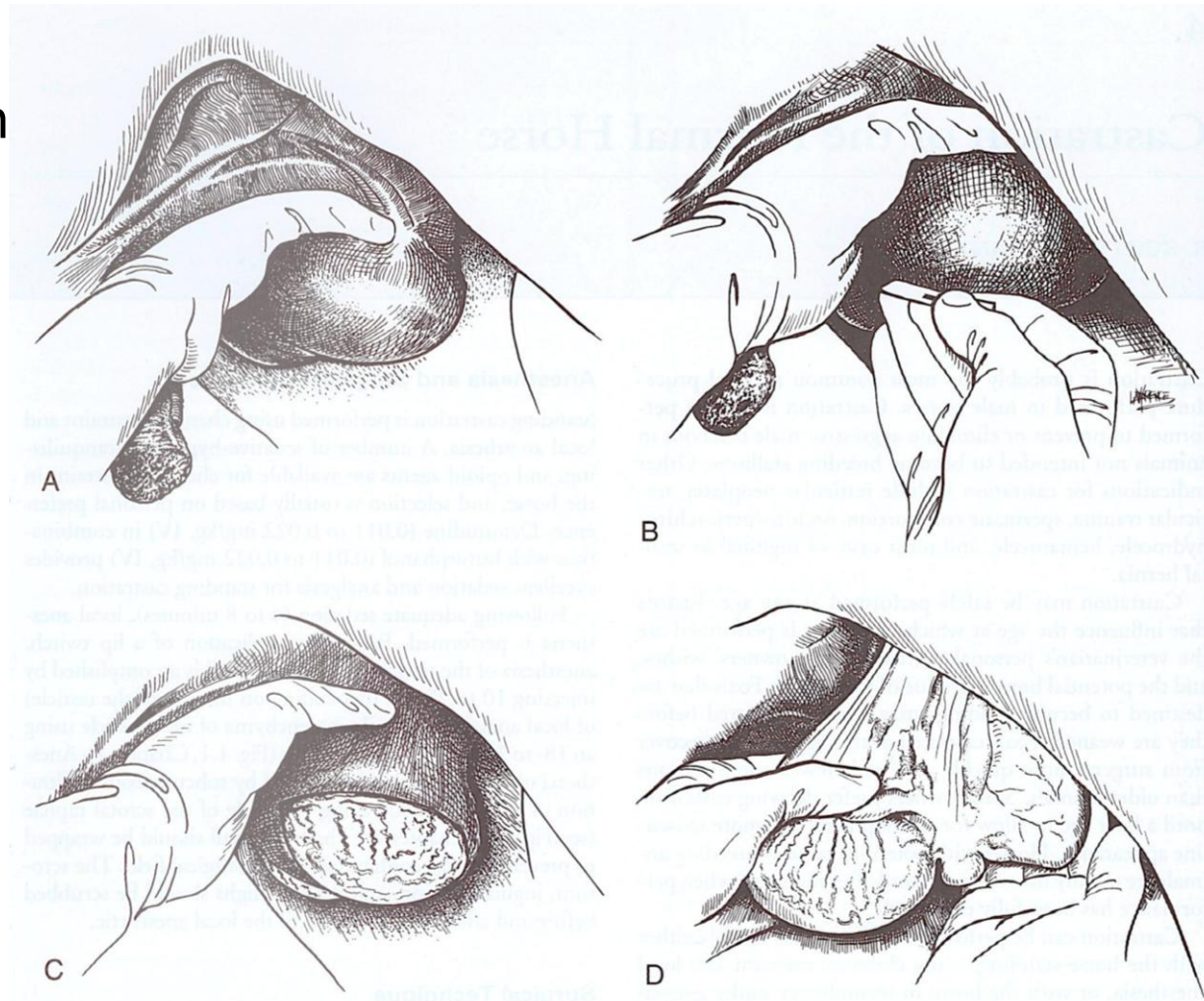
- Direct infiltration of local anesthetic into testicular parenchyma
- Subcutaneous infiltration of local anesthetic along proposed incision line






Standing Castration with an Open Technique

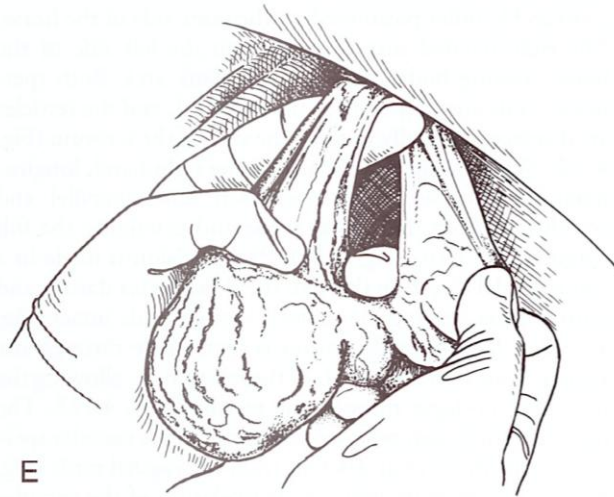- **A)** tensing the testicles in the scrotum
- **B)** scrotal incision
- **C)** completed incision into the parietal vaginal tunic
- **D)** testicles prolapsed through the incision of the vaginal tunic



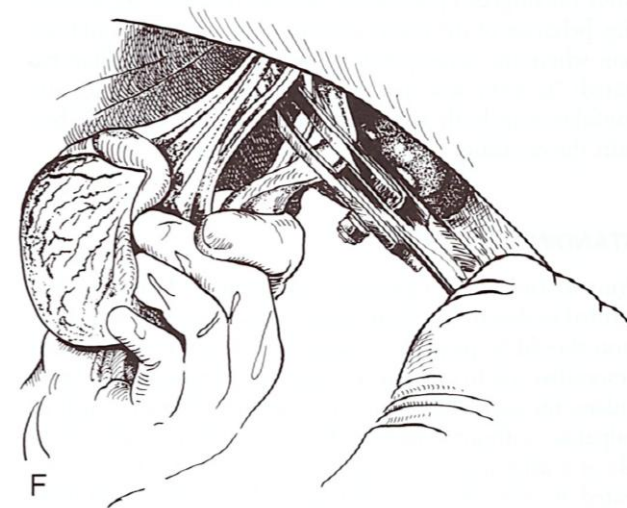


Standing Castration with an Open Technique

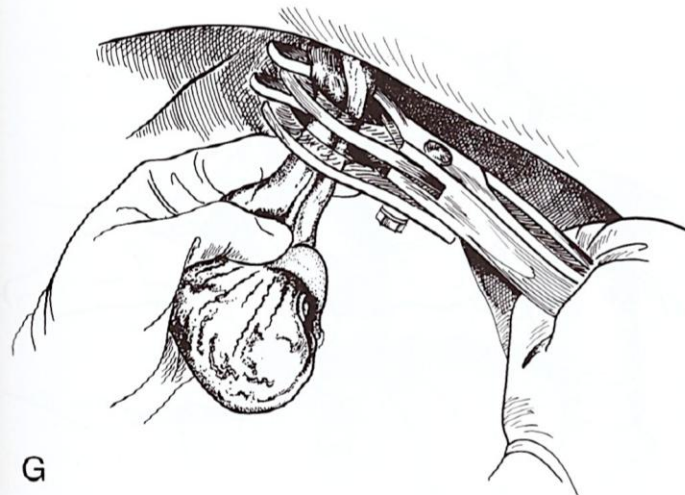
- **E)** perforation of the mesorchium
- **F)** emasculation of the musculofibrous portion of the spermatic cord
- **G)** emasculation of the vascular spermatic cord




E



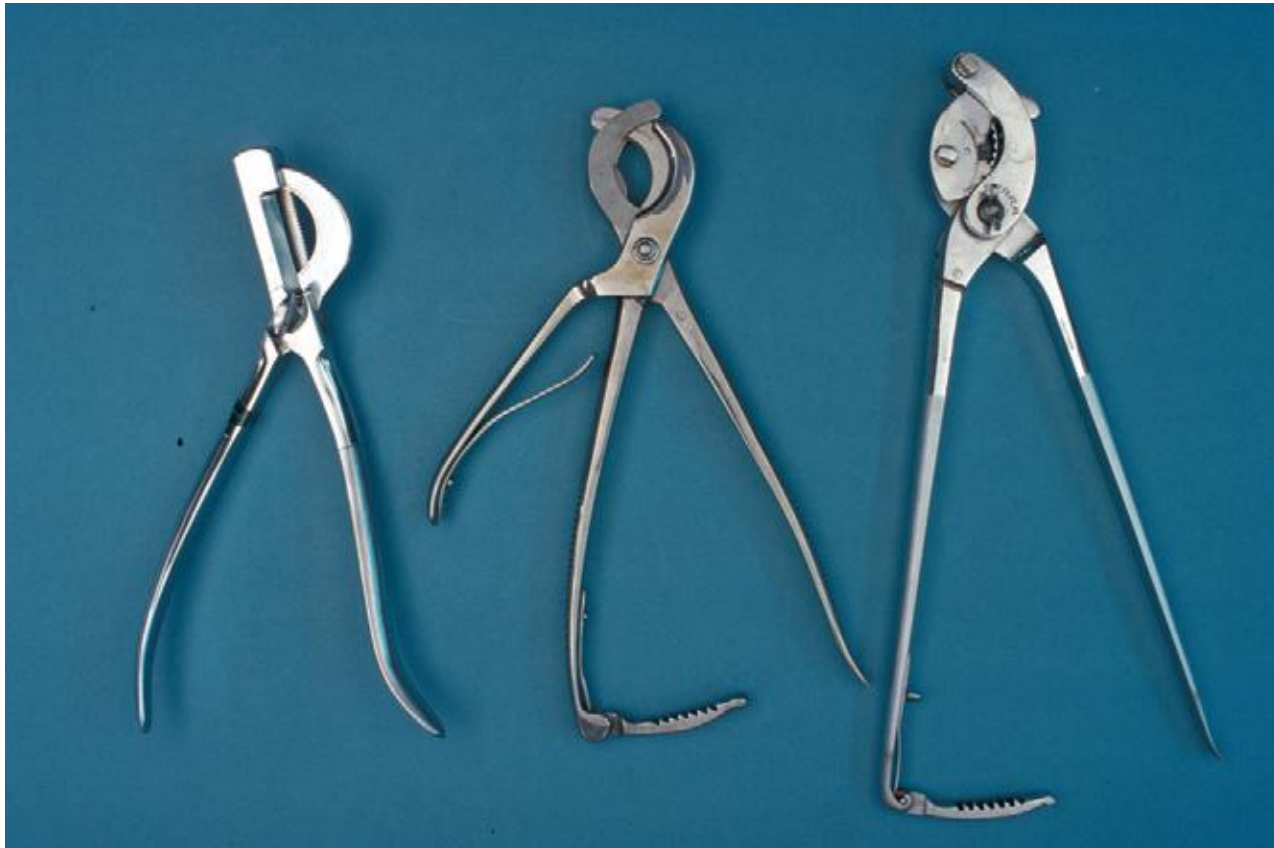F



G



Emasculators commonly used for Equine Castrations

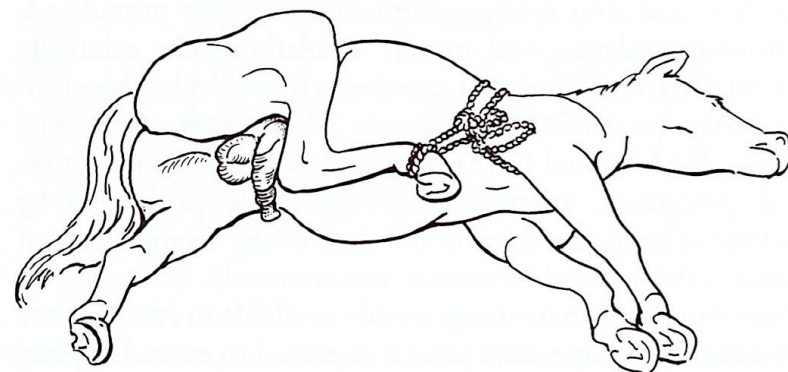
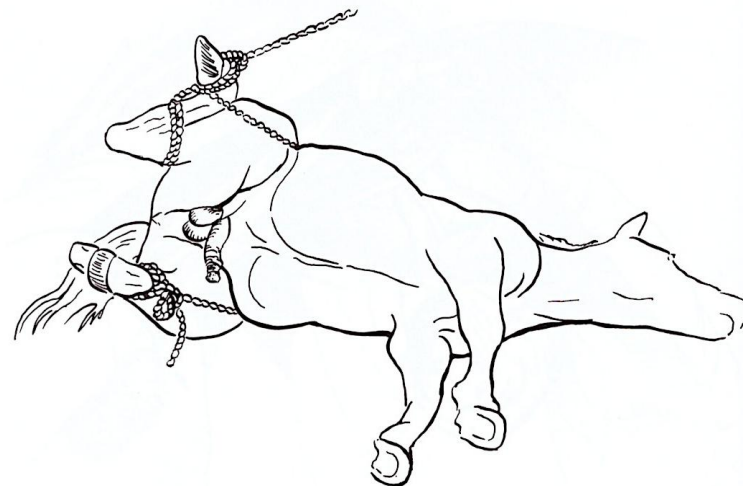



Left to right: Improved White, Reimer, Serra



Recumbent Castration with a Closed Technique through a Scrotal Approach

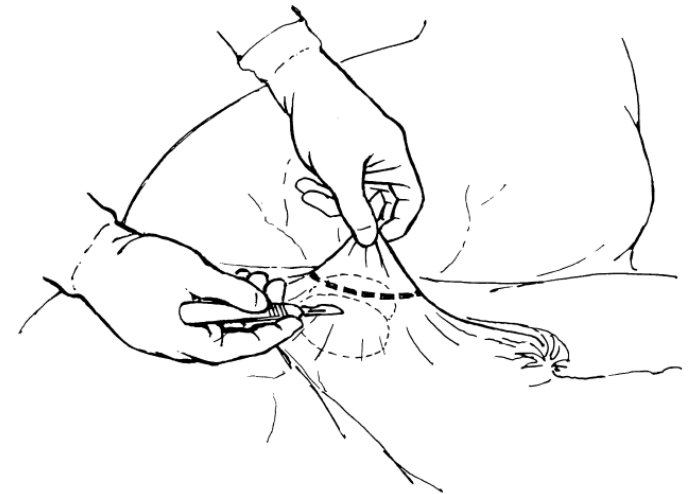
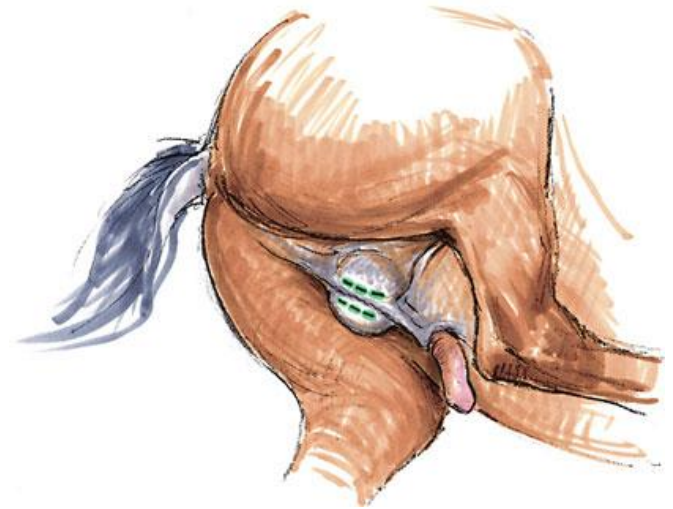- Closed castration is more difficult to accomplish in the standing horse
- Full exteriorisation of the vaginal process is much easier when the animal is in recumbency
- Hind limbs tied in a “frog leg” position
- Upper hindlimb pulled forward and secured with rope






Recumbent Castration with a Closed Technique through a Scrotal Approach

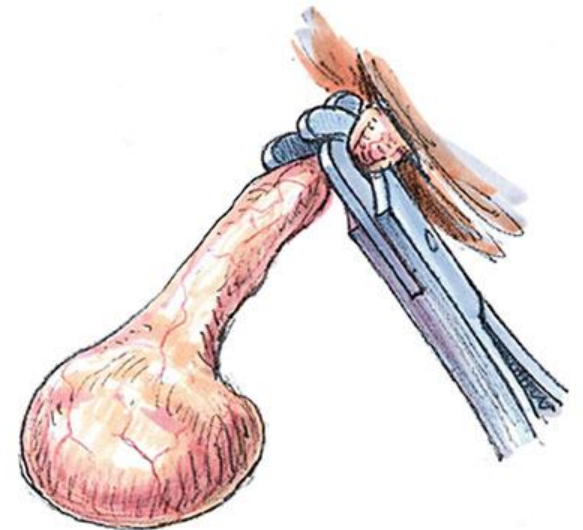
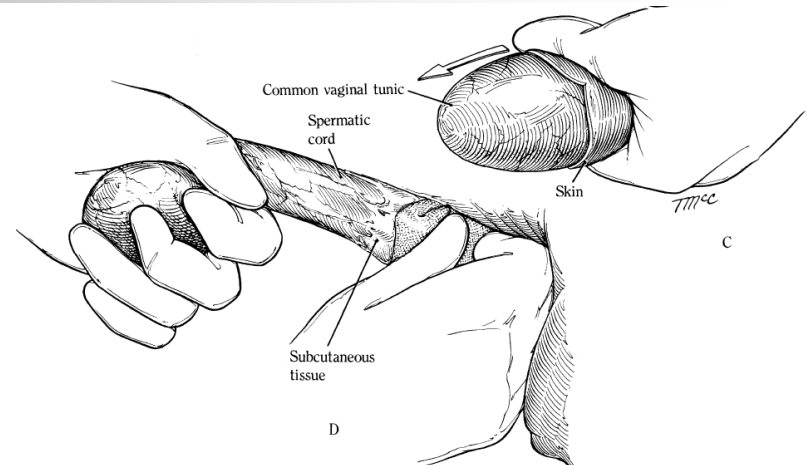
- Two skin incision are made through the scrotal skin and tunica dartos parallel to median raphe
- Alternatively the bottom of the scrotum is removed by placing traction on the scrotal raphe






Recumbent Castration with a Closed Technique through a Scrotal Approach

- Scrotal fascia is stripped from the parietal tunic using dry swab until the cremaster muscle and parietal tunic are fully exposed
- The entire spermatic cord is then emasculated close to the superficial inguinal ring
- In horses with large spermatic cord cremaster muscle can be bluntly dissected from the spermatic and the emasculators applied separately prior to crushing and severing





Ligation around Vaginal Tunic

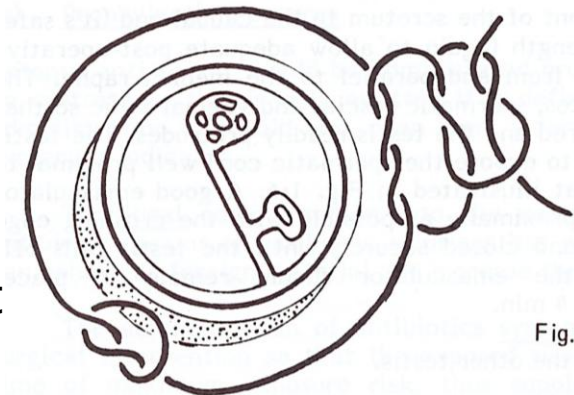
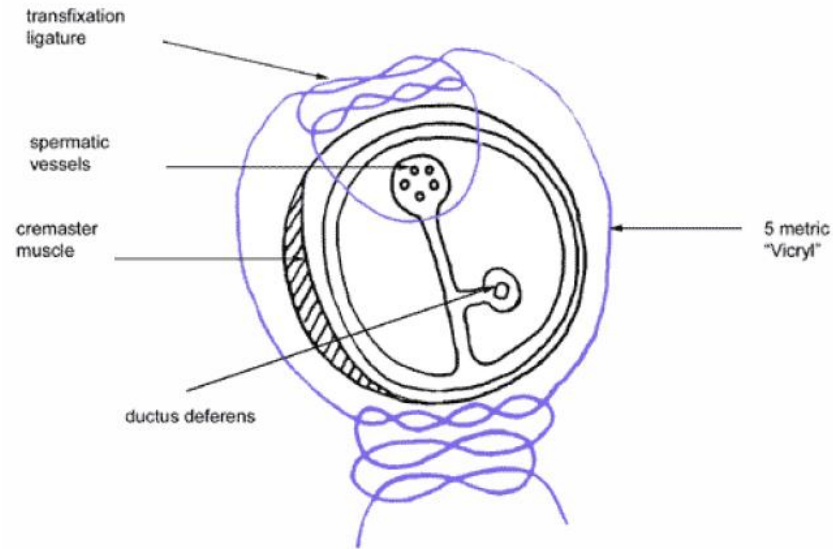
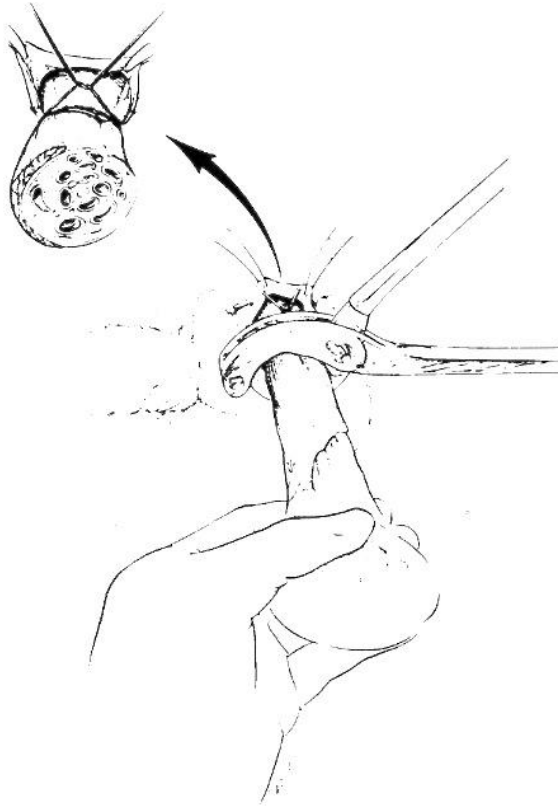
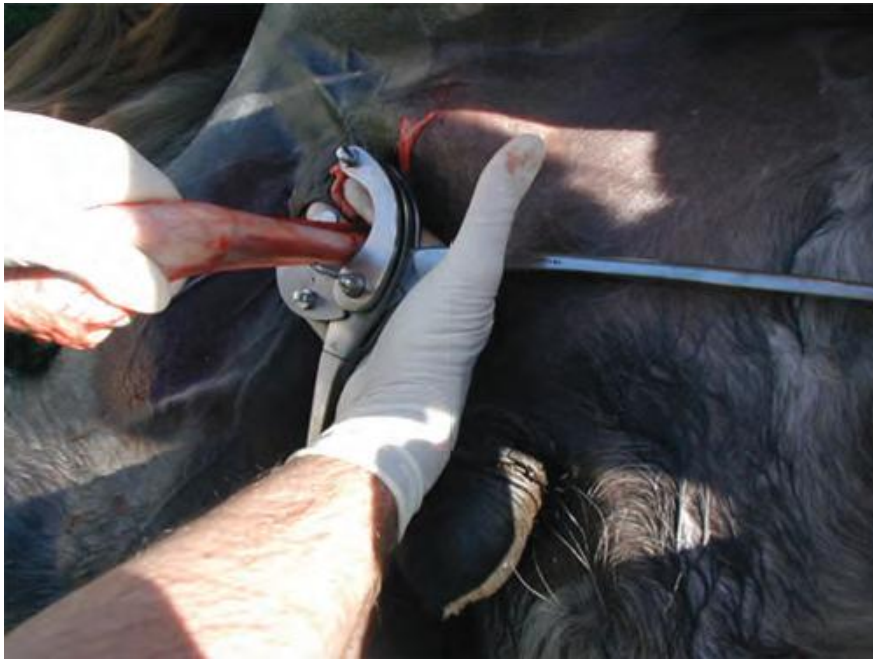

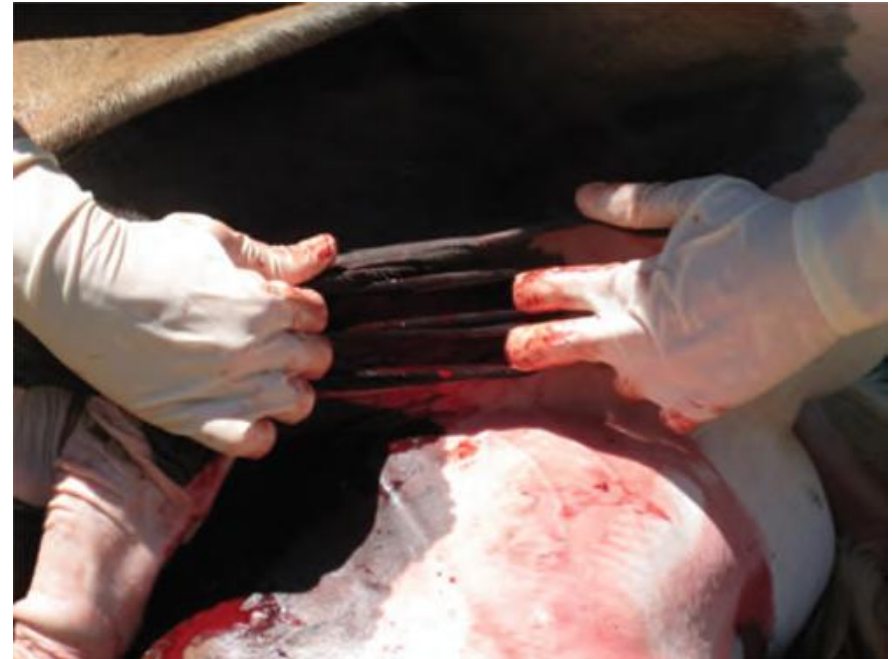Fig.

The closed technique has no advantage over the open technique in **preventing evisceration** if a ligature is not applied to the cord proximal to the site of transection

Recumbent Castration with a Closed Technique through a Scrotal Approach



Proper application of the **emasculator** with the prominent external assembly nuts facing the testis and the correct perpendicular orientation to the spermatic cord.




Stretching of the **scrotal skin** incisions to promote adequate drainage



Zurich technique

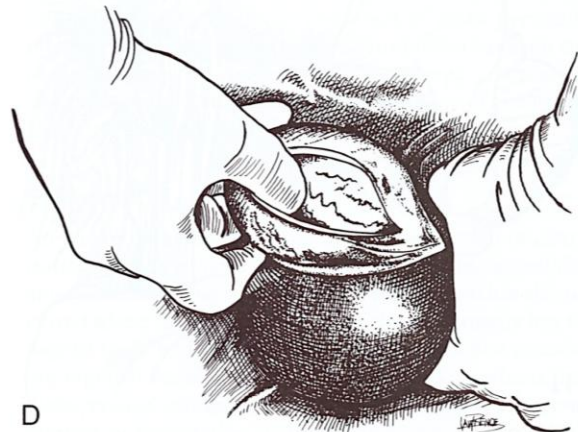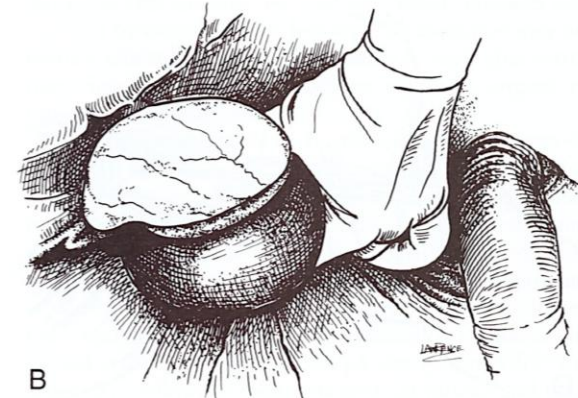
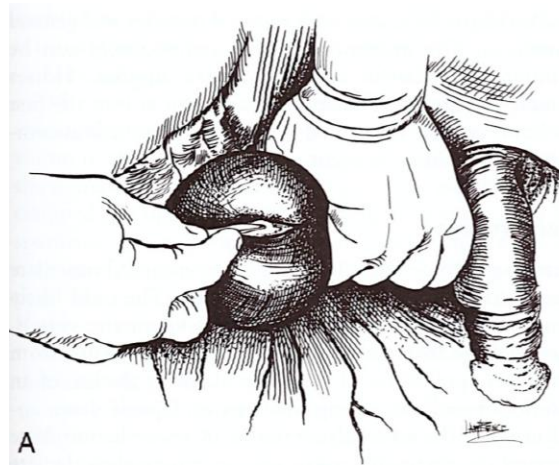
Zindel W: Die Kastration des Hengstes unter besonderer Berücksichtigung der an der Veterinär-Chirurgischen Klinik der Universität Zürich seit mehr als dreissig Jahren geübten Methode. Zürich, Veterinär-chirurgische Klinik der Universität Zürich, Zürich, 1945


- Used in Europe
- To ensure adequate **scrotal drainage** involves suturing a **30-cm-long gauze drain** to the stumps of the cords with heavy catgut suture
- The drain that exits the scrotal wound is **removed 2 days after castration** by rupturing the catgut suture with a sharp tug on the drain



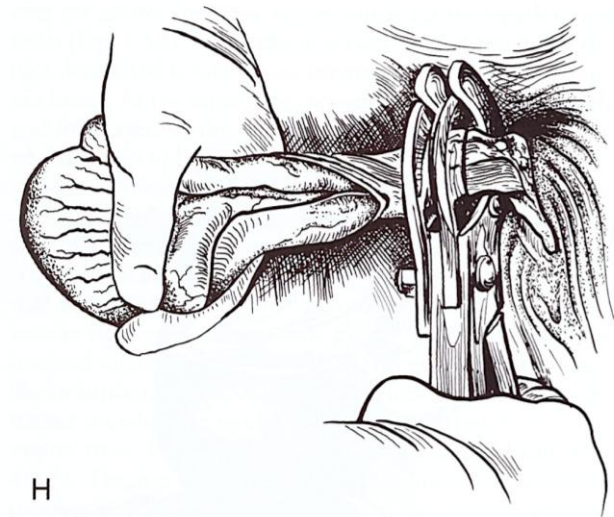
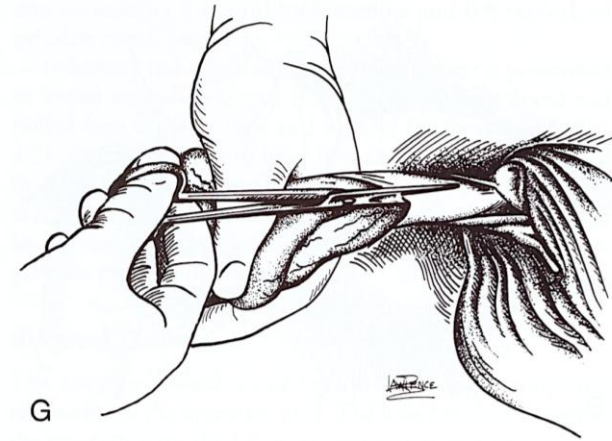
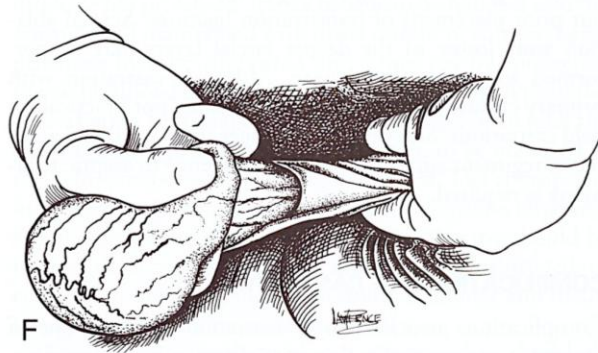
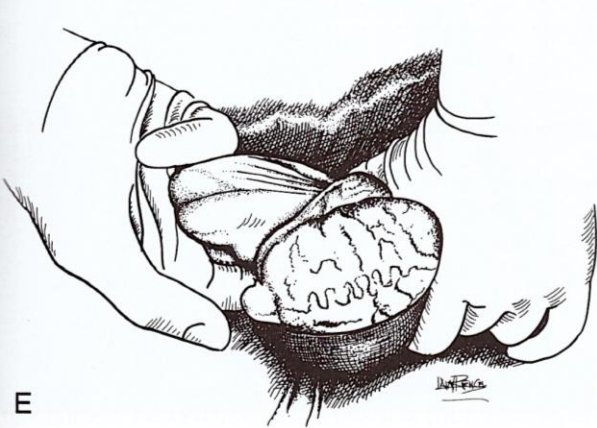Recumbent Castration with a Half- or Semi- or Modified Closed Technique through a Scrotal Approach

- **A)** scrotal incision
- **B)** extruded testicle
- **C)** incision of the parietal vaginal tunic
- **D)** thumb inserted into tunic incision






Recumbent Castration with a Half- or Semi- or Modified Closed Technique through a Scrotal Approach

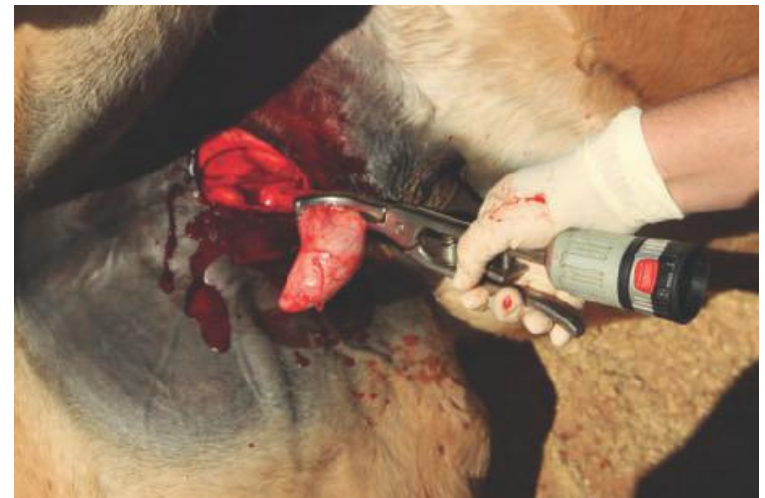
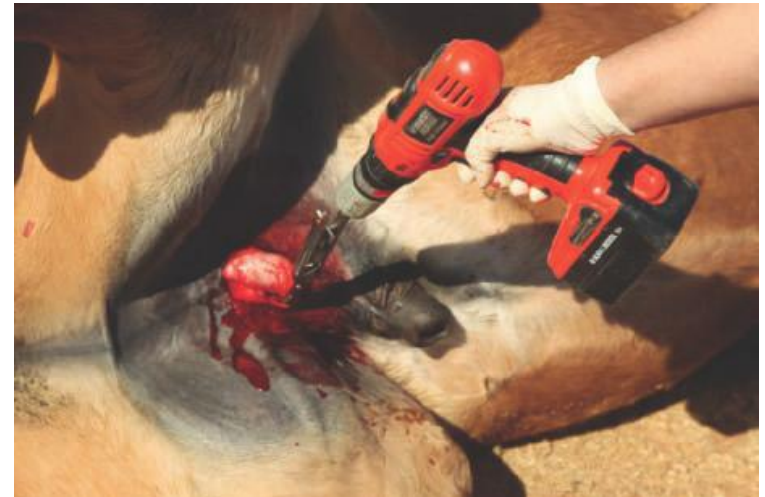
- **E)** prolapsed testicle with fingers hooked into the inverted vaginal tunic
- **F)** stripping scrotal fascia from the spermatic cord
- **G)** extending the incision in the vaginal tunic
- **H)** emasculatation of spermatic cord



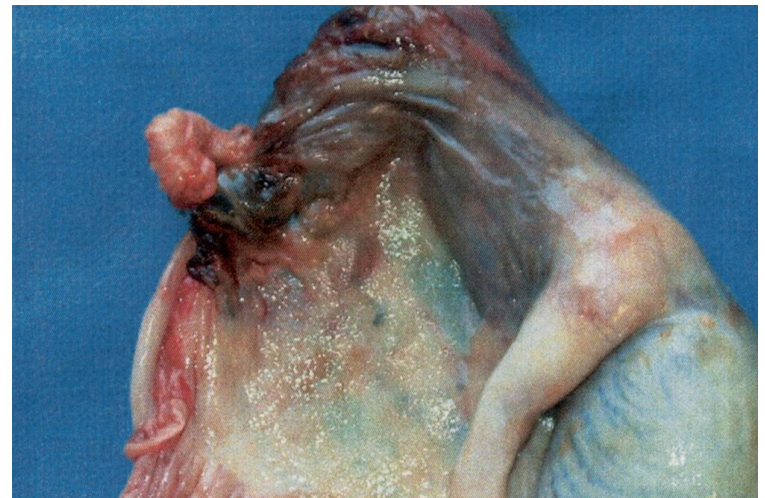
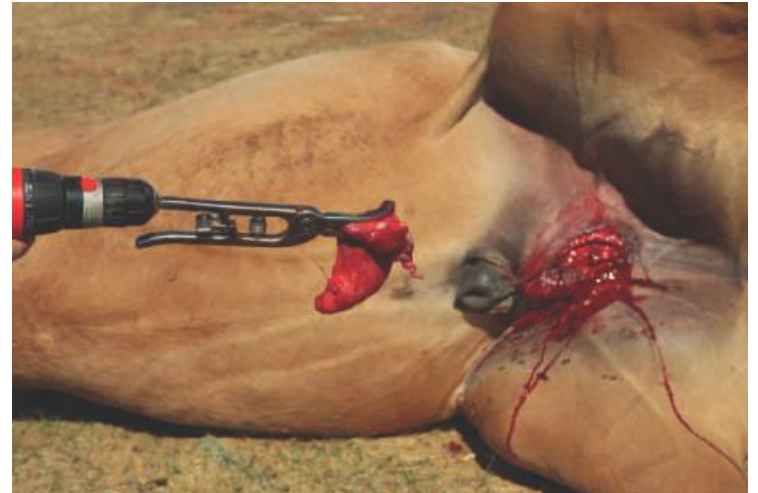Henderson Castration Instrument


- Instrument can be attached to the spermatic cord proximal to the testis to facilitate twisting and severing of the spermatic cord
- Initially upon rotation of the drill, the testis is allowed to partially retract into the scrotum



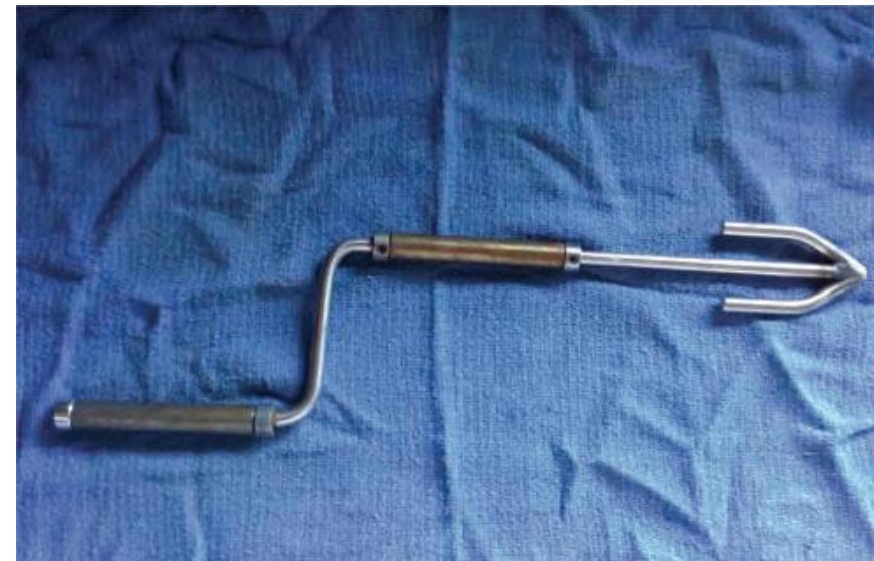Henderson Castration Instrument

- After 20–25 revolutions, the cord and attached structures will be severed in a tightly twisted fashion
- Coiled, sealed segment of spermatic cord attached to testicle

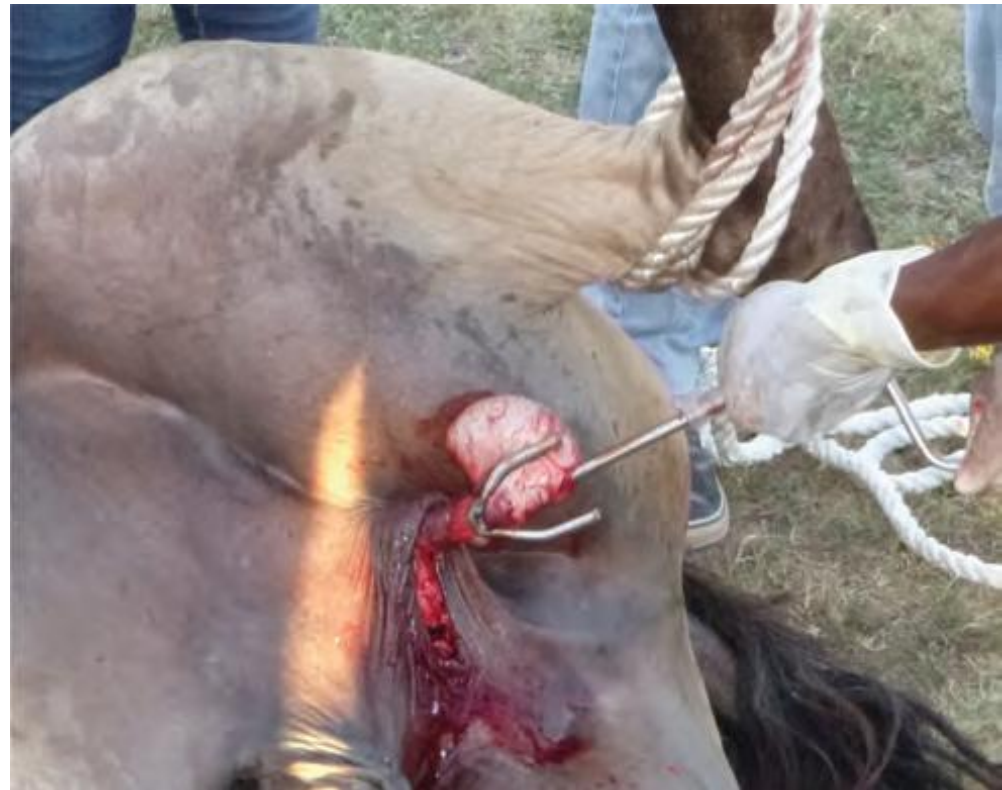




Simplified Castration With the Equitwister



The Equitwister

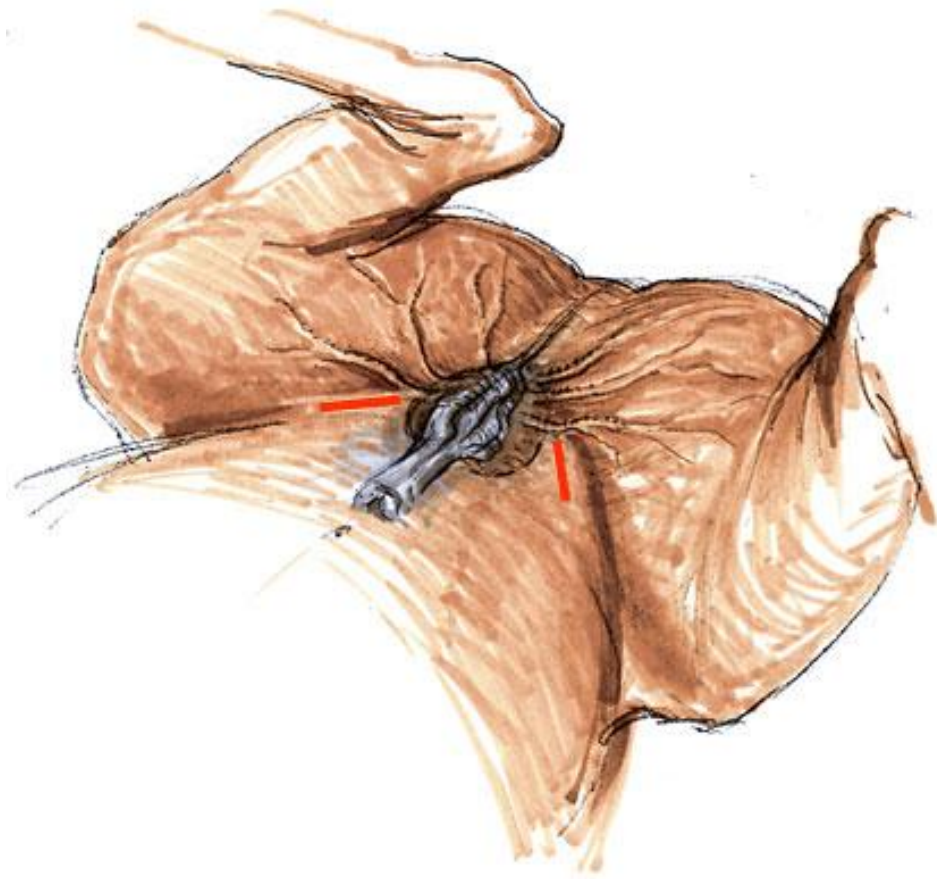



Testicle wrapped between the tines at the end of the shaft. Light pull on the instrument keeps the cord straight, the cord is then twisted by turning the handle



Primary Castration with an Inguinal Approach

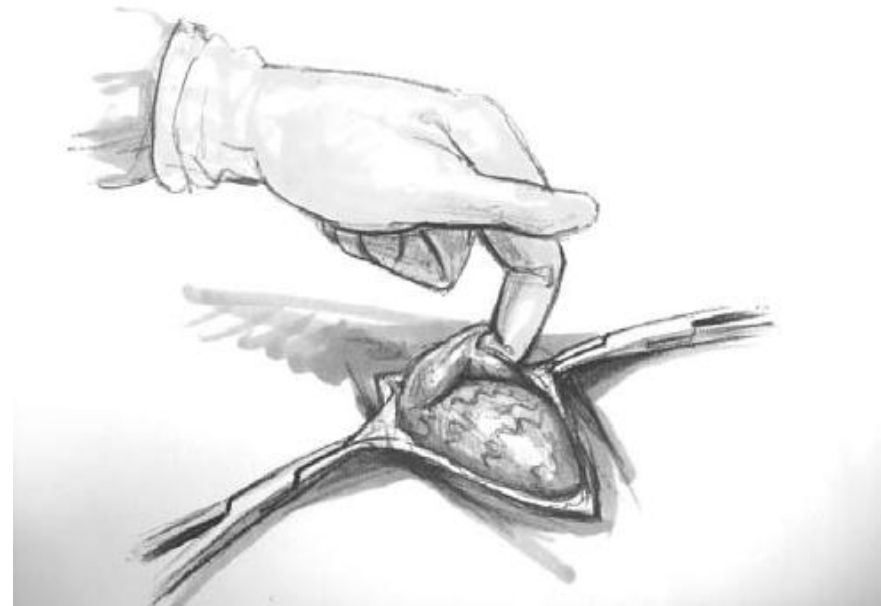- This technique is frequently used when castrating horses 2 years old or older to avoid evisceration
- With the horse anesthetized and surgical field draped
- The testis is pushed craniad from the scrotum so that it lies close to the superficial inguinal ring
- a 5- to 7-cm cutaneous incision is created over the superficial inguinal ring






Primary Castration with an Inguinal Approach

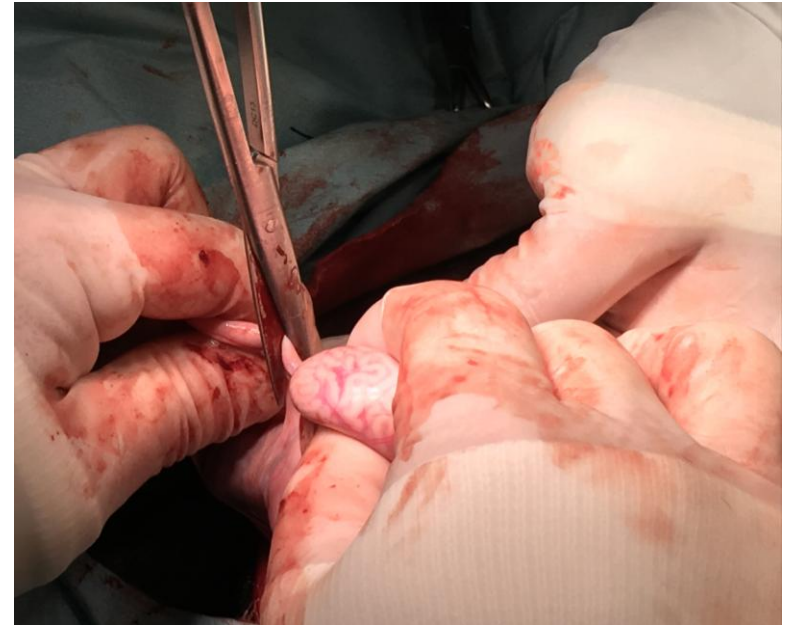
- The inguinal fascia overlying the testis is incised to expose the parietal tunic of the testis
- The parietal tunic is incised longitudinally for 5 cm in an area not covered by the cremaster muscle
- The ligament of the tail of the epididymis is located with an index finger, and by applying traction on this structure, the testis is pulled from the vaginal cavity






Primary Castration with an Inguinal Approach

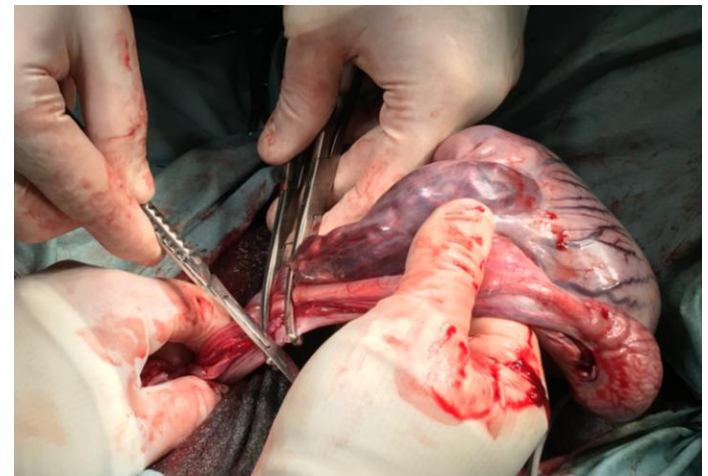
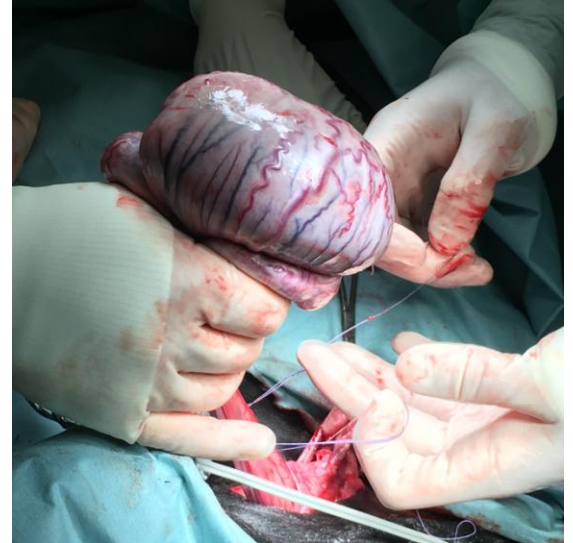- The ligament of the tail of the epididymis is transected
- The mesorchium and the distal part of the mesofuniculum are bluntly separated from the epididymus and the distal part of the spermatic cord respectively
- Bleeding vessels are cauterized to prevent hemorrhage into the vaginal cavity






Primary Castration with an Inguinal Approach

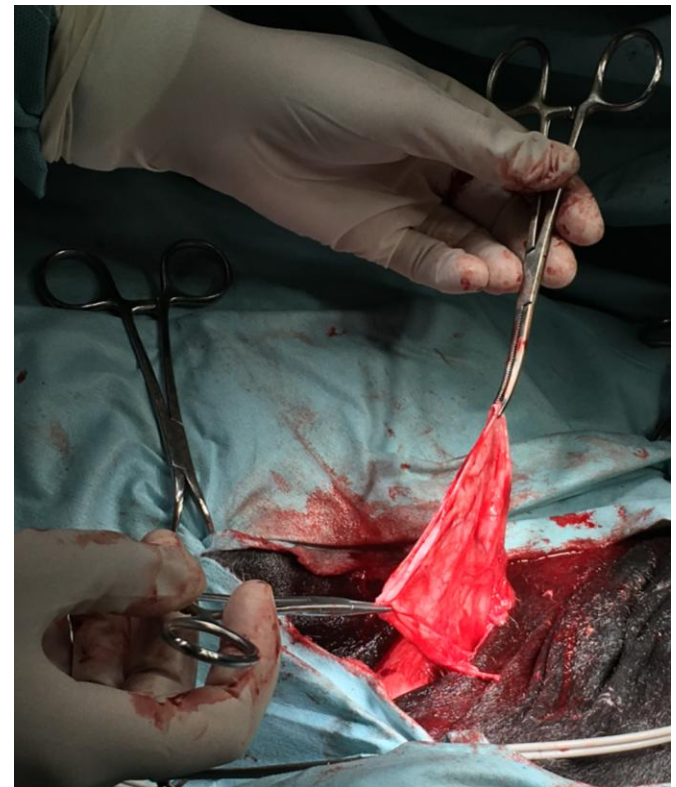
- Two ligatures (one transfixing and one modified Miller's knot) of absorbable heavy suture (2 USP) are applied 1 cm apart, as far proximad as possible, to the spermatic cord
- The vasculature and ductus deferens are severed 2 cm distal to the distal ligature
- After inspection the stump is replaced into the vaginal cavity






Primary Castration with an Inguinal Approach


- The vaginal tunic is closed in a simple continuous pattern using absorbable monofilament 2/0 USP suture
- The overlying fascia is similarly sutured in one or two layer
- The same suture material is used for subcuticular suture of the skin in a simple continuous pattern



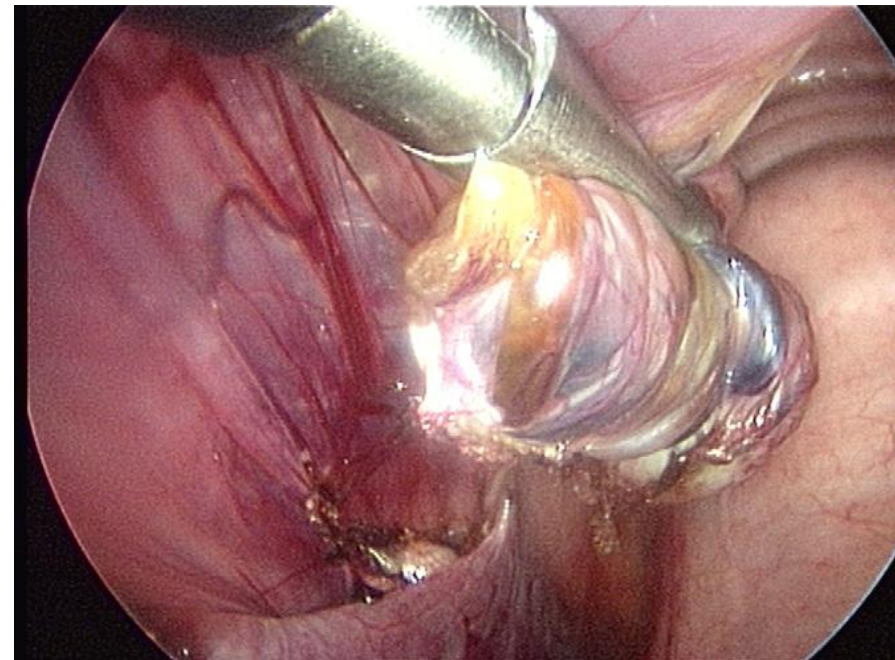
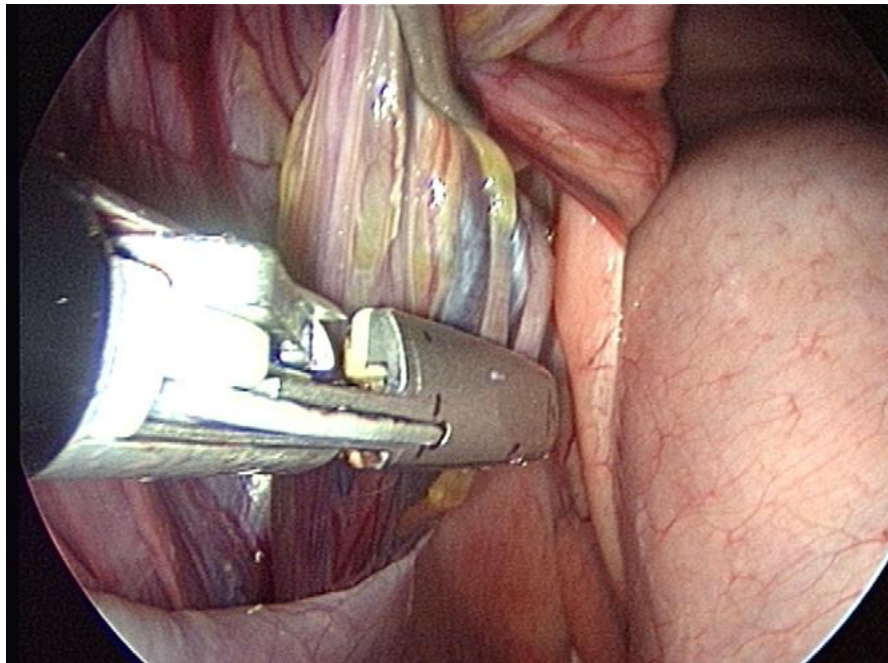


Laparoscopic Castration without Orchidectomy


- **Minimally invasive**
- Excellent **visualization** of the spermatic cord
- Visual **confirmation** that adequate **hemostasis** of the mesorchium occurs
- Eliminates the requirement for **general anaesthesia** and its associated **risks**
- Advantage of a more **rapid return to function**
- **Indications**
 - Horse at risk of general anesthesia
 - Large vaginal rings and risk of evisceration
 - Castration of descended testicle after abdominal cryptorchid castration



Laparoscopic Castration without Orchidectomy



Ligating and transecting the blood supply and ductus deferens of scrotal testes laparoscopically with the horse standing or anesthetized results in **avascular necrosis** of the **testicular parenchyma** with the **testes *in situ***



Laparoscopic Castration without Orchidectomy

EQUINE VETERINARY JOURNAL
Equine vet. J. (2006) 38 (1) 35-39

The complex blood supply to the equine testis as a cause of failure in laparoscopic castration

M. VOERMANS*, A. B. M. RIJKENHUIZEN and M. A. VAN DER VELDEN

5.6% of inguinally retained testes and **3.4%** of normally descended testes failed to become completely necrotic as a result of an **alternative blood supply** from the cremasteric or external pudental artery or both

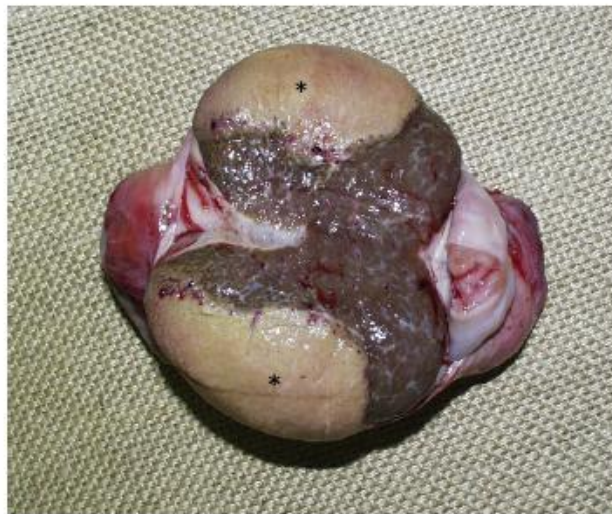

Fig. 1. Macroscopic appearance of the cut surface of a testis that underwent incomplete necrosis after laparoscopic castration. *Necrotic tissue.

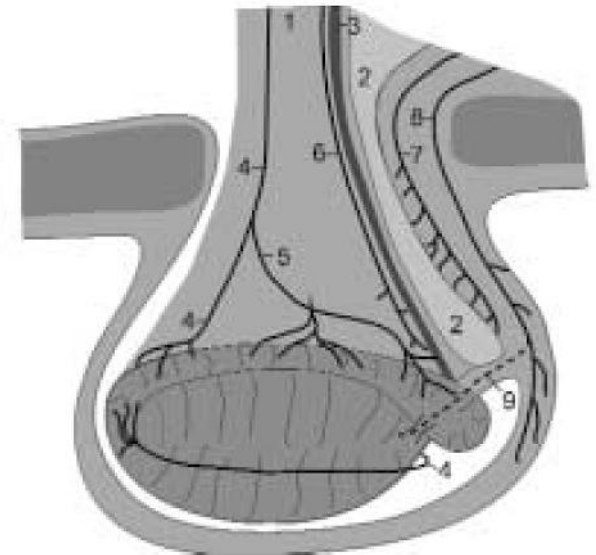




Fig 1: Blood supply to the testis and epididymis. 1 = Spermatic cord; 2 = mesorchium; 3 = ductus deferens; 4 = testicular artery; 5 = epididymal artery; 6 = deferential artery; 7 = cremasteric artery; 8 = external pudental artery; 9 = tributary from the external pudental artery.




Cryptorchidectomy

- **Cryptorchidism** (*'hidden testis'*) refers to the failure of descent of one or both testes from the fetal position in the scrotum
- The term **cryptorchid** is used to describe the nondescend testis and by extension affected horses
- **Colloquial terms** for the condition include:
 - Rig
 - Ridgling
 - Original
- Monorchid, Anorchid, Polyorchid, False rig



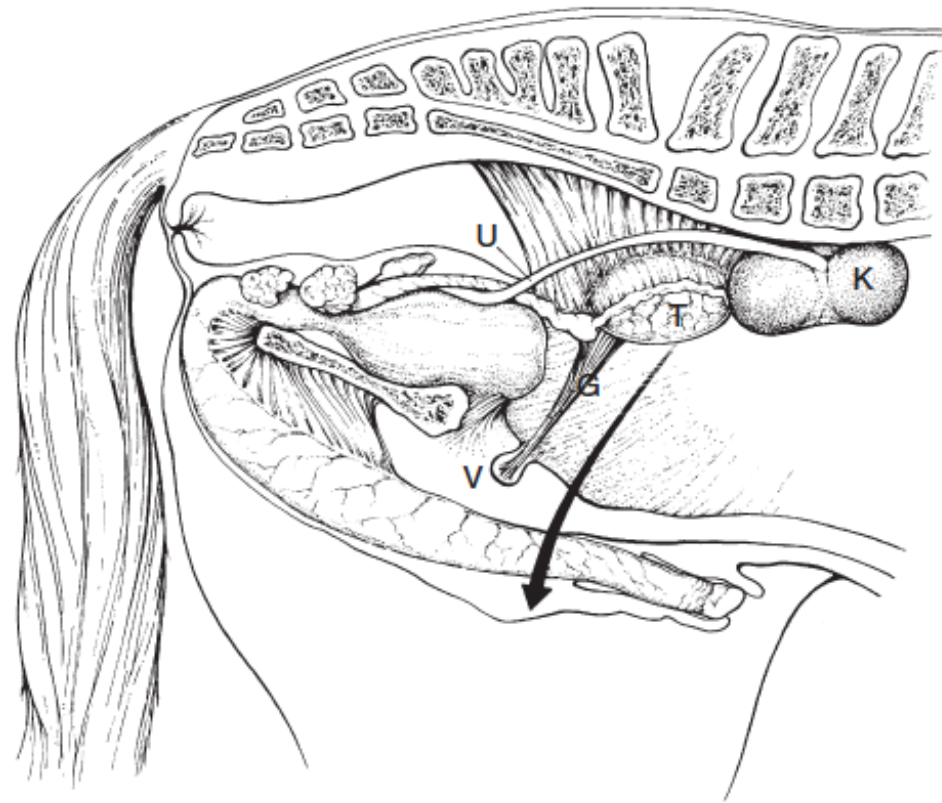
Cryptorchidectomy

- **Retrospective studies** of large numbers indicate:
 - retention of the **right** and **left** testis occurs nearly equally
 - **unilateral** retention occurs about nine times more often than does **bilateral retention**
 - most (about 60%) retained **right** testes are located **inguinally**
 - **abdominal retention** more commonly occurs with the **left** testis (right testis is smaller than the left during the stage of testicular regression)
 - **bilateral abdominal** retention of testes is nearly 2.5 times more prevalent than **bilateral inguinal** retention
 - the occurrence of **both abdominal** and **inguinal** testes in the same horse is relatively uncommon



Descent of the Testis: Gubernaculum

- Divided into **three parts**:
 - Cranial part becomes the ***proper ligament of the testis***
 - Middle part becomes the ***ligament of the tail of the epididymis***
 - Caudal or scrotal part become the ***scrotal ligament***: in abdominally retained testis is referred to as the ***inguinal extension of the gubernaculum testis***



Inguinal Canal

- oblique **passage** in the abdominal wall

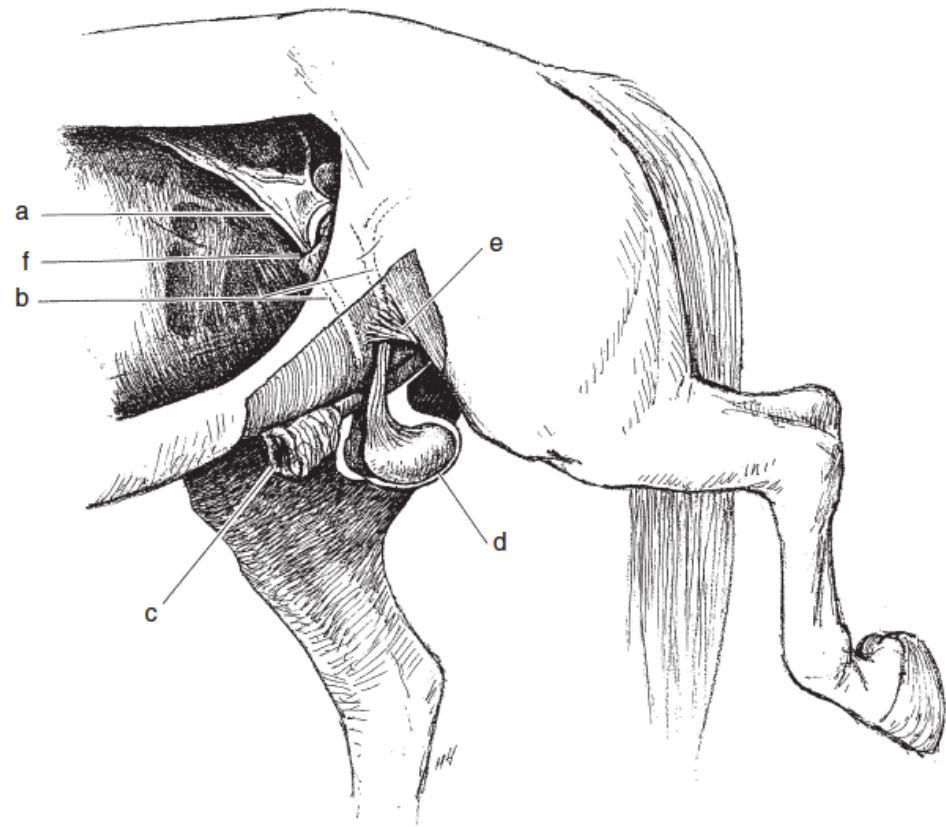
- spermatic cord, genito-femoral nerve, external pudendal vasculature and the efferent lymphatic vessels

- internal opening

- **deep inguinal ring** is a slit bordered cranially by the caudal edge of the internal abdominal oblique muscle, ventromedially by the rectus abdominis muscle and prepubic tendon and caudally by the inguinal ligament


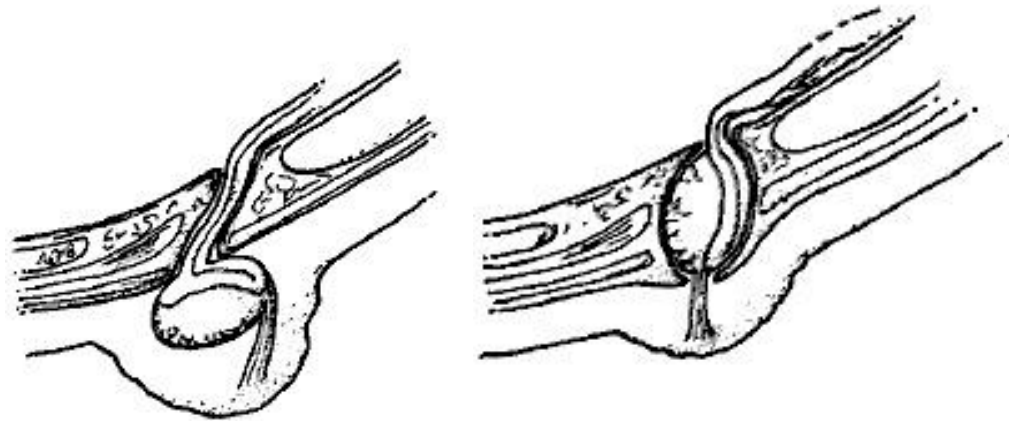
- external opening


- **superficial inguinal ring:** is a slit in the external abdominal oblique muscle



Criptorchidism in Horses: Classification

- **Inguinal** retention
 - testis situated **external** to the superficial inguinal ring
 - testis situated **within** the inguinal canal
- **Partial or Incomplete Abdominal** retention
- **Complete Abdominal** retention





Inguinal Cryptorchid Testis

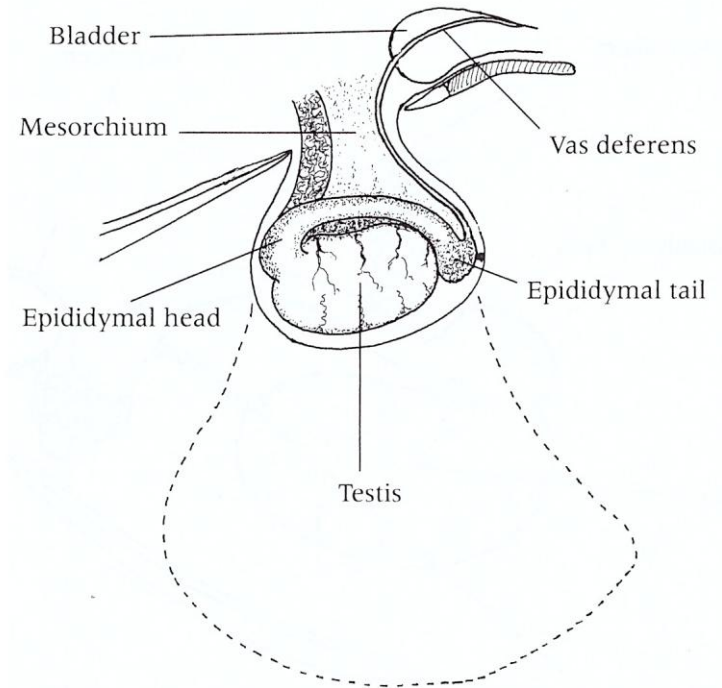
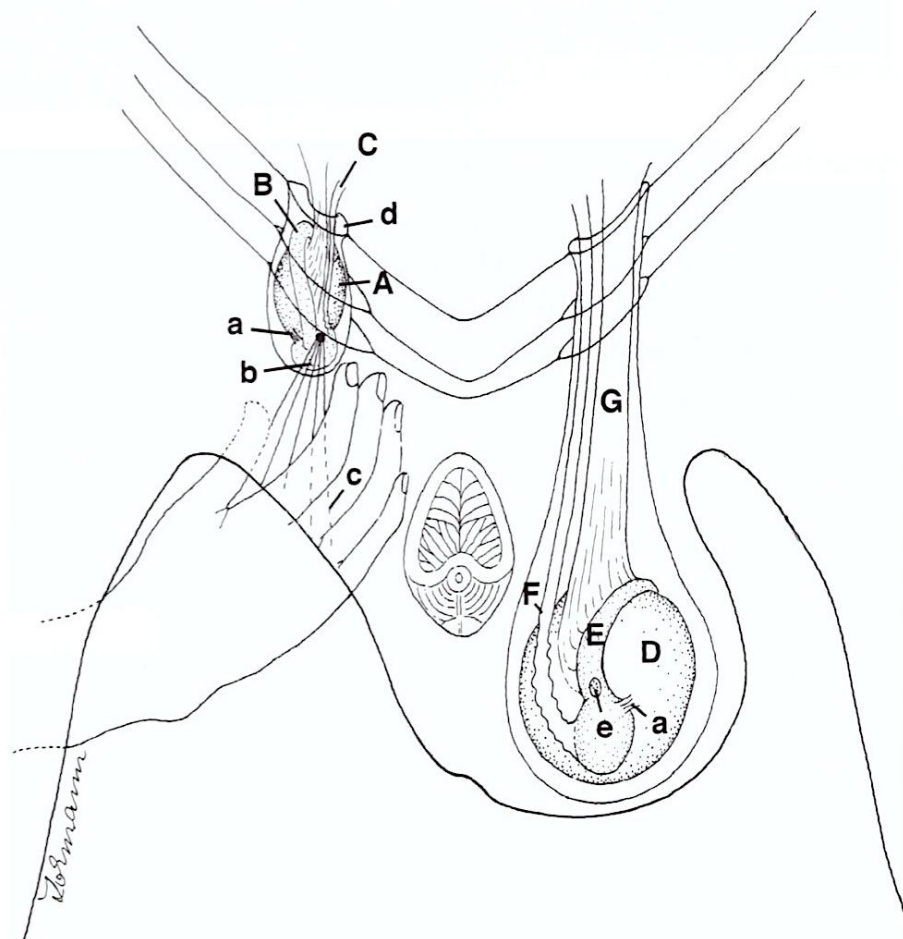



FIG. 98-2. Inguinal testis retained just outside the inguinal canal. The dotted line shows the approximate size and position of the vaginal tunic of a scrotal testis. The mesorchium suspends the vascular cone and deferent duct, the latter passing onto the dorsal surface of the empty bladder.



Partial or Incomplete Abdominal Cryptorchid Testis

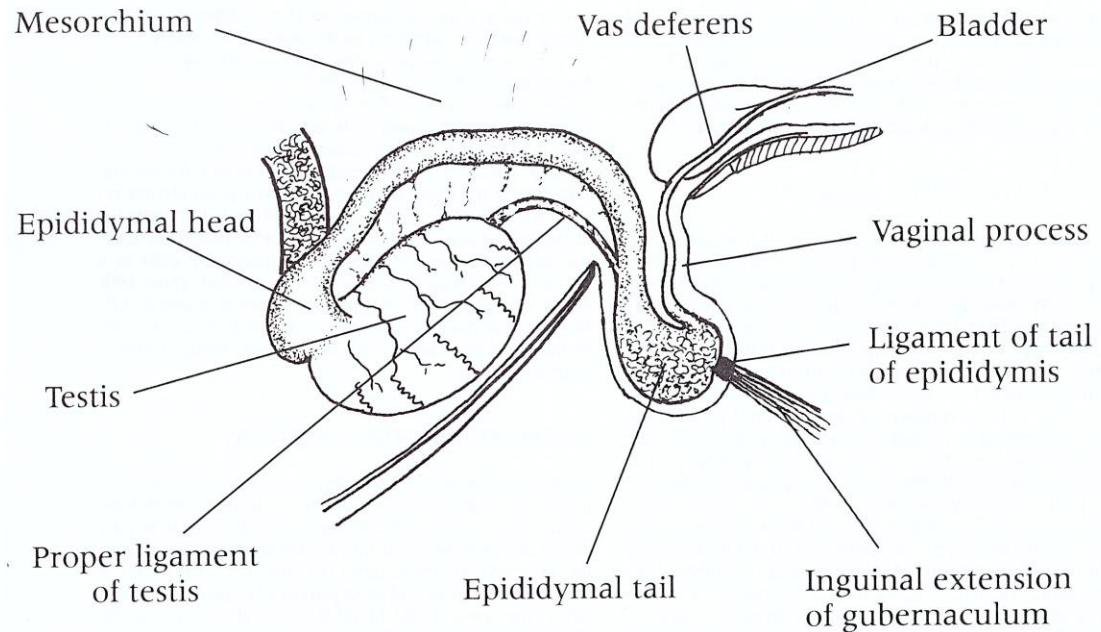
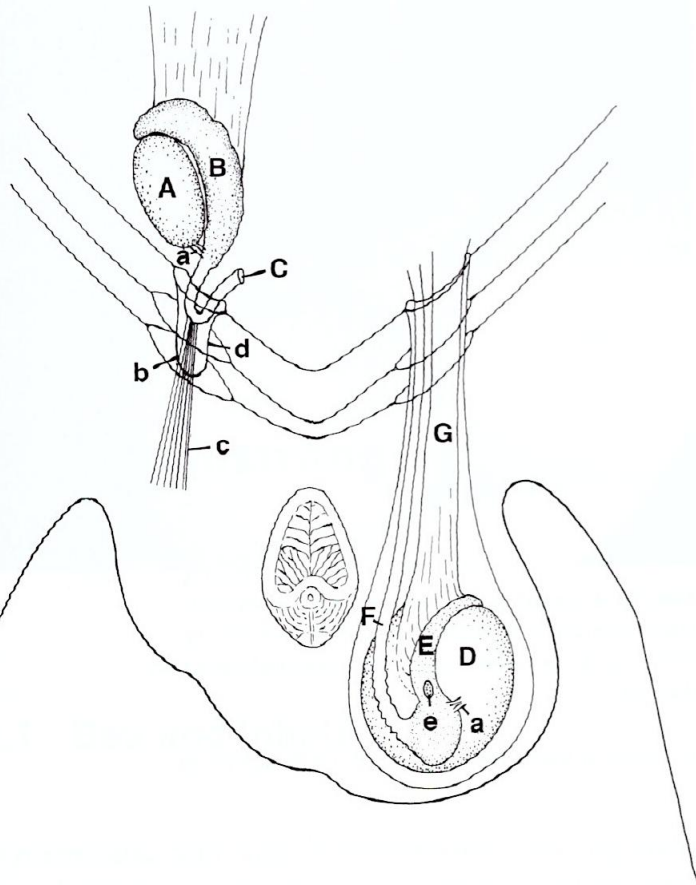



FIG. 98-3. Incomplete abdominal retention with testis in the abdomen, but the epididymal tail has descended through inguinal canal. The vaginal process contains epididymal head, part of epididymal body, and part of deferent duct.



Complete Abdominal Cryptorchid Testis

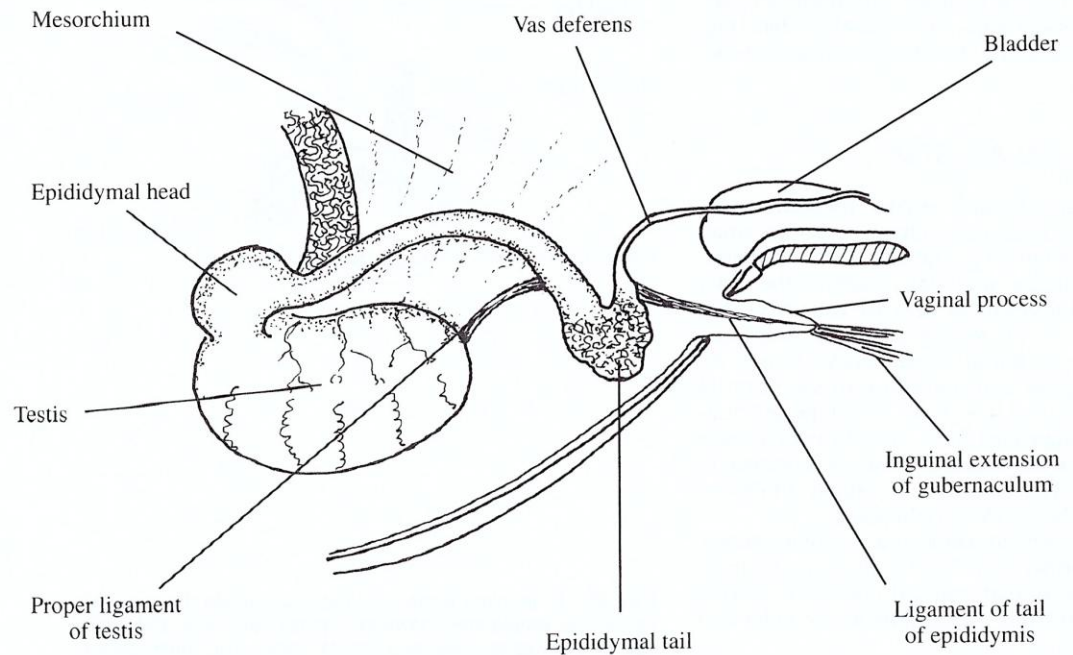
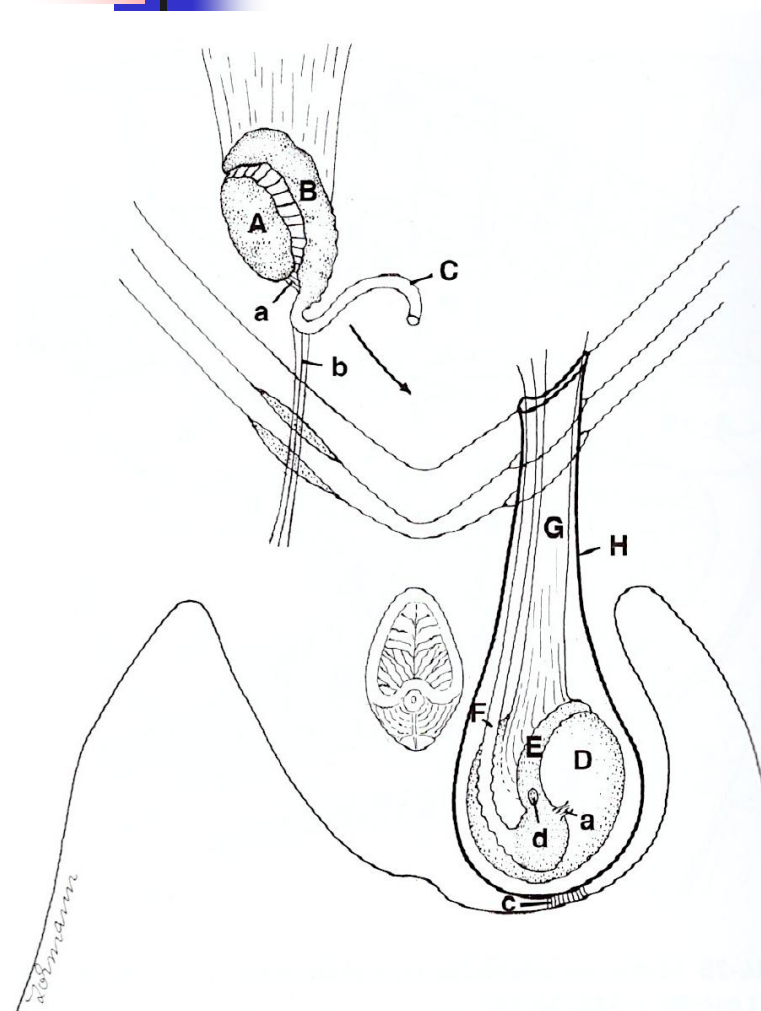
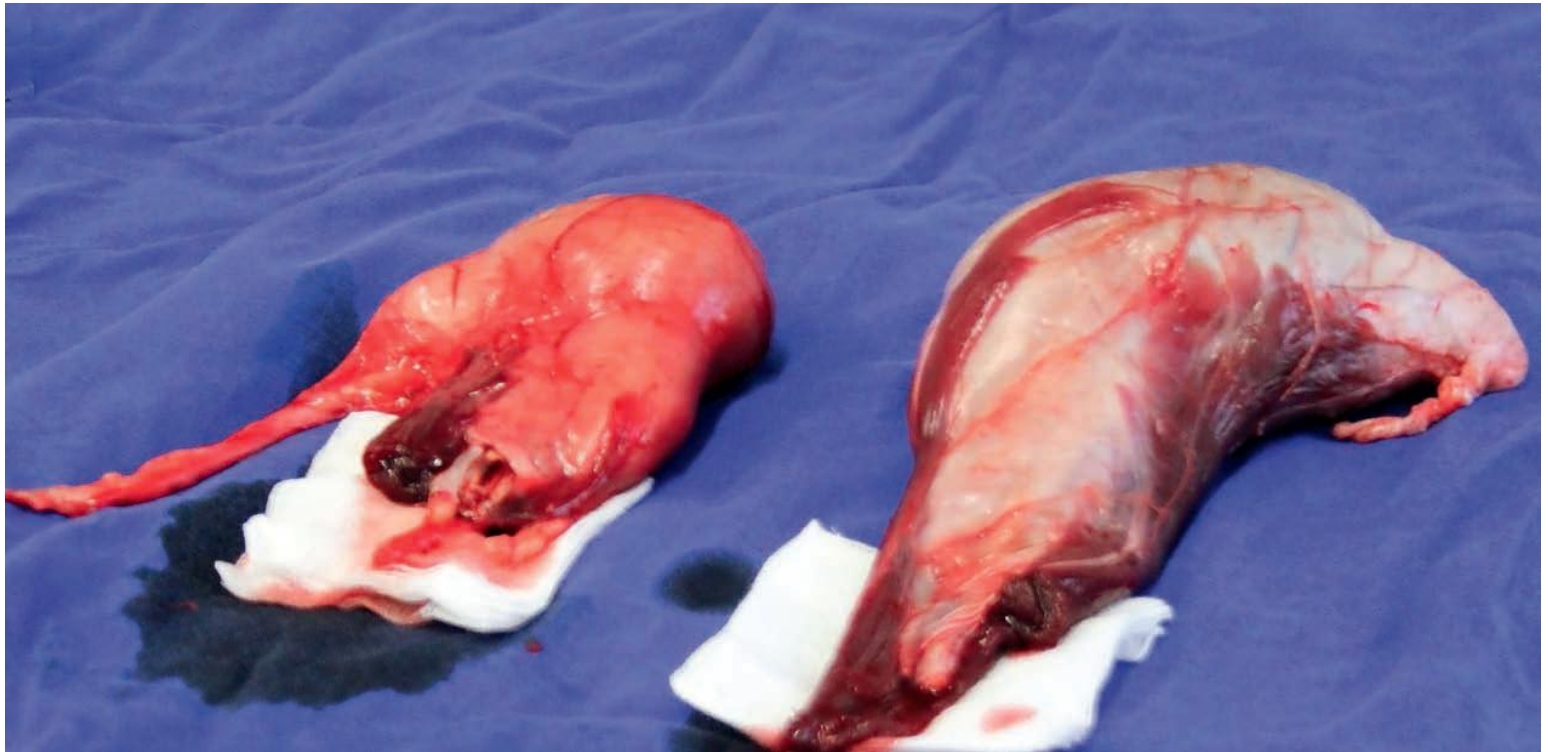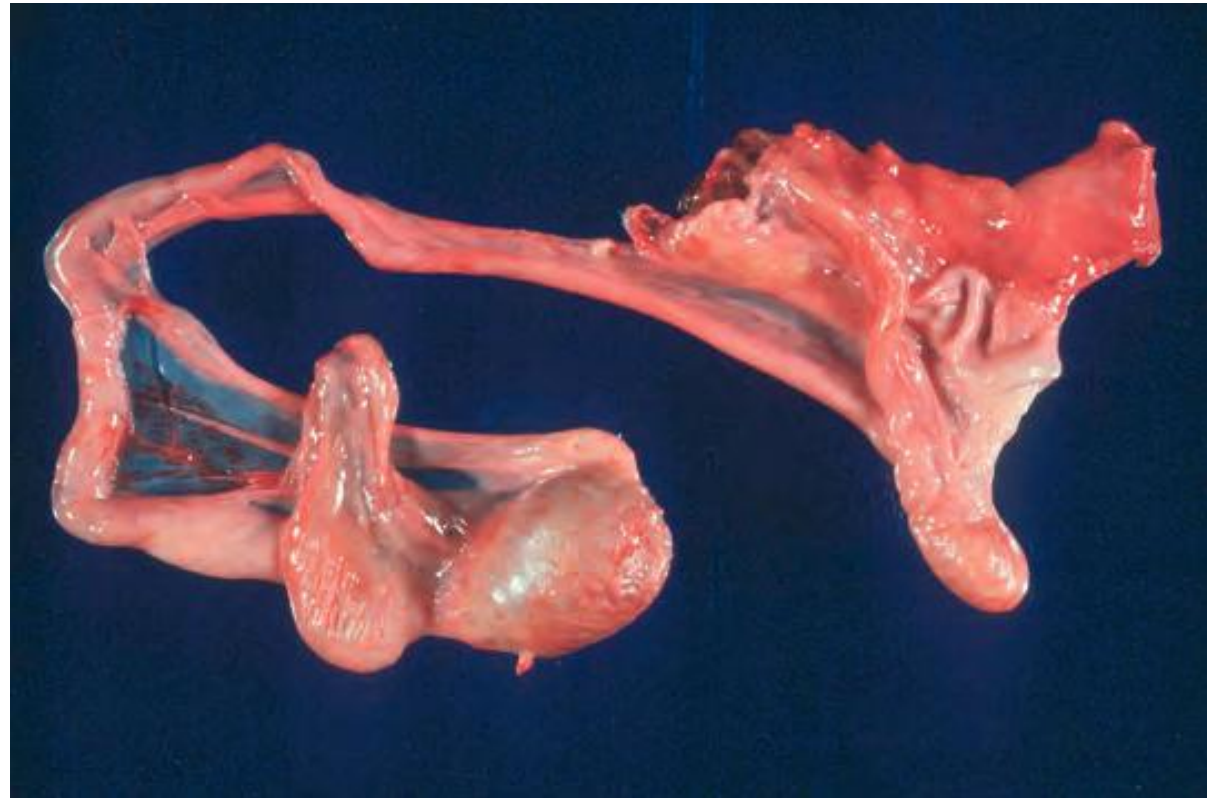

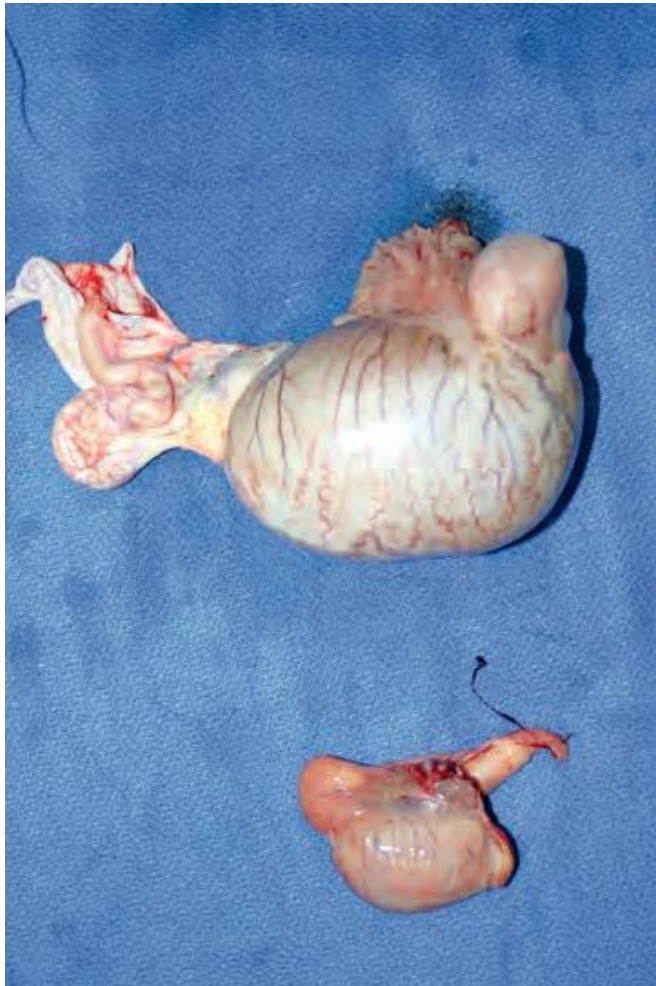

FIG. 98-1. Abdominal testis and epididymis completely retained in the abdomen. The small vaginal process contains the ligament of tail of epididymis.

Descended and retained testes




Descended and retained testes





Cryptorchidectomy

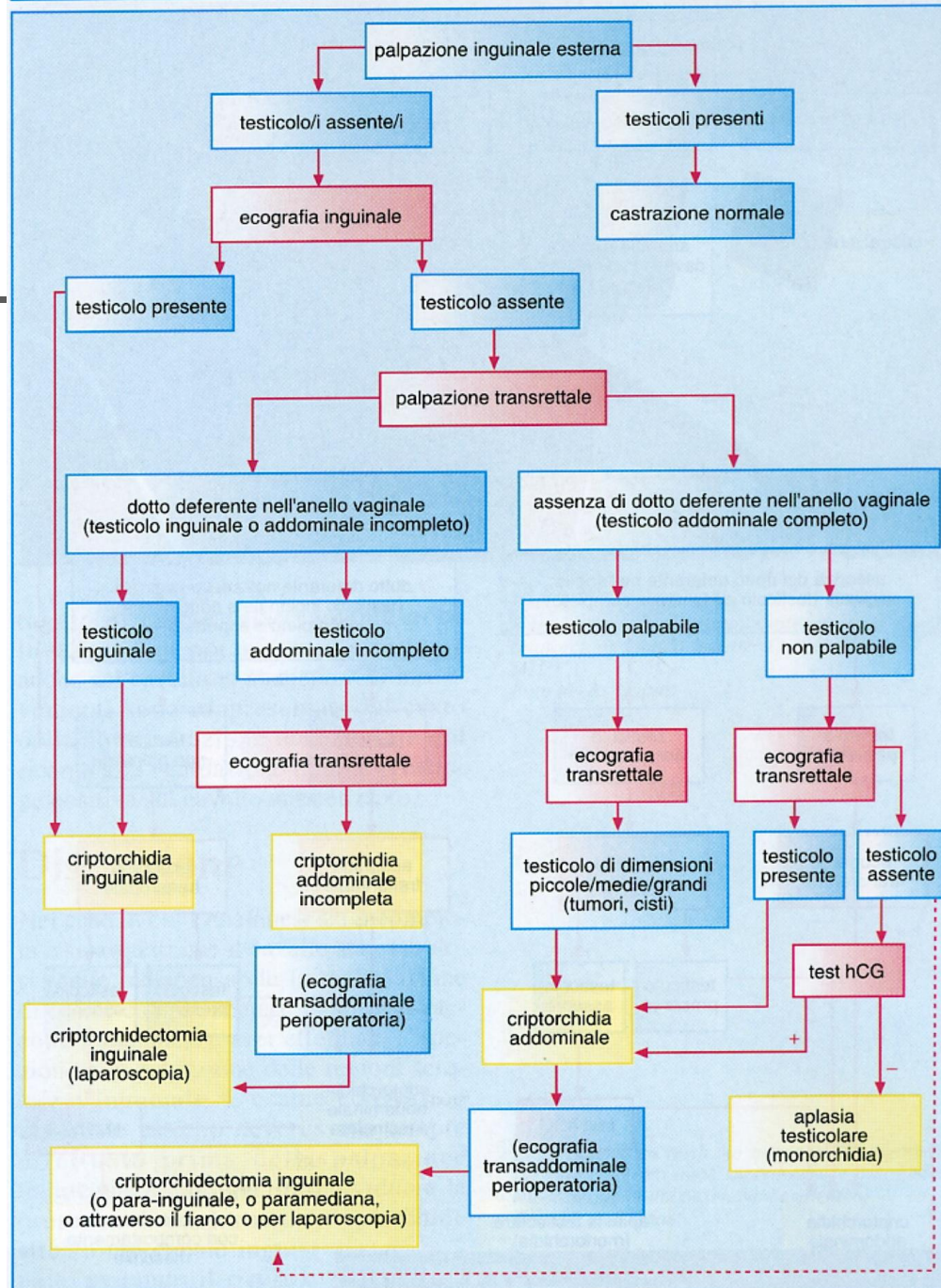

- **Diagnosis** of cryptorchidism:
 - easily if no attempt has been made to castrate the horse
 - external palpation of the scrotum reveals the absence of one or both testes
 - gonadal agenesis is extremely rare
 - if the history that the horse has not been castrated is reliable, the retained testis must be in an ectopic, inguinal, or abdominal position
 - Horse purchased as geldings but displaying stallion-like behavior pose more of a diagnostic challenge



Cryptorchidectomy

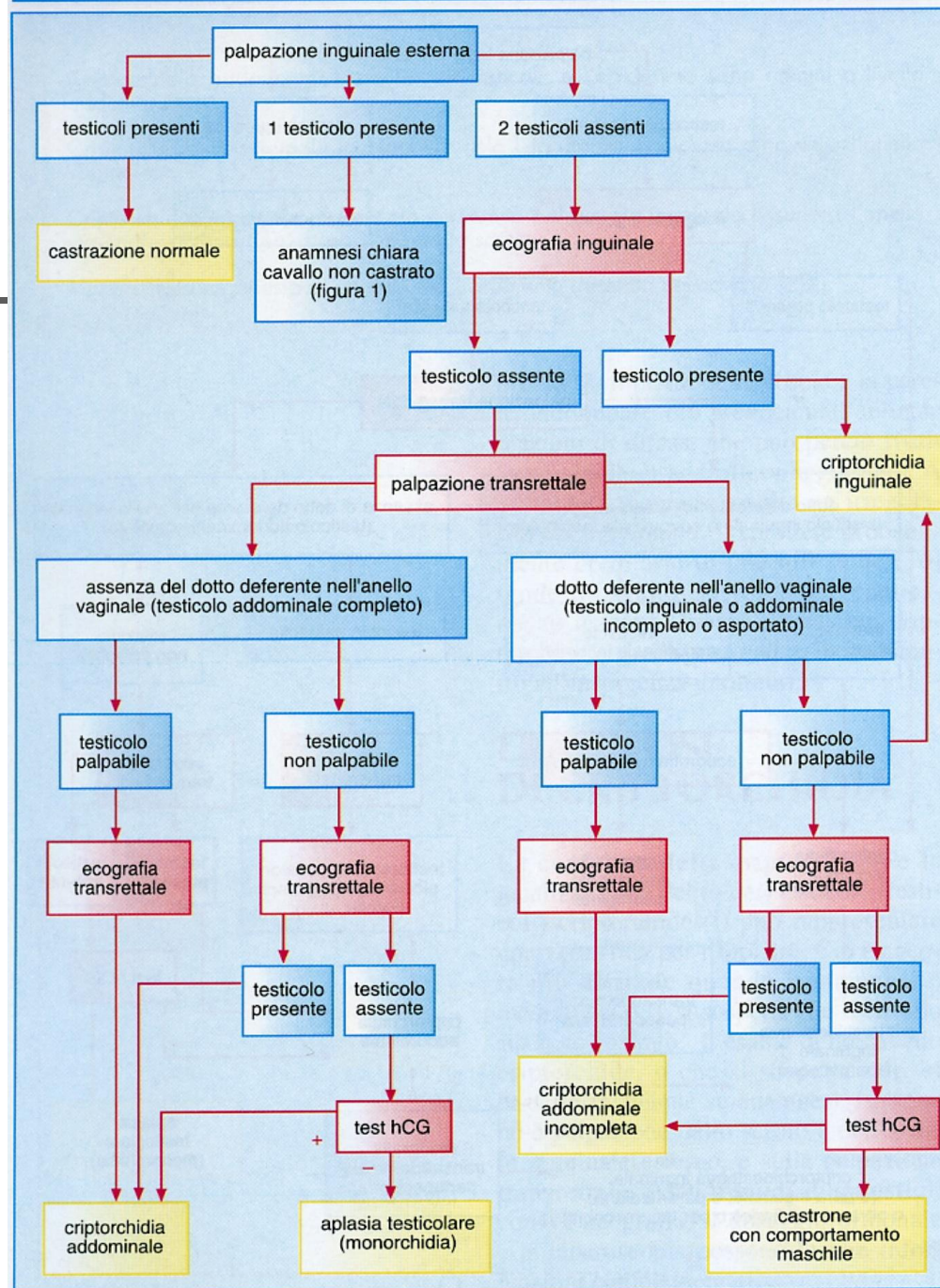
- Diagnostic **work up** of cryptorchidism:
 - Good case **history** very important
 - **Physical examination**
 - visual inspection and palpation of the scrotum and the inguinal region
 - rectal examination
 - **Ultrasound examination**
 - transrectal
 - transcutaneous inguinal
 - **Hormonal assays** (plasma or serum testosterone and estrone sulfate)
 - **Diagnostic laparoscopy**


Anamnesi chiara, il cavallo non è stato operato





Anamnesi lacunosa o dubbia






Cryptorchidectomy

■ Surgical approaches


- ***Invasive*** (requires insertion of a entire hand into the abdomen)
 - **Abdominal exploration through the inguinal canal**
 - **Suprapubic paramedian**
 - **Flank laparotomy**
- ***Noninvasive*** (the testis can be removed by introducing only two fingers or less into the abdominal cavity)
 - **Inguinal approach with eversion of the vaginal process**
 - **Parainguinal approach**
- ***Minimalinvasive***
 - **Laparoscopic cryptorchidectomy**



Cryptorchidectomy

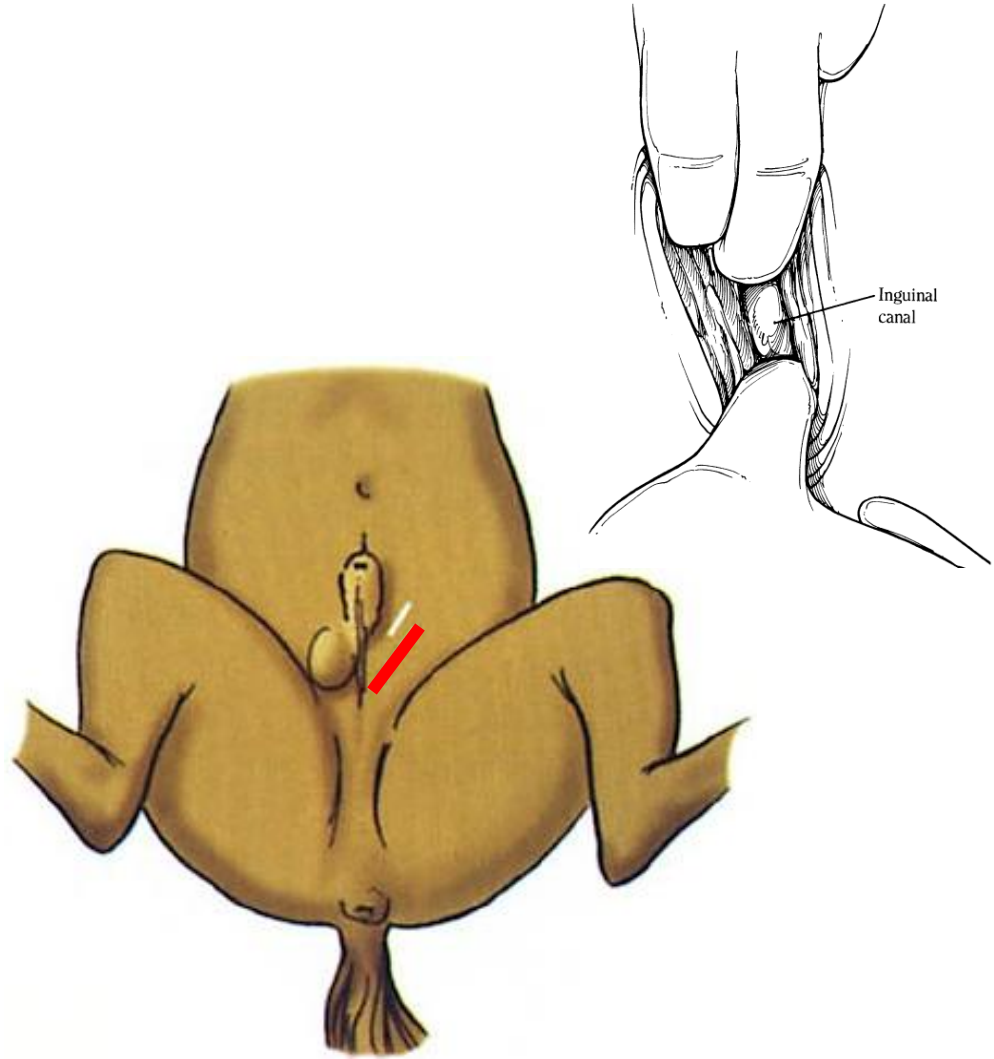
■ Selection of the surgical approaches


- The **paramedian** and **flank** approaches allow removal of only an abdominal testis (*retraction of an inguinal testis into the abdomen can usually be accomplished only with difficulty*)
- The **inguinal** approach allows removal of either an abdominal or an inguinal testis
- Except for the **flank** and **laparoscopic standing** approaches the horse must be anesthetized
- When general anesthesia is not practical an **abdominal testis** can be removed with the horse standing
- Castration of **partial cryptorchid** by the **inexperienced surgeon** may result in removal of the tail of the epididymis inadvertently leaving the testis within the abdomen



Cryptorchid Castration: No Invasive Inguinal Approach

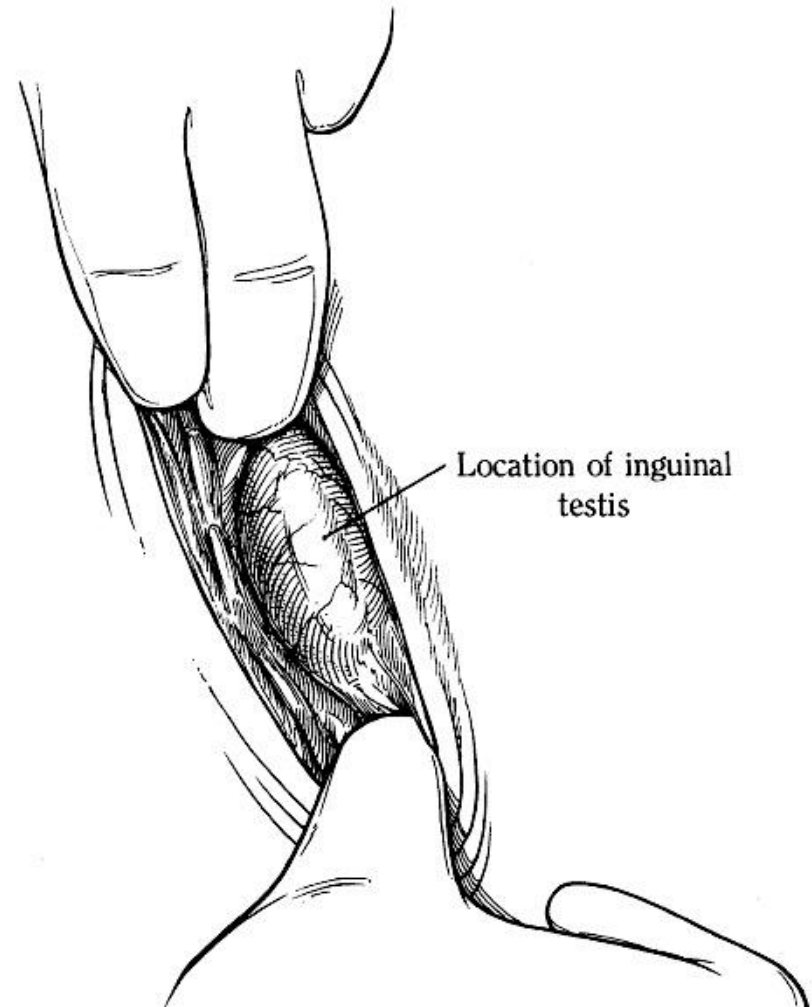
- The horse is anesthetized and positioned in dorsal recumbency
- The superficial inguinal ring is exposed through an 8- to 15-cm skin incision (depending on the horse's size) made directly over the superficial inguinal ring
- The inguinal fascia is separated digitally to expose the superficial inguinal ring






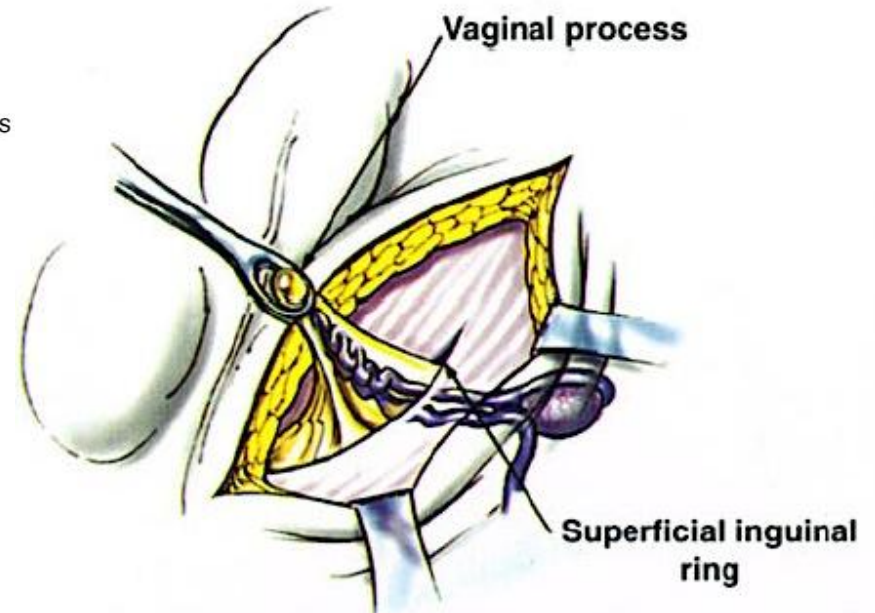
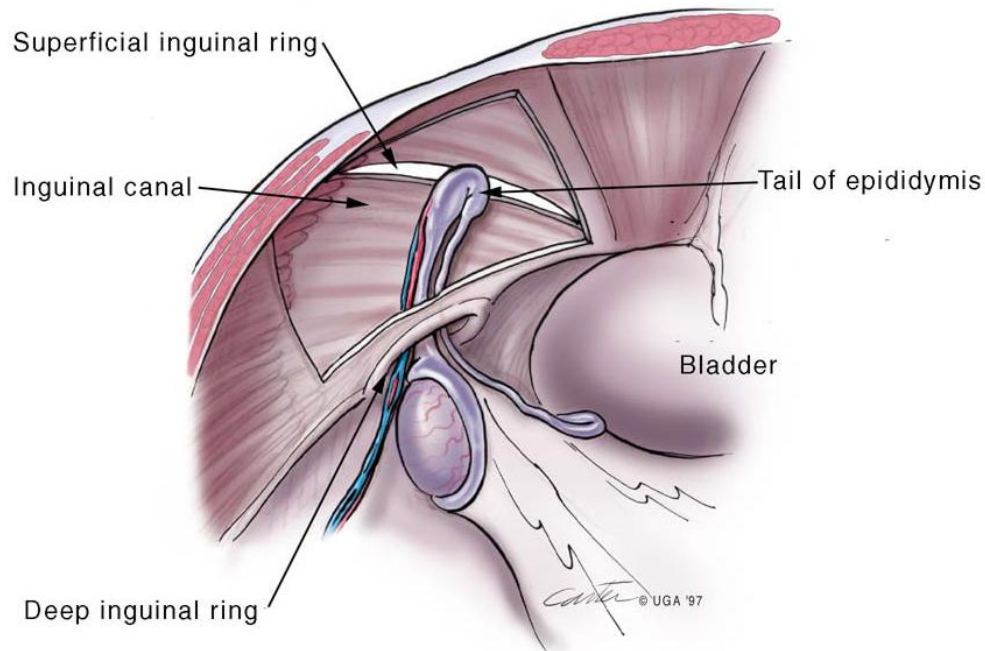
Cryptorchid Castration: Noinvasive Inguinal Approach

- An inguinal testis is readily encountered when the superficial inguinal ring is exposed
- If the testis has already been removed, the stump of the spermatic cord is encountered as it exits the canal
- An abdominal testis can be retrieved locating the rudimentary common vaginal tunic or *vaginal process*






Noninvasive Inguinal Approach: Partial Abdominal Cryptorchid



The vaginal process of the partial abdominal cryptorchid testis lies **everted within the inguinal canal** and is readily encountered during inguinal exploration



Noninvasive Inguinal Approach: Complete Abdominal Cryptorchid

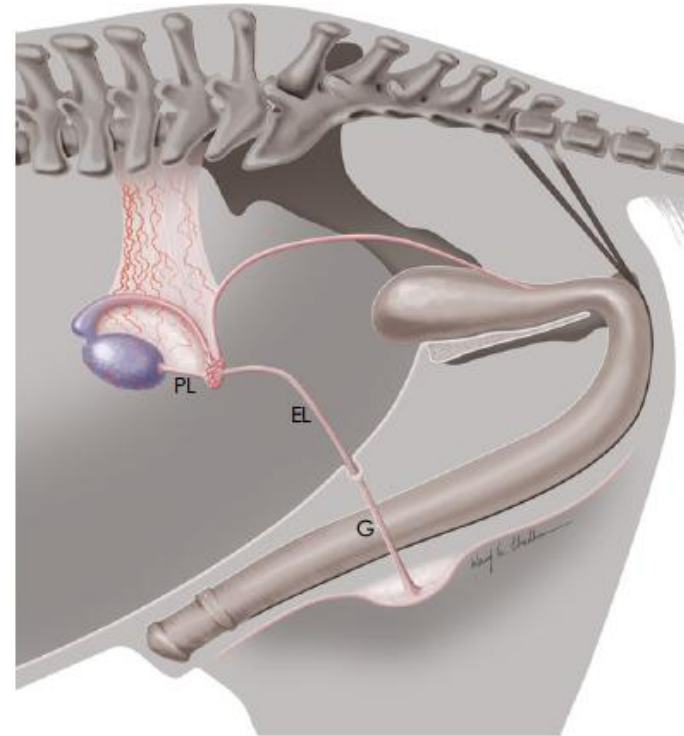
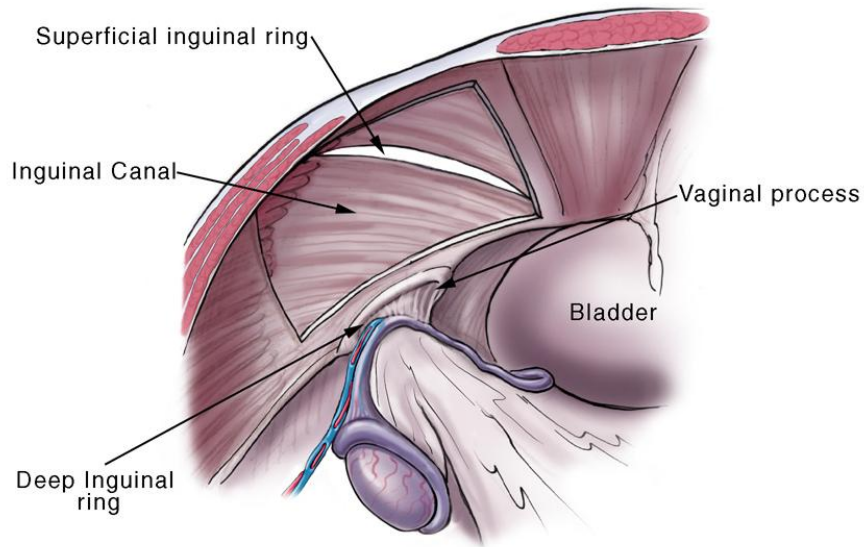



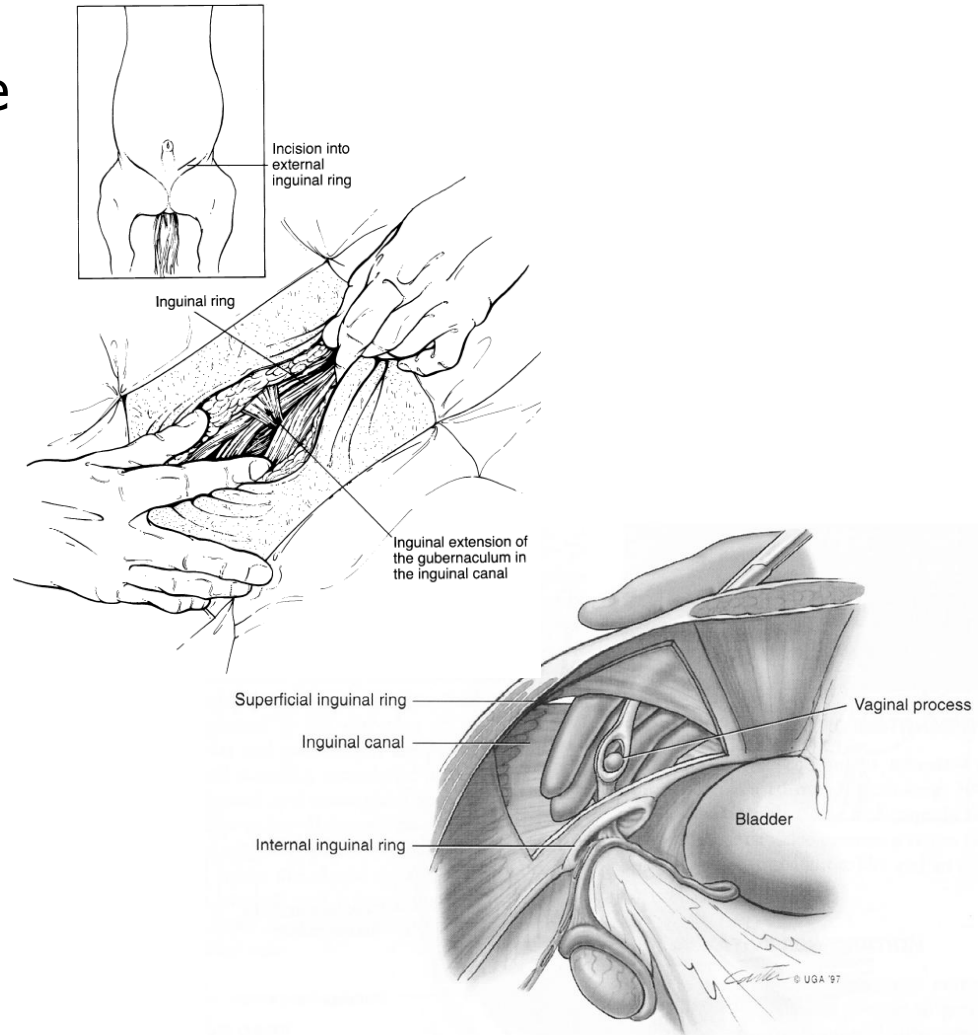
Fig 1: Structures used during location of an abdominal cryptorchid testicle. PL, proper ligament; EL, ligament of the tail of the epididymis; G, inguinal extension of the gubernaculum. Image


The vaginal process of the complete abdominal cryptorchid lies **inverted within the abdominal cavity**, along with the epididymis and testis, and difficulty may be encountered in locating and everting it into the canal



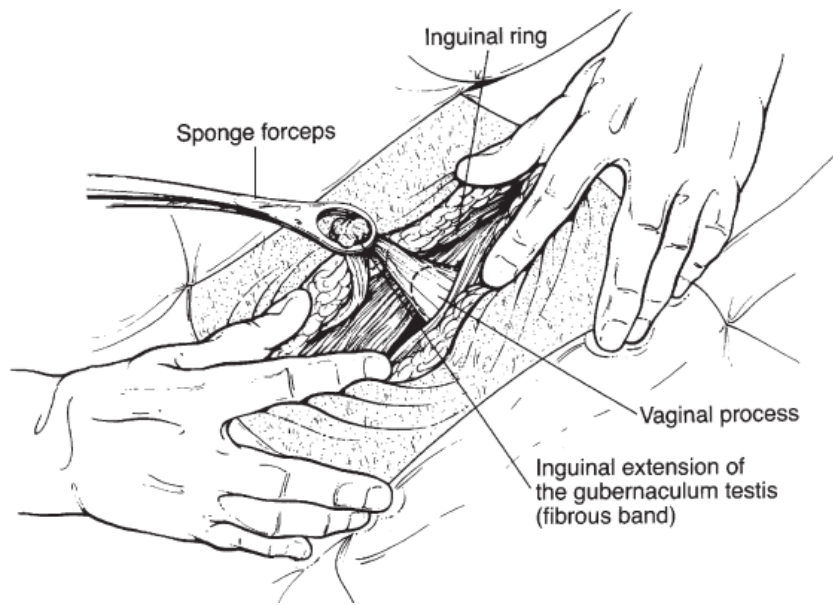
Cryptorchid Castration: Noninvasive Inguinal Approach

- An inverted vaginal process can be everted into the inguinal canal by exerting traction on the *scrotal ligament* (also known as the inguinal extension of the *gubernaculum testis*)
- The IEGT is located by examining the margin of the superficial inguinal ring for a fibrous band that descends into the canal
- An inverted vaginal process can also be everted using a sponge forceps

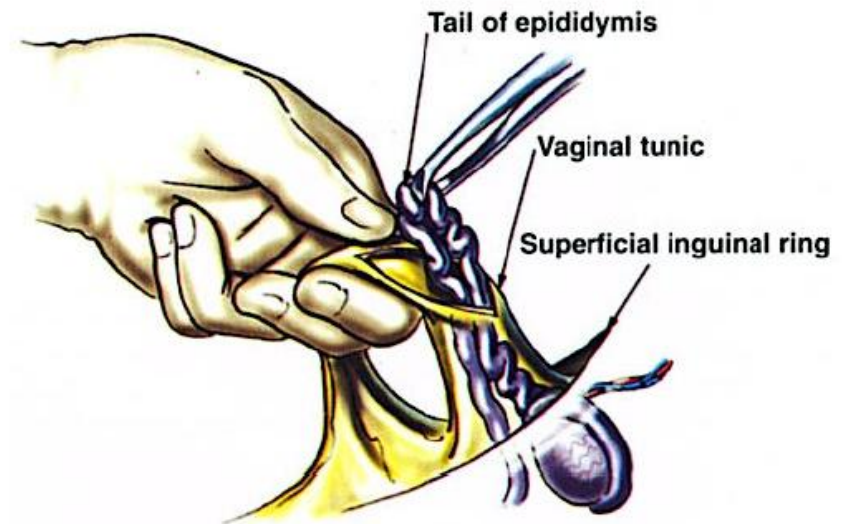





Cryptorchid Castration: Noinvasive Inguinal Approach



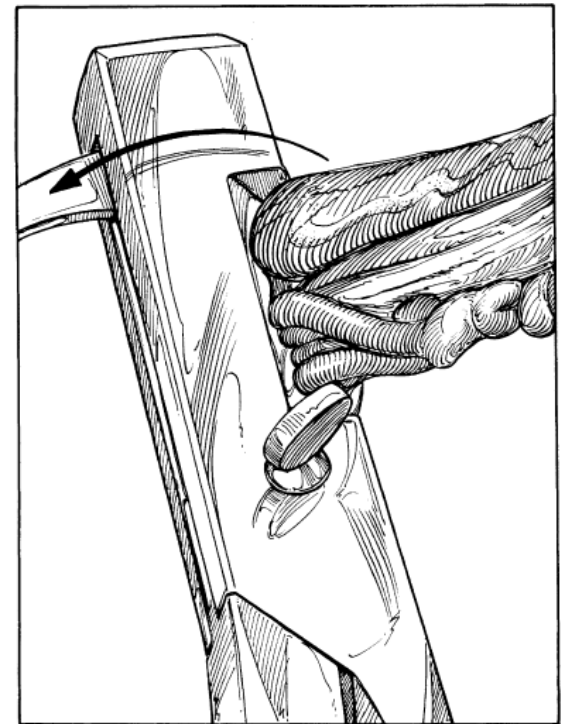
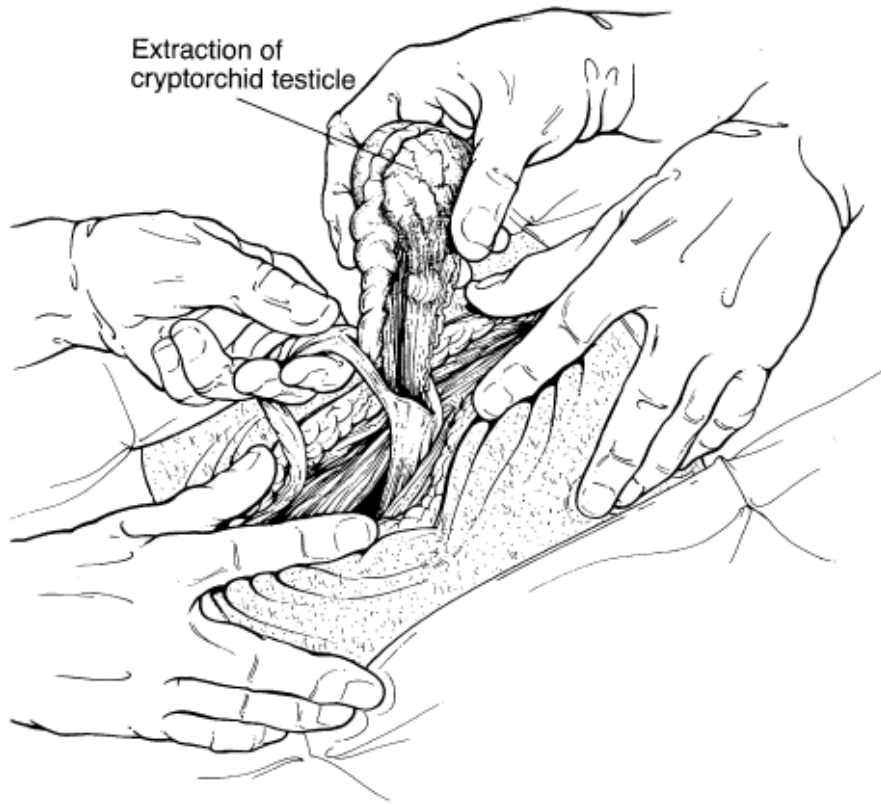
After the vaginal process is everted and stripped of inguinal fascia, it is incised longitudinally




The epididymis contained within is grasped with a hemostat and exteriorized



Cryptorchid Castration: Noinvasive Inguinal Approach

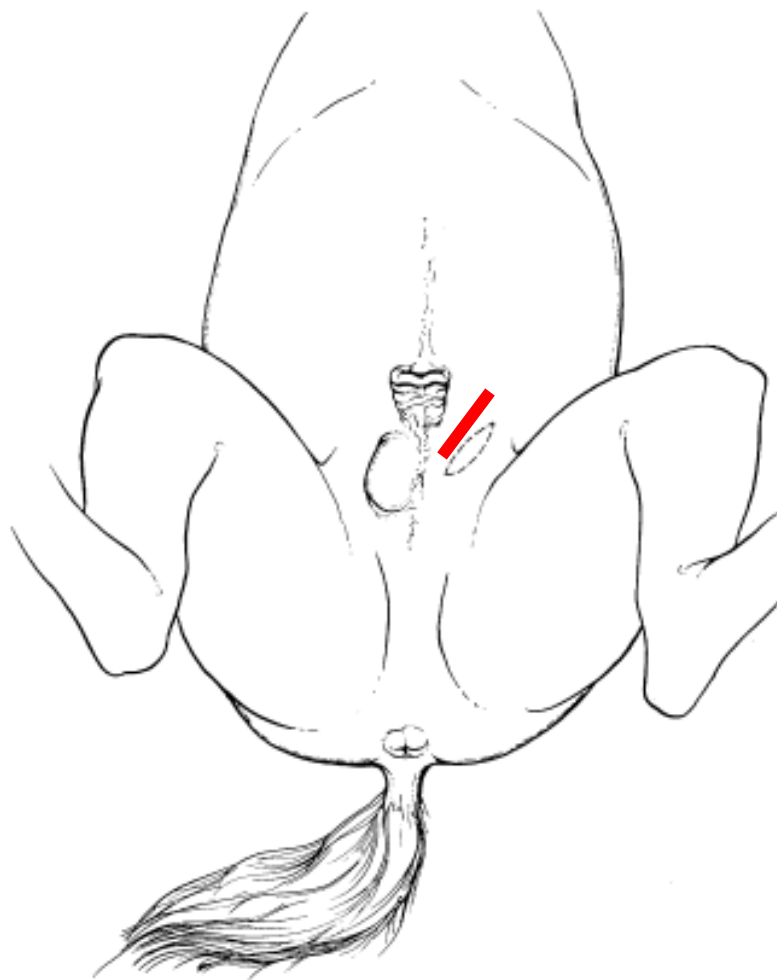


Applying traction on the proper ligament of the testis, the testis can be pulled through the vaginal ring and exteriorized for removal



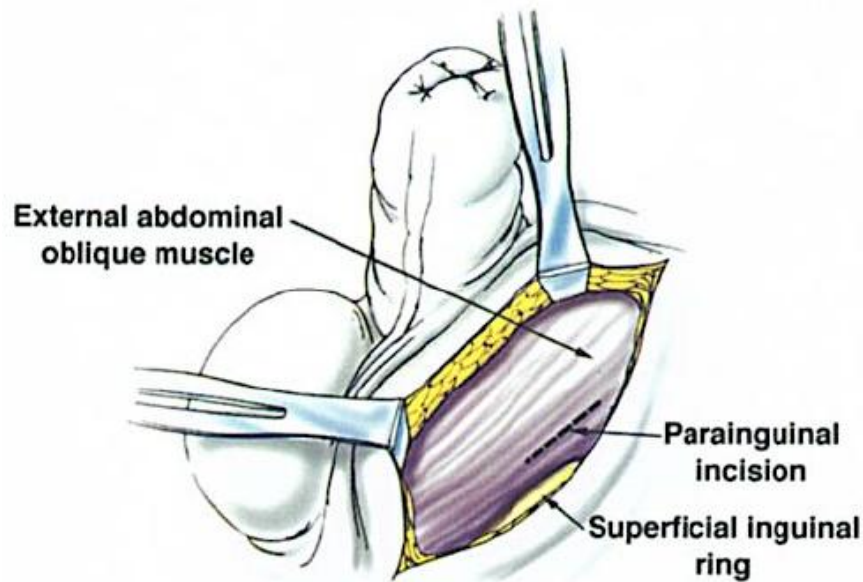
Cryptorchid Castration: Parainguinal Approach

- Is preferred over the inguinal approach by some surgeons because the vaginal ring is not disrupted
- A 4-cm incision is made in the aponeurosis of the external abdominal oblique muscle, 1 to 2 cm medial and parallel to the superficial inguinal ring
- The aponeurosis of the external abdominal oblique muscle is more easily sutured than the superficial inguinal ring

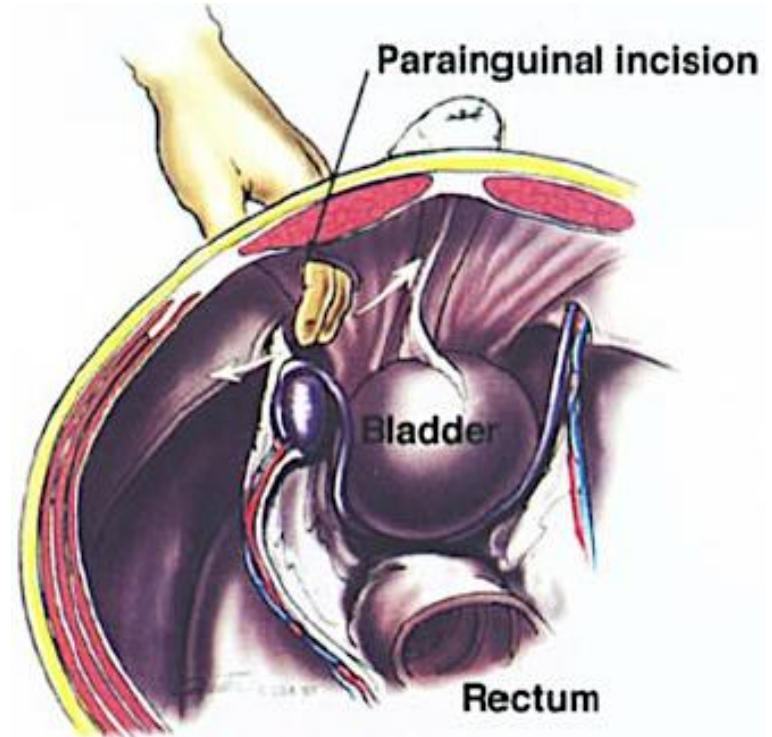





Cryptorchid Castration: Parainguinal Approach



The incision is centered over the cranial aspect of the ring



Internal abdominal oblique muscle underlying the aponeurosis is spread in the direction of its fibers and the peritoneum is penetrated with a sharp thrust of the index and middle fingers



Cryptorchid Castration: Suprapubic Paramedian Approach

- An 8- to 15-cm longitudinal skin incision is made 5 to 10 cm lateral to the ventral midline
- The incision begins at the level of the preputial orifice and extends caudally
- The abdominal tunic and ventral sheath of the rectus abdominis muscle are incised longitudinally, and the underlying fibers of the rectus abdominis muscle are bluntly separated in the same direction
-
- The dorsal rectus sheath, retroperitoneal fat and peritoneum are penetrated with a finger then a hand is introduced into the abdomen

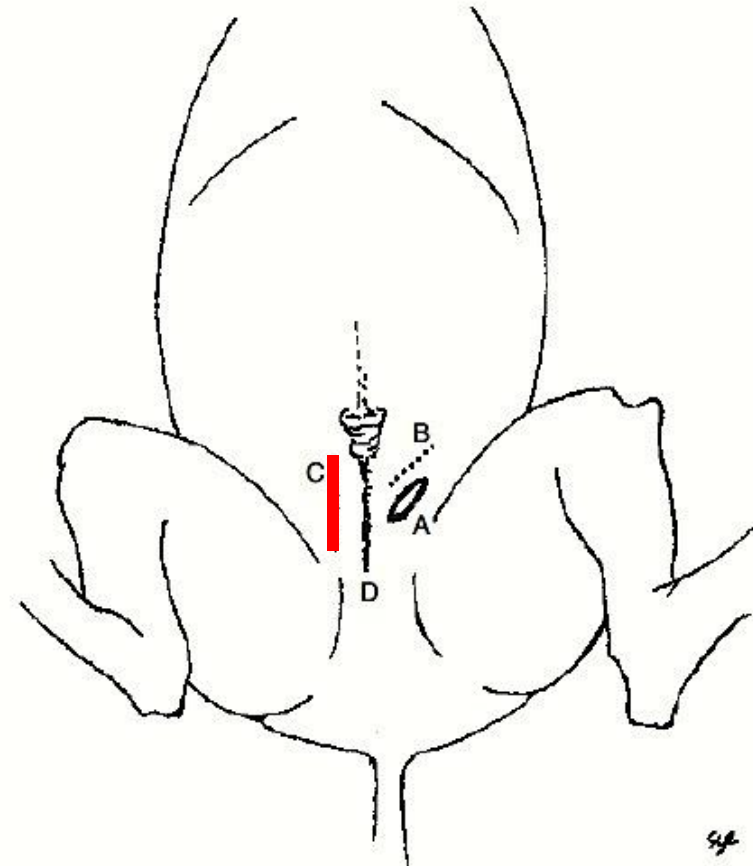

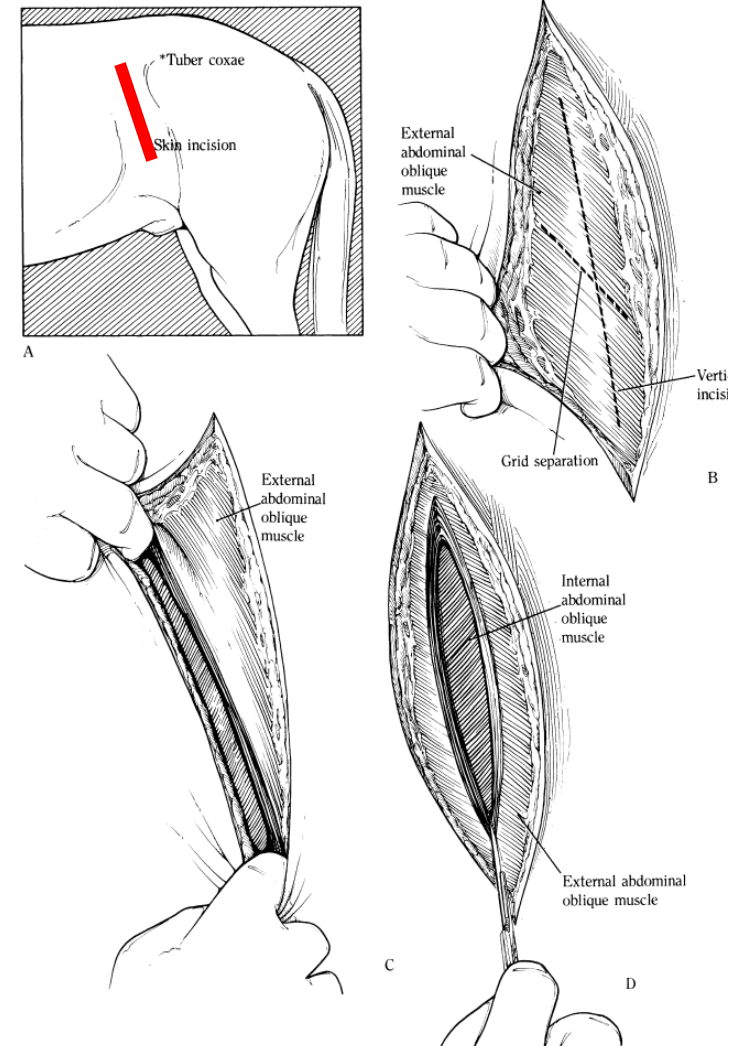


Figure 158.1 Approaches for cryptorchidectomy. (a) Inguinal; (b) parainguinal; (c) paramedian; and (d) scrotal.



Cryptorchid Castration: Flank Approach


- Horse standing or recumbent
- 10- to 15-cm incision is made through the skin and subcutis in the paralumbar fossa of the affected side
- The external abdominal oblique muscle is transected in the direction of the skin incision
- The peritoneum is exposed by splitting the internal abdominal oblique and transversus abdominis muscles in the direction of their fibers
- The peritoneum and retroperitoneal fat are perforated with a finger to enter the abdomen






Laparoscopic Technique of Cryptorchidectomy

- An **abdominal testis** can be removed laparoscopically with the horse
 - in **standing** position
 - in **dorsal recumbency** in **Trendelenburg** position
- **No disruption** of the **internal inguinal/vaginal ring** minimizing risk of **evisceration**
- **Inguinal** retained **testes** should be removed using **traditional** castration **methods** to avoid disruption of the vaginal ring
- **Experienced** and properly **trained surgeon**

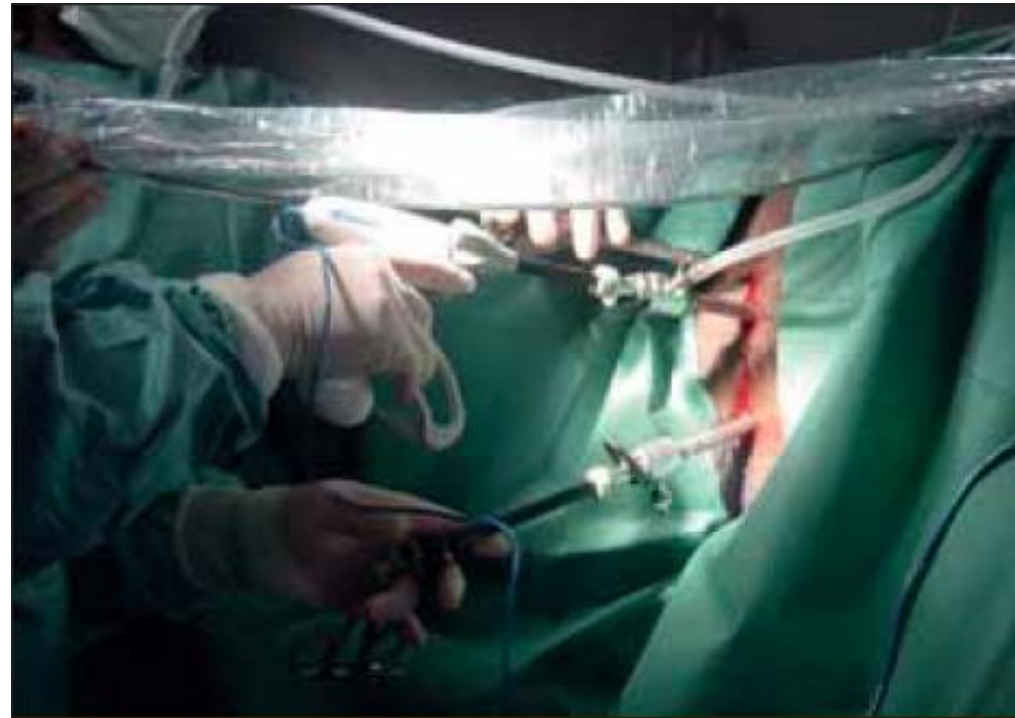
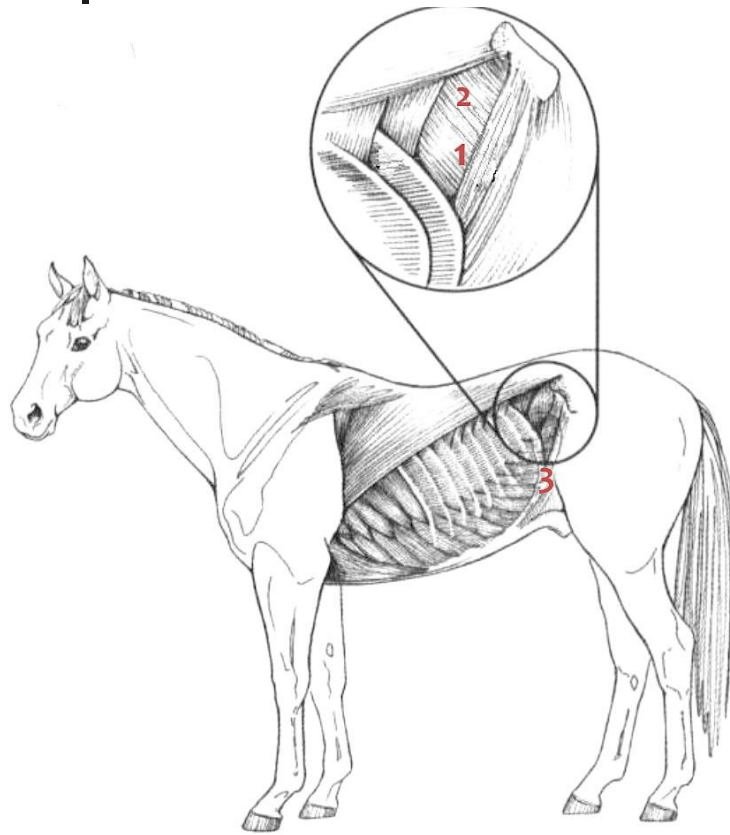


Standing Laparoscopic Cryptorchidectomy


- The placement and number of the portals in the paralumbar fossa can vary
- Generally three portals are necessary (*three portal technique*)
 - One portal is used to insert the **laparoscope**
 - One portal is used to insert **forceps to grasp** the testicle
 - One portal is used to insert an **instrument to sever** the spermatic cord
- **Suture Loop** technique, **Electrosurgical** instrumentation, **Ligasure** Instrumentation
- **Extracorporeal** emasculation (*two portal technique or laparoscopic-assisted*)



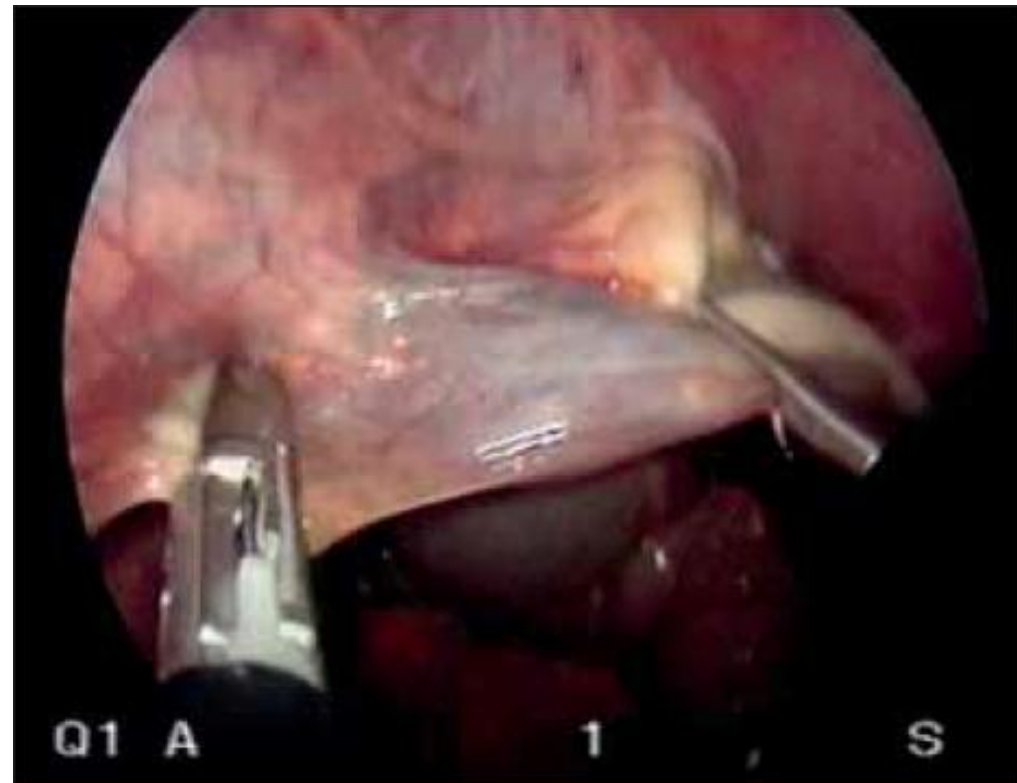
Standing Laparoscopic Cryptorchidectomy




Typical **portal arrangement** for **laparoscopic cryptorchidectomy** in **standing sedated horses**



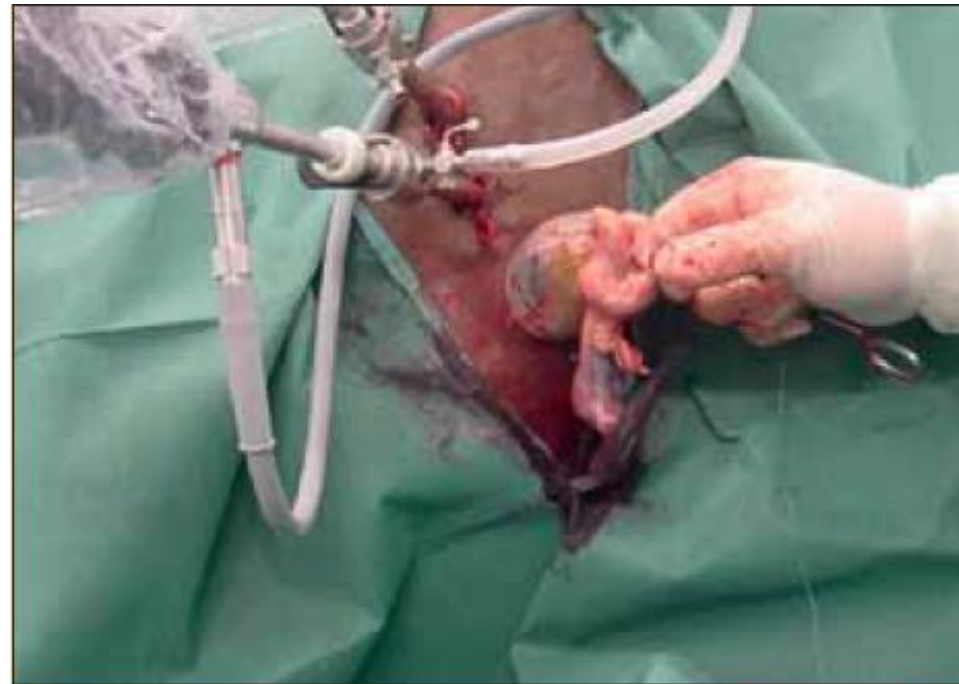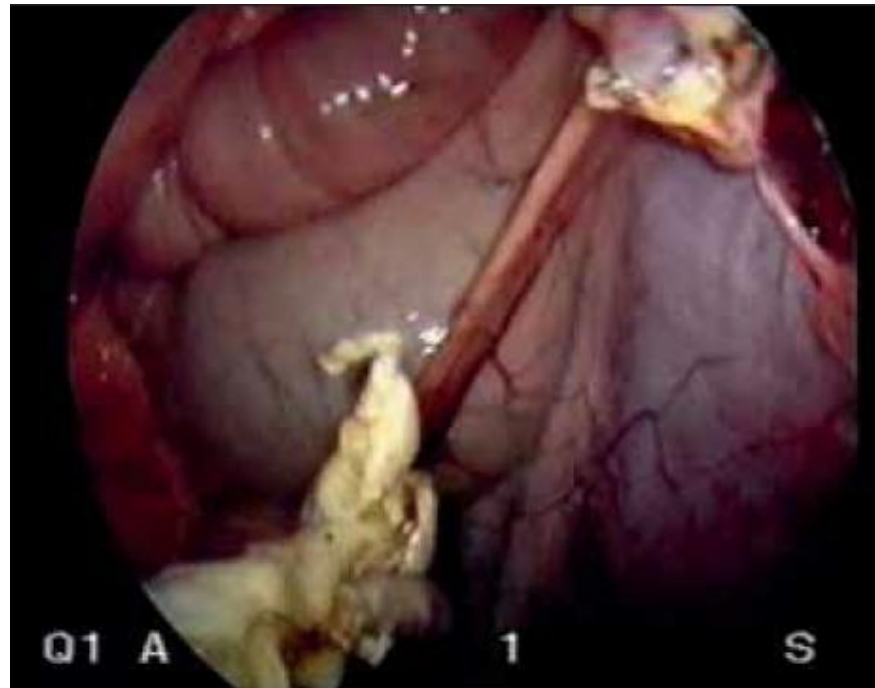
Standing Laparoscopic Cryptorchidectomy




The testicular vessels and ductus deferens of an abdominal testis can be transected intra-abdominally with **vessel-sealing devices** such as the **LigaSure**



Standing Laparoscopic Cryptorchidectomy




Removal of an abdominal testis through a small incision in the paralumbar fossa



Laparoscopic Cryptorchidectomy in the Dorsal Recumbent Horse

- Horse **anesthetized**, the hindquarters must be elevated to **displace the viscera cranial**, making **positive-pressure ventilation** necessary
- Dorsal recumbent approach **works well** for cases involving **bilateral abdominal** retention
- **Hemostasis** of the testis can be performed
 - **Outside** the abdomen (each testis is exteriorized through the corresponding instrument portal)
 - **Inside** the abdomen (only one portal has to be enlarged to remove both testis)



Laparoscopic Cryptorchidectomy in the Dorsal Recumbent Horse

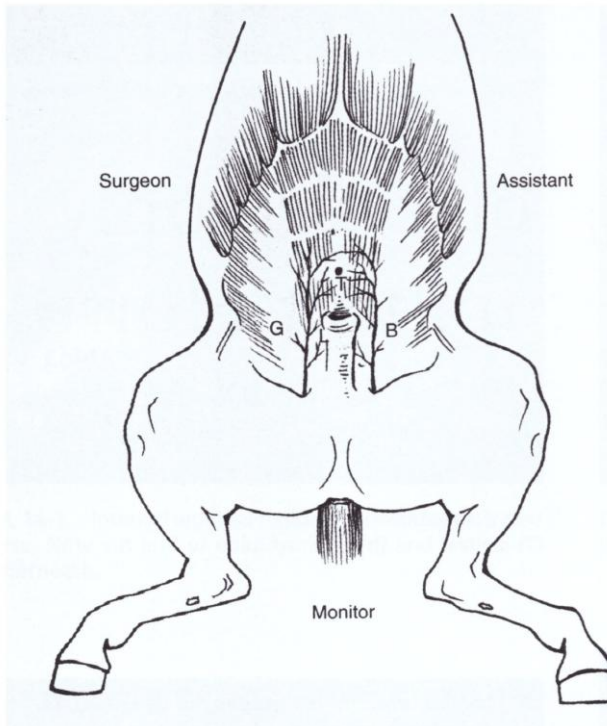
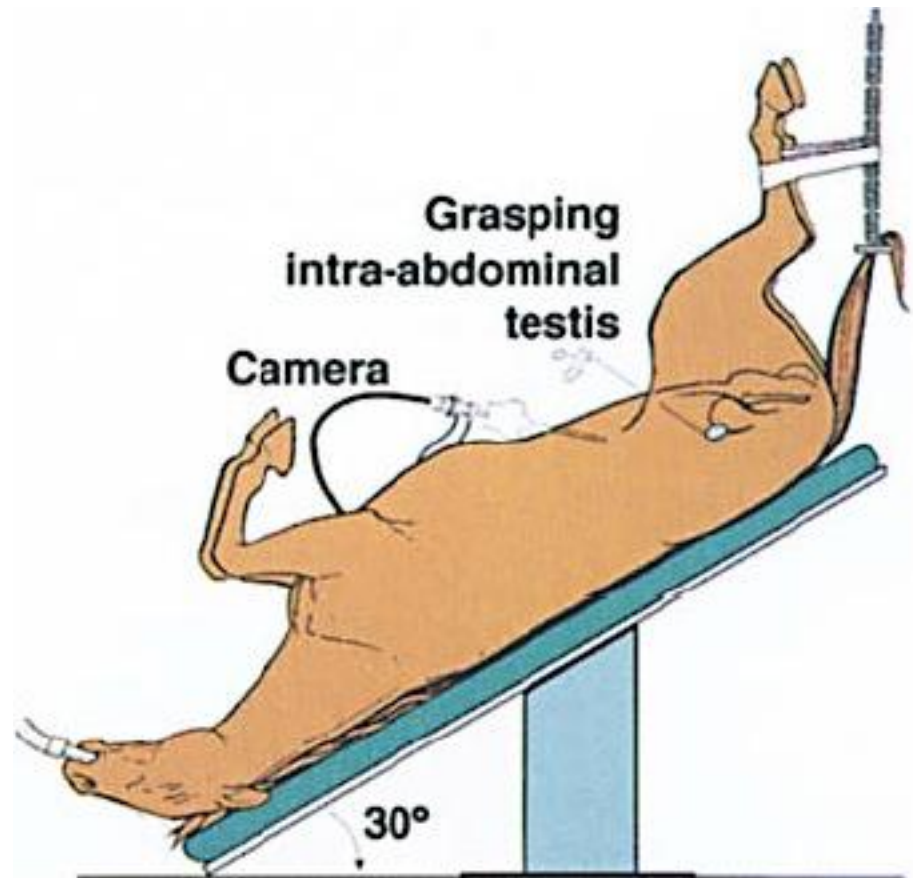

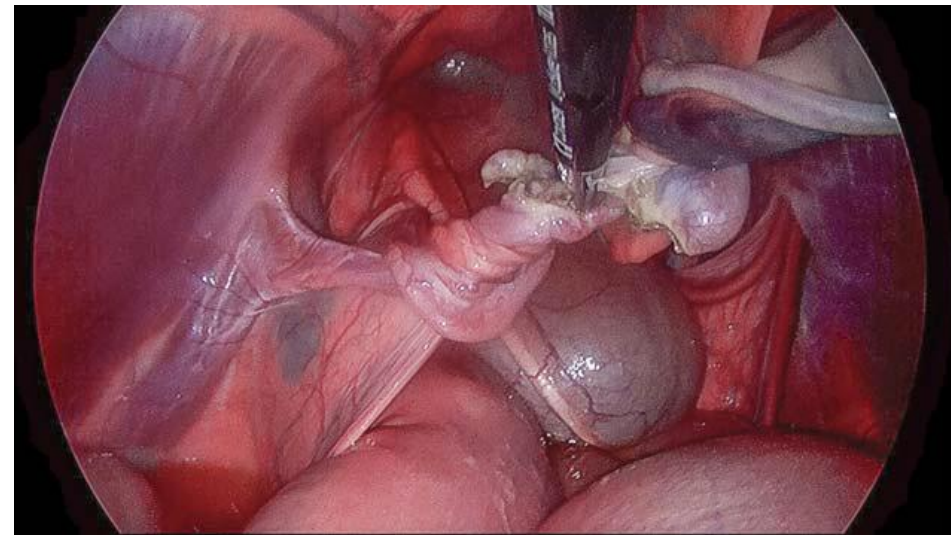
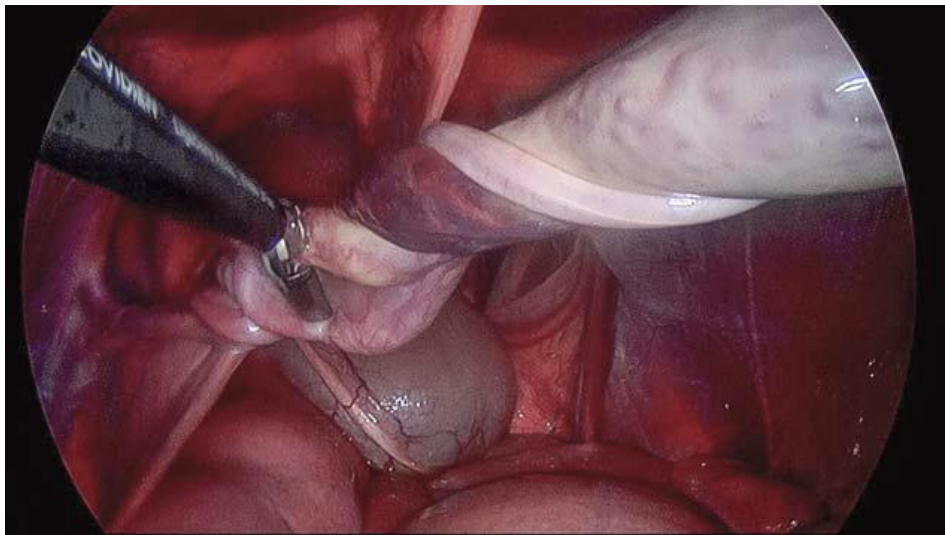


FIG. 14-1 Operating room setup and location of instrument portals. *T*, Laparoscopic telescope; *G*, grasping forceps; *L*, ligating loop; *B*, accessory portal for bilateral cryptorchids.






Laparoscopic Cryptorchidectomy in the Dorsal Recumbent Horse





Intraoperative laparoscopic view of the **vessel sealing device** (LigaSure) applied across the testicular vessels, mesorchium, and vas deferens



OSPEDALE VETERINARIO

UNIVERSITARIO DIDATTICO FACOLTÀ MEDICINA VETERINARIA



**Grazie per
l'attenzione!**

**Servizio di medicina e
chirurgia del cavallo UNITE**