

Anestesi diagnostiche tronculari

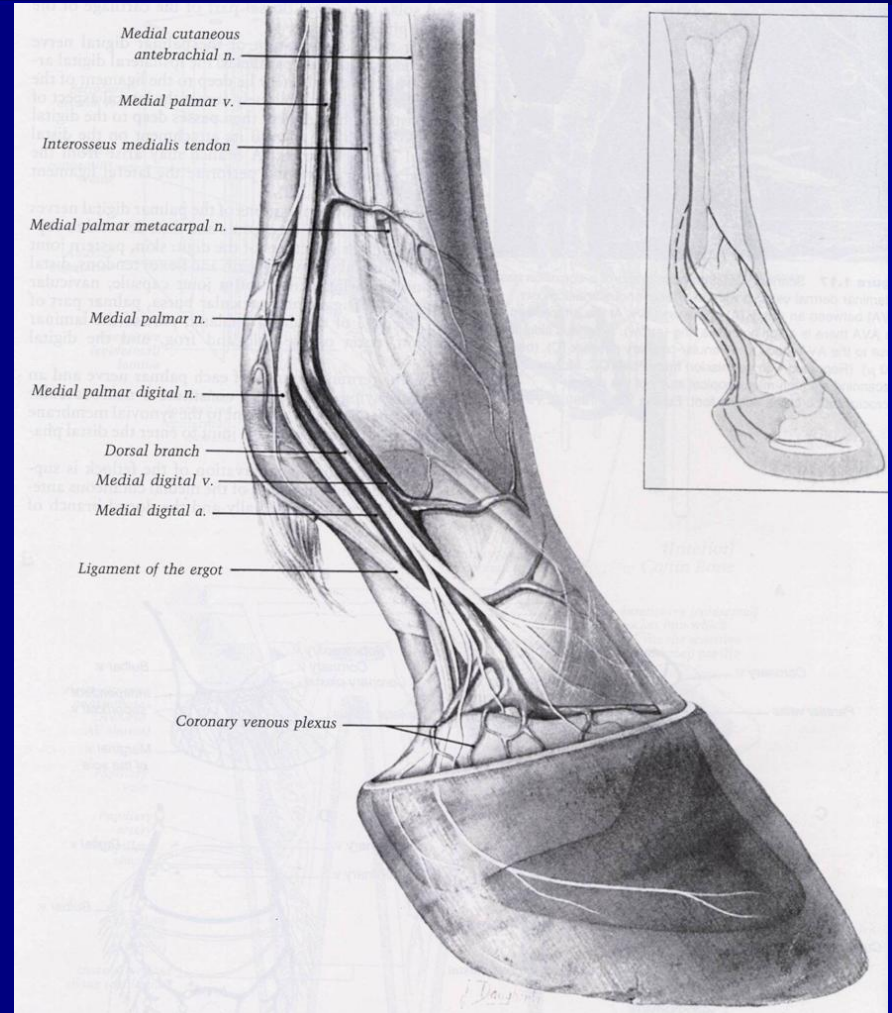
Scuola di Specializzazione in Medicina e
Chirurgia del Cavallo

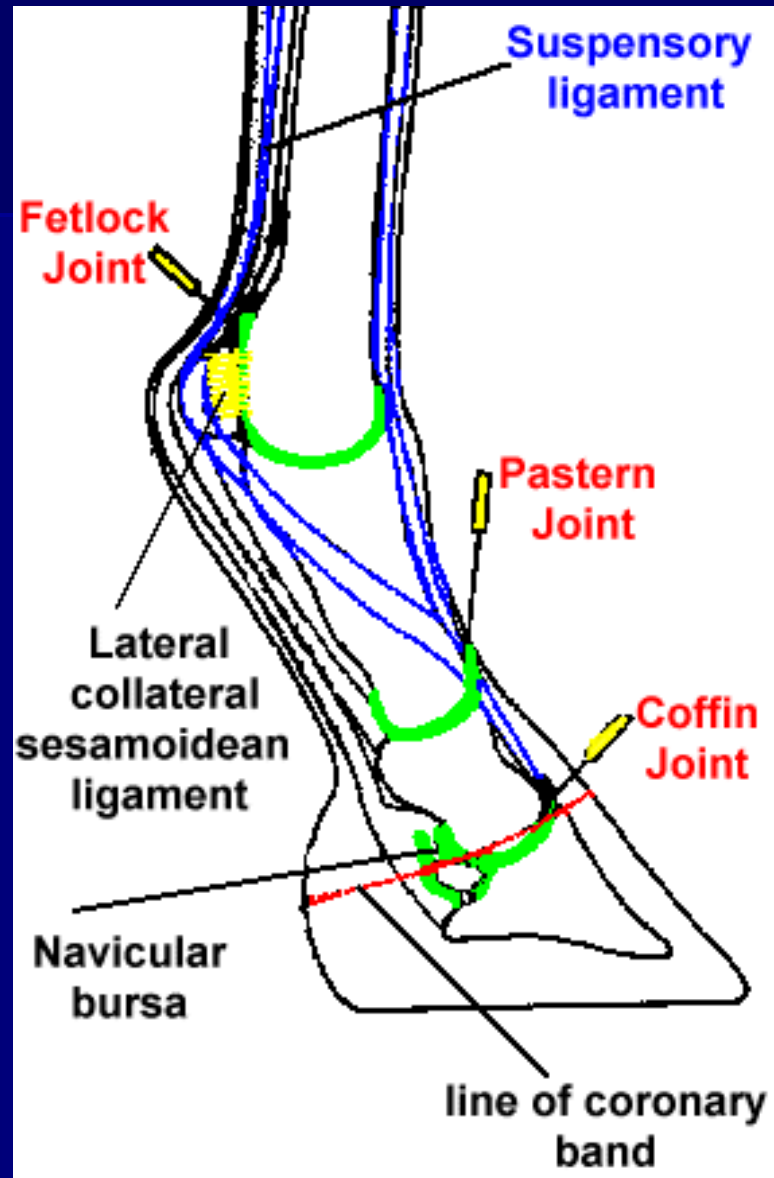
Università degli Studi di Teramo

Corso di Diagnostica Clinica

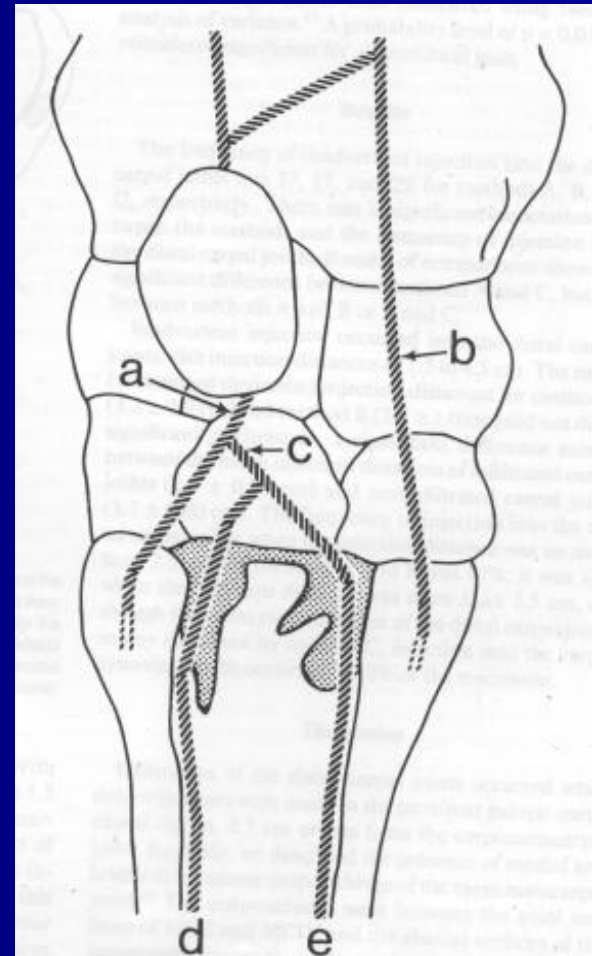
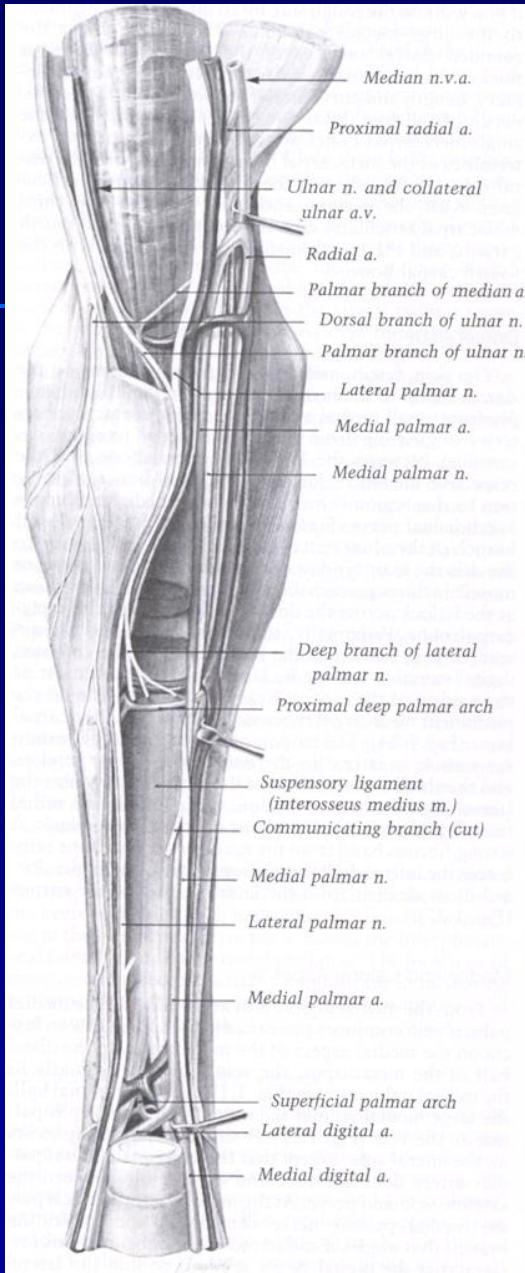
Innervazione del dito

- Nervi palmari laterale e mediale
- Nervi digitali palmari e dorsali

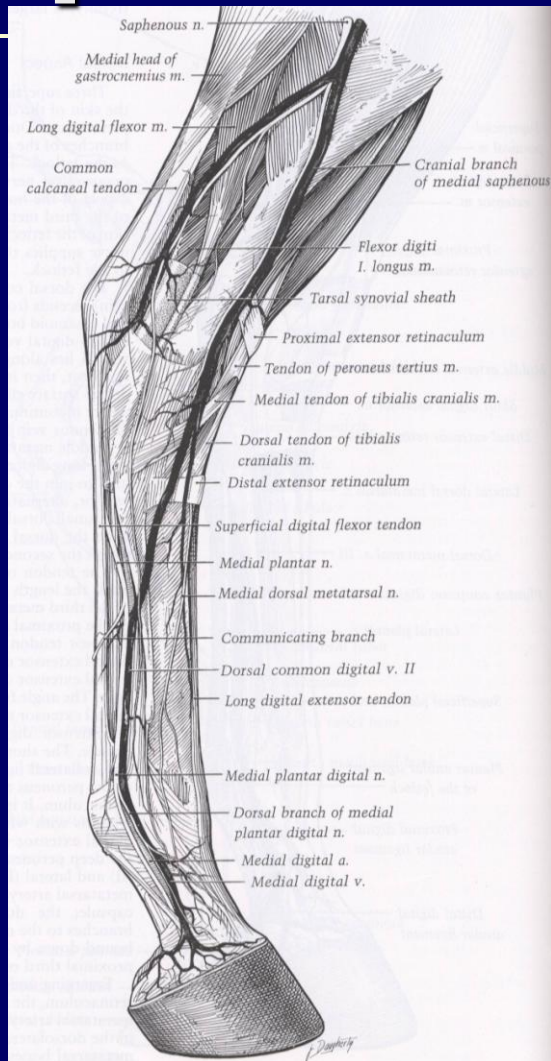




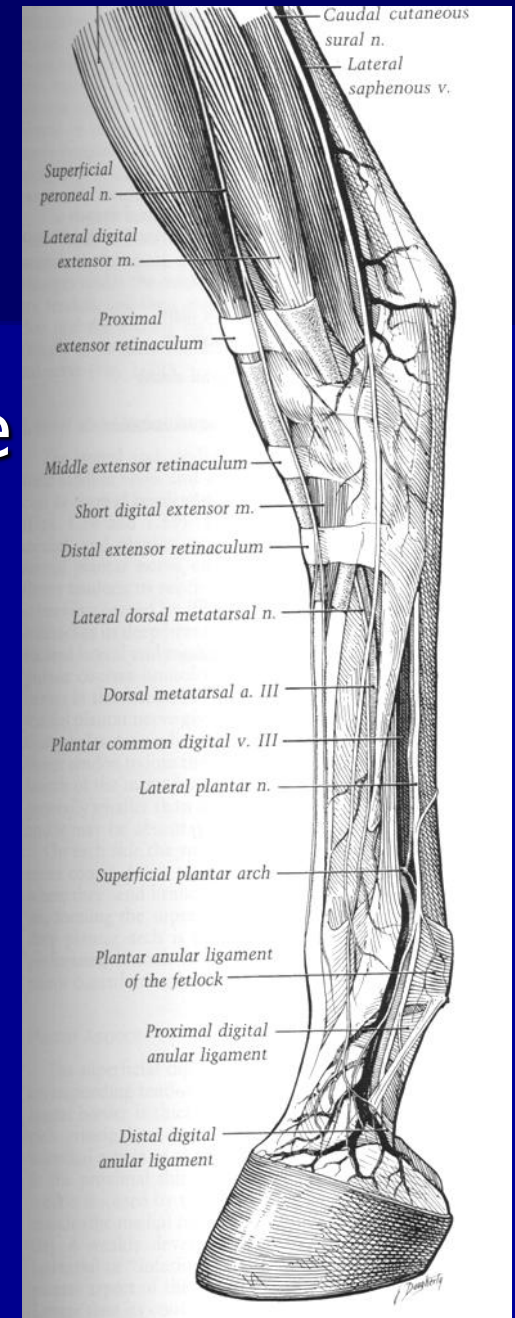
Innervazione dello stinco



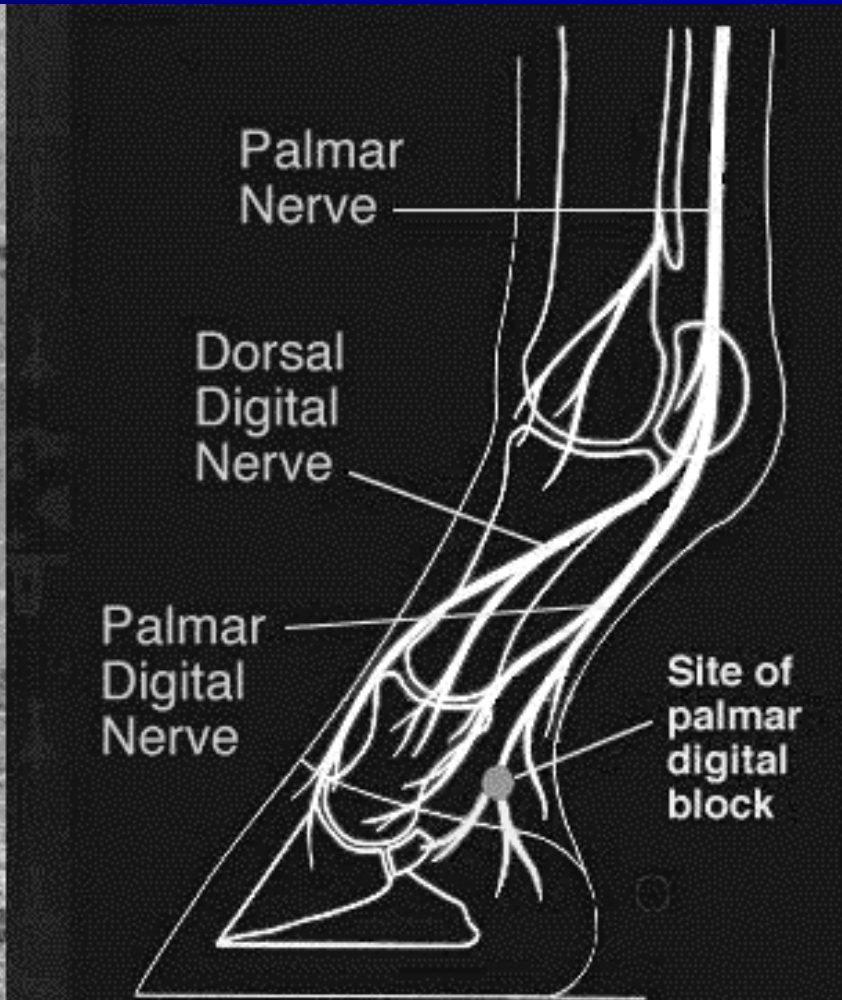
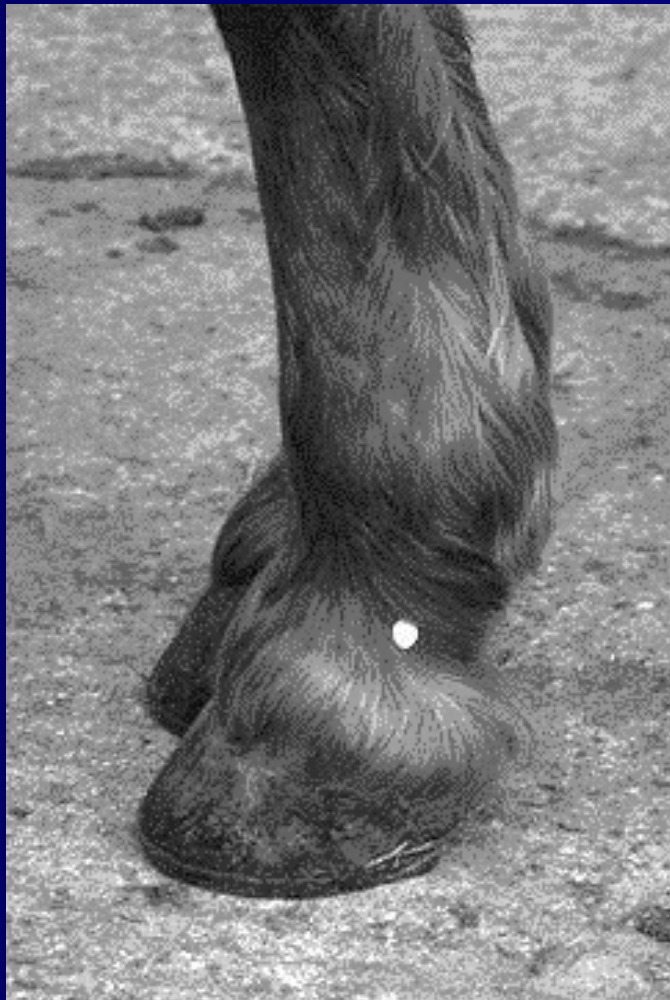Innervazione arto posteriore



- N. metatarsale dorsale mediale
- N. peroneo superficiale
- N. cutaneo caudale della sura



Anestesia digitali palmari

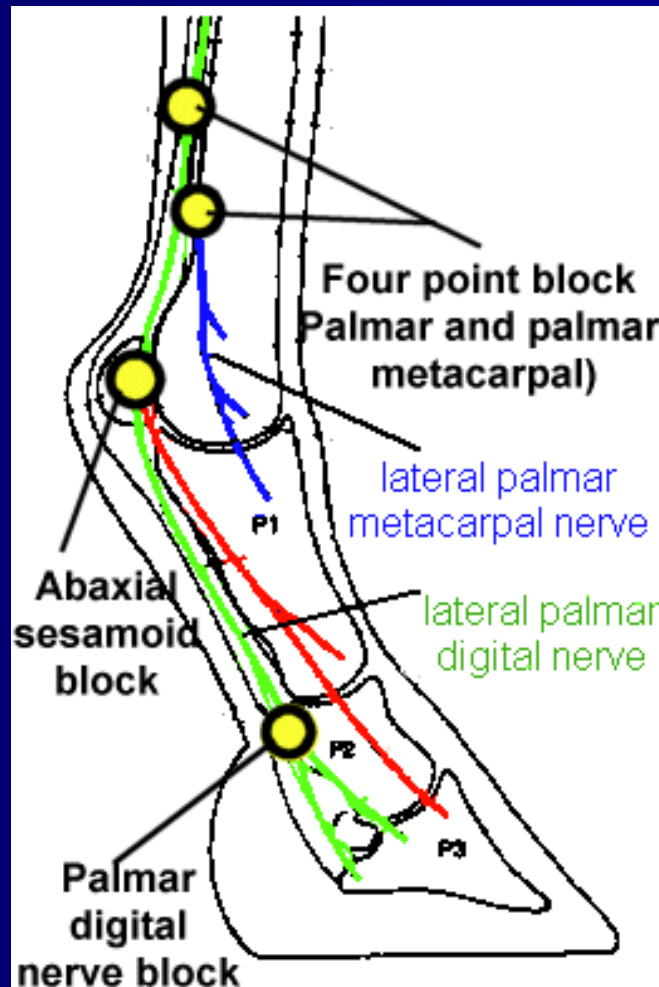


Anestesia del dito



2.

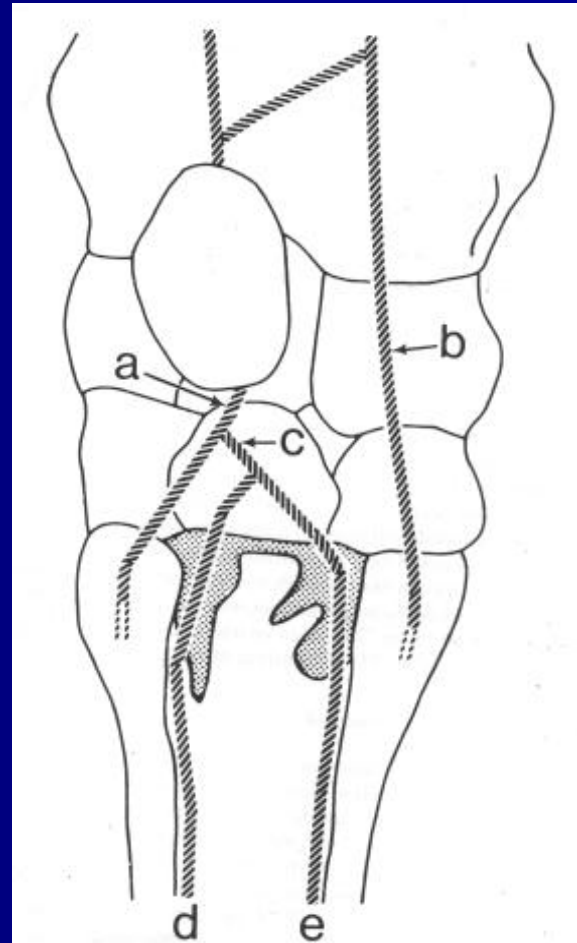
1.



3.

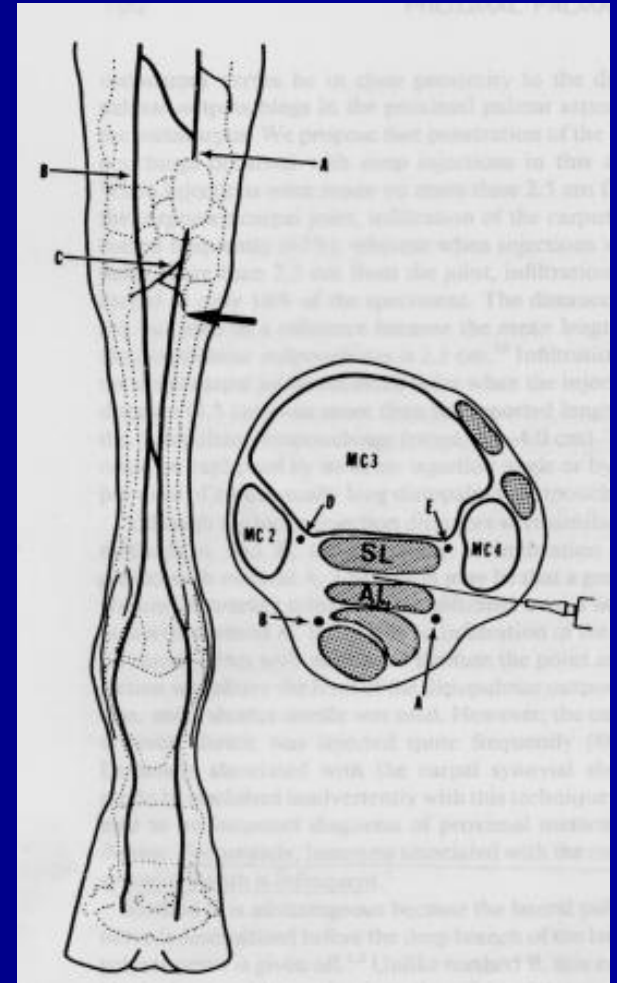
Analgesia metacarpale prossimale palmare

- Penetrazione recessi palmari ventrali art. carpo-metacarpale



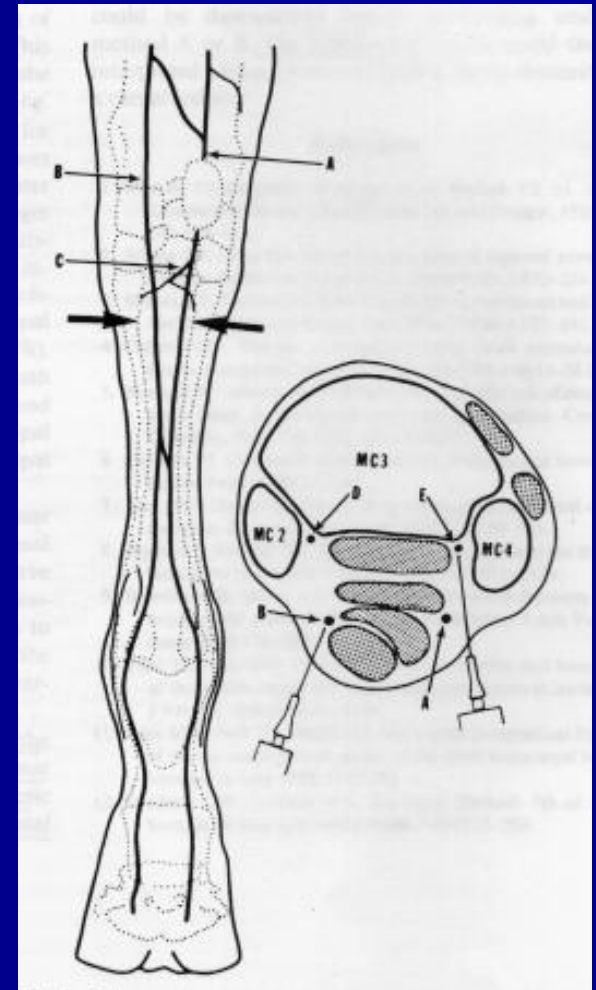
Infiltrazione inserzione prossimale leg. sospensore

- 20 ml di anestetico tra briglia carpica e ins. pross. del legamento sospensore



High four points block

- 2.5 ml, assialmente a MC VI e II
- 2.5 ml tra tendini flessori e sospendore, med. e lat.



Blocco a livello del pisiforme

- Solo il nervo palmare laterale
- Subito al di sotto del pisiforme
- Ago 1.5 cm da 25 G (5 ml)

