

Understanding Feline Heartworm Infection: Disease, Diagnosis, and Treatment

Alice C. Y. Lee, DVM,* and Clarke E. Atkins, DVM, Dipl. ACVIM (Internal Medicine & Cardiology)[†]

Feline heartworm disease is a very different clinical entity from canine heartworm disease. In cats, the arrival and death of immature heartworms in the pulmonary arteries can cause coughing and dyspnea as early as 3 months postinfection. Adult heartworms suppress the function of pulmonary intravascular macrophages and thus reduce clinical disease in chronic feline heartworm infection. Approximately 80% of asymptomatic cats self-cure. Median survival time for symptomatic cats is 1.5 years, or 4 years if only cats living beyond the day of presentation are considered. Aberrant worm migration is more frequent than it is in dogs, and sudden death can occur with no prior clinical signs. The bacterial endosymbiont *Wolbachia* likely contributes to the inflammatory pathology of heartworm disease, but its role is not yet fully clear. Unfortunately, the diagnosis, treatment, and management of feline heartworm disease are far from simple. Antemortem diagnosis is hampered by low worm burdens, the frequency of all-male infections, and nonspecific radiographic lesions. It is up to the veterinarian to determine the correct index of suspicion and choose the right combination of diagnostic tests to achieve an answer. Treatment is symptomatic because adulticide therapy is risky and does not increase survival time. Despite the dangers of feline heartworm disease, less than 5% of cats in the United States are on chemoprophylaxis. It is important for veterinarians to take a proactive preventive stance because heartworm infection in cats is a multisystemic disease that has no easy cure. © 2010 Elsevier Inc. All rights reserved.

Keywords: *Dirofilaria immitis*, feline, heartworm-associated respiratory disease (HARD), *Wolbachia*, diagnosis, treatment

Heartworms (*Dirofilaria immitis*) have long been acknowledged as a cause of severe and potentially fatal cardiopulmonary disease in dogs, and thus much effort has been put into the study of this parasite in its natural definitive host. However, several noncanid species can also act as atypical hosts for adult *D. immitis* worms, including another very popular companion animal, the domestic cat. It is only recently that the scientific community has focused attention on feline heartworm disease and recognized the differences in host response, pathophysiology, and clinical presentation of heartworm infection in cats versus that in dogs. In particular, a new disease manifestation in cats has been elucidated that occurs independent of worm maturation to the adult stage in the pulmonary vasculature: heartworm-associated respiratory disease (HARD).¹ Moreover, the role of *Wolbachia* endosymbionts in heartworm infection is slowly coming to light, and the parasite life expectancy, host mortality, and

self-cure rate in cats are now better understood. In this review, the authors will describe recent advances in our understanding of feline heartworm infection and will provide recommendations for the diagnosis and prevention of this important parasitic infection.

Epidemiology and Life Cycle

Dirofilaria immitis is endemic in many countries. Heartworm prevalence in dogs has been extensively reported worldwide with values as high as 80% in some regions, though this number varies greatly depending on geographical location.² The prevalence of feline heartworm infection, less well defined because definitive antemortem diagnosis is difficult to achieve, is generally estimated to be 5% to 20% that of the canine population in the same area.³ Reasons for the lower prevalence in cats may include poor suitability as a definitive host,⁴⁻⁷ as well as mosquito feeding preferences: *D. immitis* vectors such as *Aedes taeniorhynchus* and *Culex quinquefasciatus* are found in greater frequency on dogs versus cats when both hosts are present together.⁸ Necropsy studies conducted a few years ago in northern Georgia and Florida revealed adult heartworms in 2.1% and 4.9% of shelter cats, respectively.^{7,9} In a population of client-owned cats in Italy that were not receiving chemoprophylaxis, 6.7% were confirmed to be heartworm infected via antigen testing and echocardiography, and 18.6% were antibody positive.¹⁰ An outdoor lifestyle increases a cat's exposure to mosquito vectors

From the *Department of Microbiology & Immunology, C4183 Veterinary Medical Center, College of Veterinary Medicine, Cornell University, Ithaca, NY, USA.

[†]Department of Clinical Sciences, College of Veterinary Medicine, North Carolina State University, Raleigh, NC, USA.

Address reprint requests to: Alice C. Y. Lee, DVM, Department of Microbiology & Immunology, C4183 Veterinary Medical Center, College of Veterinary Medicine, Cornell University, Ithaca, NY 14853. E-mail: cl568@cornell.edu.

© 2010 Elsevier Inc. All rights reserved.

1527-3369/06/0604-0171\\$.00/0

doi:10.1053/j.tcam.2010.09.003

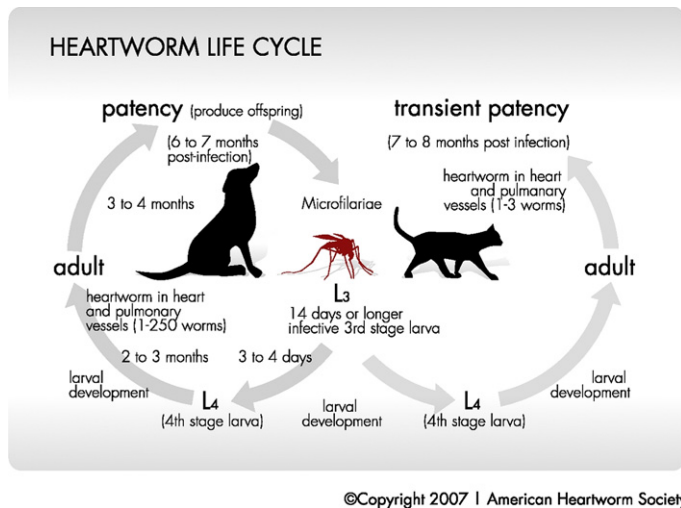


Fig. 1. Life cycle of *Dirofilaria immitis* in cats versus dogs. Reprinted with permission from the American Heartworm Society (www.heartwormsociety.org/pet-owner-resources/heartworm.html).

and is a risk factor for infection; however, living strictly indoors does not fully protect against infection. In various studies, between 19% and 27% of confirmed heartworm-infected cats were indoor only.^{10,11}

The life cycle of *Dirofilaria immitis* in cats is similar to that in dogs (Fig 1). A female mosquito ingests microfilariae when it feeds on an infected dog (or other canid). The microfilariae develop into first-stage larvae and then subsequently into infective third-stage (L3) larvae after undergoing 2 molts within the mosquito; this process can take between 8 and 30 days, depending on ambient temperature.¹² When the mosquito then feeds on a cat, the infective L3 deposited on the skin enter the bite wound. The molt to the L4 stage occurs in the subcutaneous tissue and muscle within 3 days.¹³ Based on our understanding of heartworm development in the dog, we believe that after about 2 months migrating through muscle and adipose tissue, the L4 undergo a final molt to become immature adults. The immature worms enter a peripheral vein and are carried by the circulation to the caudal pulmonary arteries 70 to 90 days postinfection, where the majority are cleared, but a few may continue development into adults.^{1,14} Microfilaremia occurs in <20% of cats with mature heartworm infections and begins 7 to 8 months after infection; patency persists for only 1 to 2 months.^{6,13} Most commonly there are 2 to 4 adult heartworms (range, 1-8) per cat and—unlike the case in dogs, in which *D. immitis* can live for up to 7.5 years—they survive for just 2 to 4 years, which is longer than previously believed.^{10,15} This marked reduction in worm fertility and viability is believed to result from an innate resistance to *D. immitis* on the part of the feline host.^{4,6,7} Aberrant migration occurs with greater frequency in cats than in dogs.⁶ Ectopic locations include body cavities and the central nervous system.¹⁶

Pathophysiology and Clinical Manifestations

In cats, most of the immature worms that reach the caudal pulmonary arteries die, inducing a strong vascular and parenchymal inflammatory response.^{1,14} This pronounced reaction is hypothesized to be due to the activity of pulmonary intravascular macrophages (PIM), a component of the reticuloendothelial system that cats possess but normal dogs do not.^{14,17} Accordingly, cats may exhibit coughing or dyspnea or intermittent vomiting around 3 months postinfection, something not known to be associated with canine heartworm disease.¹⁴ This unique manifestation of feline heartworm infection is known as HARD.¹ Regardless of whether adult worms ultimately develop, heartworm-exposed cats have the potential to develop significant lung damage.¹ Histological examination of shelter cats undergoing necropsy showed that antibody-positive cats with no adult heartworms (presumptive HARD patients) demonstrated a frequency of pulmonary arterial occlusive hypertrophy that was intermediate in severity between cats that harbored adult heartworms and cats that had no evidence of heartworm exposure (i.e., antibody-negative and no adult heartworms).¹⁸

Cats in which a mature infection develops may be asymptomatic in many cases. Mature adult heartworms are believed to secrete a product that downregulates PIM activity, such that the resulting antiinflammatory effect minimizes clinical signs in infected cats.¹⁷ Signs most often exhibited in chronic feline heartworm disease are respiratory in nature (dyspnea, coughing), but vomiting, neurological signs (ataxia, circling, head tilt, blindness, seizures), and sudden death are also observed.^{11,13,15} Acute respiratory distress and sudden death are generally attributed to the death, deterioration, and embolization of worms or worm fragments, causing pulmonary arterial infarction and circulatory collapse.^{4,13} Rarely, right-sided heart failure and caval syndrome have been documented in cats.^{13,19,20} Adult heartworms induce pathology in the pulmonary arteries characterized by villous endarteritis, intimal fibrosis, medial hypertrophy, and thrombosis.^{4,18} A side-by-side comparison of HARD and chronic feline heartworm disease is presented in Table 1.

Like many filarial worms, *Dirofilaria immitis* has a symbiotic relationship with an intracellular bacterium of the genus *Wolbachia*.^{21,22} These bacteria are harbored by all stages of heartworm and are shed in high numbers during microfilarial production and when larvae or adult worms die.²² Immunoglobulin G antibodies against *Wolbachia* surface proteins (WSP) increase and remain high for months in cats after experimental heartworm infection.²³ Cats treated with ivermectin 30 days postinfection have even higher titers than untreated control cats, suggesting that the large quantity of bacteria released on larval death generates a strong host immune response.²³ This long-lasting humoral response against WSP may allow a previously exposed feline host to more effectively eliminate heartworm larvae on repeat exposure, thus providing another possible explanation for the cat's natural resistance to heartworm infection.²³ WSP, in and of itself, has been shown to stimulate expression of proinflamma-

Table 1. Comparison of Immature Heartworm-associated Respiratory Disease (HARD) and Chronic Heartworm Disease in Cats

	HARD	Chronic heartworm disease
Onset of clinical signs after infection	3 months	7 months
Etiology	Arrival and death of immature heartworms in pulmonary arteries	Pulmonary vascular, parenchymal, and cardiac response to the presence, death, and deterioration of adult heartworms
Clinical signs	Dyspnea, coughing, wheezing	Dyspnea, coughing, hemoptysis, collapse, vomiting, neurological signs, heart failure, sudden death
Serological test results		
Antigen	Negative	Positive or negative
Antibody	Often positive	Often positive
Microfilaremia	Absent	Occasionally present
Radiographic findings	Bronchointerstitial pattern	Variably bronchointerstitial pattern, pulmonary artery enlargement, and pulmonary hyperinflation; less commonly pleural effusion or pulmonary consolidation
Echocardiographic findings	Normal (no heartworms discernible)	Heartworm(s) often found in pulmonary artery, right atrium, or right ventricle; possible pulmonary hypertension

tory mediators, leading to the theory that *Wolbachia* contributes directly to the pathology of heartworm disease.²¹ This is further supported by the finding that dogs receiving ivermectin (at 4× the preventive dosage) and doxycycline (to suppress *Wolbachia* populations) before undergoing adulticide therapy had significantly milder lung lesions on histological examination compared with dogs receiving adulticide alone.²⁴ However, a recent study investigating the link between relative *Wolbachia* load and severity of lung pathology in heartworm-infected cats and dogs did not demonstrate a clear correlation.²² At this time, the importance of this endosymbiont in causing pulmonary lesions is uncertain.

Diagnosis of Feline Heartworm Infection and Disease

Because of low worm burdens and low circulating antigen levels, the diagnostic approach to feline heartworm infection should incorporate a combination of testing methods.¹⁶ Serological tests are typically the initial screening tool. They can provide very useful information, but the limitations of these methods must be understood to correctly interpret test results. A positive antibody test denotes heartworm exposure (and development of larvae to at least the L4 stage) and serves as an alert that the cat may have a mature infection, may have or may later develop HARD, and is at risk for future infection; however, it does not confirm the presence of adult worms. A negative result likewise does not rule out infection,²⁵ though it reduces the odds substantially because the majority of cats with adult infections are antibody positive. Commercially available antigen tests, up to this point, have targeted an antigen produced mainly in the reproductive tract

of adult females. Recently, a new antigen detection kit was launched that claimed 100% sensitivity when samples from dogs with male-only or male-plus-juvenile-worm infections were tested (Rapide *Dirofilaria* Ag Test Kit; Modern Veterinary Therapeutics, LLC, Miami, Florida, USA). It remains to be seen how this will alter our ability to diagnose heartworm infection in cats. Tests that detect the female reproductive antigen are prone to false-negative results in cats because of low worm burdens and the possibility of male single-sex infections.²⁵ They also do not detect immature infections (those acquired <7-8 months before testing took place). A positive result does point strongly to the presence of heartworms, but one must keep in mind that predictive values change with the true prevalence of disease, meaning that a positive antigen result in a low-prevalence area has a greater risk of being false positive. Another downside to serological testing is the fact that antibodies and antigen remain in circulation for an indeterminate length of time after the cat has cleared the parasite, making it difficult to discriminate between past and active infection.⁷ Therefore, serological testing helps to raise or lower the index of suspicion for feline heartworm disease, but rarely provides a definitive diagnosis. That being said, a positive antigen test in a symptomatic cat or in an endemic area is considered to be diagnostic. Running both an antibody and antigen test improves sensitivity compared with running either test alone.^{16,25}

For cats, performing a modified Knott test for microfilariae is rarely fruitful because patency is short lived; however, when present, microfilaremia provides a definitive diagnosis.

Thoracic radiography provides another piece of the puzzle, but again, findings are nonspecific and variably include: a bronchointerstitial lung pattern (or less commonly a pure

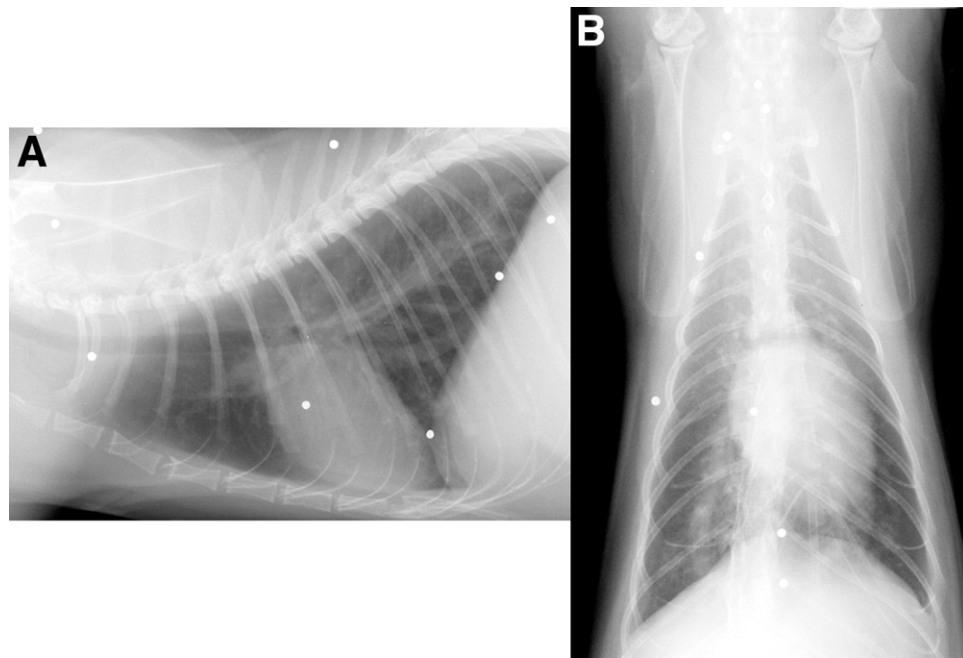


Fig. 2. Thoracic radiographs from a cat with heartworm disease and cough. (A) Lateral view. Note the hyperinflated chest, flat diaphragm, and moderate interstitial pulmonary infiltrate. The right ventricle is mildly enlarged. (B) Dorsoventral view. The pulmonary infiltrate is more readily appreciated in this view in the right caudal lung lobe. Note the enlarged right caudal lobar pulmonary artery (>1.6 times the ninth rib at the ninth intercostal space). Reprinted with permission.³³

bronchial, interstitial, or alveolar pattern), pulmonary artery enlargement (defined as a caudal pulmonary artery wider in diameter than 1.6 times the ninth rib at the ninth intercostal space), pulmonary hyperinflation, and sometimes right ventricular enlargement (Fig 2).^{4,5,11,16,26,27} These changes may be mistaken for other lung diseases such as allergic bronchitis, asthma, or aelurostrongylosis.^{1,15,28} Because the index of suspicion for feline heartworm disease has historically been low, it is likely that many cases of feline heartworm have been misdiagnosed in the past (Fig 3). Occasionally, pleural effusion due to hydrothorax or chylothorax may be observed on thoracic radiographs, and evidence of thromboembolism may also be present.^{5,13,15} In some patients, no radiographic abnormalities are detected.^{11,27}

Echocardiography is a useful adjunctive test in patients with clinical suspicion of heartworm disease and, in almost all cases, is the only definitive way to diagnose infection antemortem. Heartworms appear as a double-lined hyperechoic structure in the pulmonary arteries or chambers of the heart (Fig 4). The sensitivity of this method is much higher in cats as compared with dogs because the smaller size of the feline pulmonary arterial tree makes heartworms easier to find.¹³ However, operator experience and skill play a significant role in the accuracy of this examination. Sensitivity of echocardiography has ranged from 40% in one study to almost 100% in another.²⁶ Overall, to rule in or rule out feline heartworm infection with any degree of certainty, a combination of tests must be used, with full understanding of the limitations of each one.

Treatment Options for Cats with Adult Heartworms

Treatment options are limited in cats compared with dogs. Adulticidal therapy may be standard for dogs, but it is not recommended in cats because of the high mortality rate from

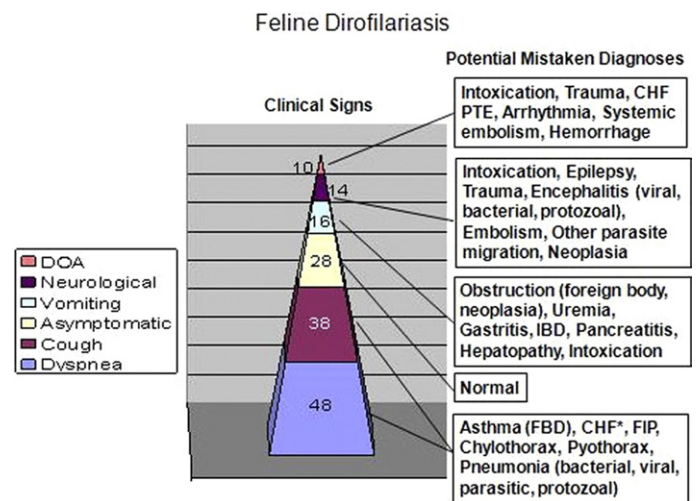


Fig. 3. Clinical signs and differential diagnoses for feline heartworm disease, including HARD, reported for 50 proven cases of heartworm infection in cats. Number of cats exhibiting each clinical sign is shown. Differential diagnoses were generated based on data presented by Atkins and coworkers.¹¹

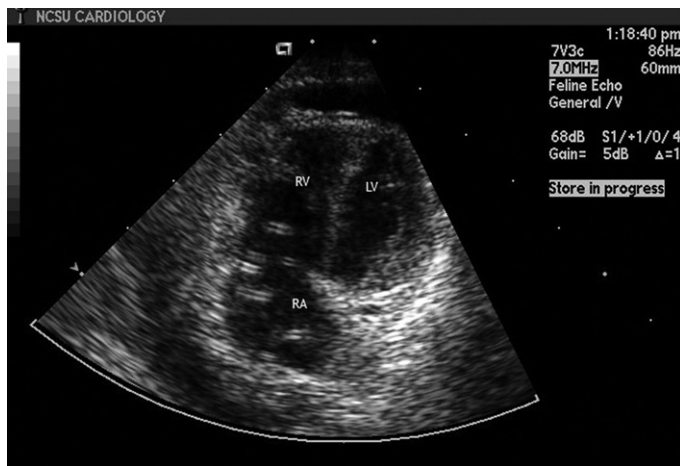

Fig. 4. Two-dimensional echocardiogram showing 2 adult female heartworms, seen as double-lined echodensities, in the right atrium and right ventricle of a naturally infected cat. RA = right atrium, RV = right ventricle, LV = left ventricle.

pulmonary thromboembolism and possible anaphylactic-like reaction to dead and dying worms.¹⁶ Because many cats self-cure, symptomatic treatment is considered a preferable alternative. Cats with clinical or radiographic signs of pulmonary disease can be given antiinflammatory doses of prednisone (1-2 mg/kg, every 12-48 hours as needed, tapered down over 3-4 weeks). For patients whose signs persist or recur, alternate-day prednisone at the lowest effective dose can be given indefinitely.¹³ All infected cats should receive heartworm preventive to avoid repeat infection. Because cats are only transiently microfilaremic, there is no need to worry about causing mass microfilarial death with chemoprophylactic administration. Also, as part of the safety testing performed during the Food and Drug Administration approval process, commercially available heartworm preventives have been shown to be safe when used in infected cats.¹³

There is some debate as to whether doxycycline should be administered to heartworm-infected animals to target the *Wolbachia* endosymbiont. Although a decrease in pulmonary inflammation was observed in one study in which dogs were given doxycycline and ivermectin before adulticide therapy,²⁴ the benefits for cats—in which adulticide treatment is not advised—have yet to be evaluated. Consequently, doxycycline is not recommended as an adjunctive therapy in cats at this time.

Successful surgical extraction of heartworms has been reported in cats. In theory, this is a safer treatment option than chemotherapy, which may cause thromboembolism. Unfortunately, it carries its own set of risks, namely vascular trauma with hemorrhage, and intraoperative worm breakage resulting in potentially fatal anaphylactic-like shock.^{13,16} Several extraction methods have been described: jugular venotomy with use of alligator forceps, endoscopic forceps, basket snares or loop snares to retrieve worms; main pulmonary arteriotomy; right auriculotomy; and right atriotomy with total venous inflow occlusion (Fig 5).^{16,19,20} Cats that sur-



Fig. 5. Surgical heartworm extraction (from the same cat shown in Fig 4) using a nitinol loop snare. The operator has ensnared 2 adult female heartworms from a cat with heart failure manifested by chylothorax. This procedure was performed under fluoroscopic guidance and proved curative for this cat. Reprinted with permission.²⁰

vived surgery showed marked clinical improvement. Nevertheless, because of the risk and impracticality, surgical extraction is generally limited to emergency situations such as caval syndrome, or to specialized referral centers.

Prognosis

The prognosis for any infected cat must be considered guarded.¹⁵ In 2 prospective studies, approximately 80% of naturally infected, asymptomatic cats eventually self-cured (i.e., adult worms died naturally); of these, 68% and 25% developed clinical signs over time, whereas 32% and 75% remained free of symptoms.^{10,15} The other 20% or so of asymptomatic cats died 8 to 41 months after diagnosis, often very suddenly. A retrospective study of symptomatic cats seen at a referral center showed a median survival time of 1.5 years overall, though survival was much better (4 years) when only those cats still alive one day after presentation were considered.¹¹ In this study of 50 cats with natural heartworm infection, 9 were regarded as having survived heartworm disease (i.e., lived >1000 days postdiagnosis). Survival of 11 cats treated with sodium caparsolate was not significantly different from that of the 30 managed without adulticide. Likewise, youth (≤ 3 years of age), gender, presence of dyspnea, cough, heartworm antigenemia, and echocardiographically identifiable worms did not appear to impact survival. The effect of heartworm infection on survival has been compared with that of other cardiovascular diseases in cats. Overall, the prognosis is comparable with that of hypertrophic cardiomyopathy, the most benign of primary feline heart diseases.²⁹ Although many cats appear to tolerate heartworm infection well, and some are able to self-cure without grave consequences, it is important to remem-

Table 2. Spectrum of Activity of Commercially Available Feline Heartworm Preventive Products in the United States

Product (mode of application)	Heartworm	Roundworm	Hookworm	Ear mite	Flea
Ivermectin (oral)	+		+		
Milbemycin oxime (oral)	+	+	+		
Selamectin (topical)	+	+	+	+	+
Moxidectin plus imidacloprid (topical)	+	+	+	+	+

ber that the presence of a single worm can prove fatal.^{2,16} The best approach to feline heartworm disease is to prevent it through use of chemoprophylaxis.

Prevention against Infection

Heartworm chemoprophylaxis in cats has proven benefits. Pulmonary pathology and clinical signs were compared in 3 groups of cats experimentally infected with *Dirofilaria immitis*: 1) untreated control cats, 2) cats treated with ivermectin beginning at 84 days postinfection to kill immature heartworms arriving in the lungs, and 3) cats given monthly heartworm preventive (selamectin) beginning at 28 days postinfection.¹ Cats in the second group had marked pulmonary arteriolar and alveolar inflammation, at times equal in severity to that observed in the control group. Both groups also exhibited intermittent signs of lethargy, depression, and dyspnea. In contrast, cats that received heartworm preventive had no clinical signs, and the histological appearance of their lung tissue was more or less normal. Therefore, elimination of heartworm larvae before they reach the lungs can prevent the clinical and pathological changes associated with both HARD and adult heartworm infections.

Unfortunately, only a small minority of veterinarians regularly prescribes heartworm preventive for cats. In a survey of 1101 veterinary clinics in the western United States, 13% had a clinic policy of recommending heartworm prevention for feline patients.³⁰ Of a population of pets presented at the University of Pennsylvania teaching hospital from 1999 to 2006, a mere 12% of cats were receiving chemoprophylaxis for heartworm compared with 80% of dogs.³¹ The nationwide number is even worse with <5% of cats receiving preventive, according to an independent market research group.³² With knowledge of the detrimental effects that adult and larval stages of *Dirofilaria immitis* can potentially have on any exposed cat, it is clear that current practices need to be improved. There are several highly effective products on the market for preventing adult heartworm infections in cats, all of which belong to the macrocyclic lactone family: ivermectin, milbemycin, moxidectin, and selamectin. Alone, or formulated as a combination parasiticide, these monthly medications offer the added benefit of concomitantly treating gastrointestinal and/or external parasites (Table 2).

Management Strategies for Veterinarians

Heartworm preventives offer a wealth of benefits with few side effects. Chemoprophylaxis should be administered to all

cats, housed indoors or outdoors, that live in heartworm-endemic regions. Cats do not generally need to be heartworm tested before beginning a heartworm preventive because, first, definitive diagnosis is difficult to achieve; second, cats are not typically patent, eliminating the likelihood of an adverse reaction to preventive treatment; and third, most macrocyclic lactones typically kill microfilariae slowly, again reducing or eliminating the chance of an adverse reaction. The veterinary profession has been slow to adopt heartworm preventive use in cats. It is important for veterinarians to begin taking this proactive preventive stance because heartworm infection in cats is a multisystemic disease, has no easy cure, is easily preventable, and macrocyclic lactone heartworm preventives have a broad spectrum of activity against a variety of endoparasites and ectoparasites.

Though our understanding of the unique features of feline heartworm disease has greatly improved in recent years, the management of heartworm-infected cats has not gotten any simpler. Hopefully, with further study into this complicated disease, more insights will be gained that will guide future clinical practice.

References

1. Blagburn BL, Dillon AR: Feline heartworm disease: solving the puzzle. *Vet Med* 102:7-14, 2007 (suppl)
2. Lee ACY, Montgomery SP, Theis JH, et al: Public health issues concerning the widespread distribution of canine heartworm disease. *Trends Parasitol* 26:168-173, 2010
3. Ryan WG, Newcomb KM: Prevalence of feline heartworm disease—a global review, in *Proceedings of the Heartworm Symposium '95*. Auburn, AL, American Heartworm Society, pp 79-86, 1995
4. Dillon R: Feline dirofilariasis. *Vet Clin North Am Small Anim Pract* 14:1185-1199, 1984
5. Holmes RA, Clark JN, Casey HW, et al: Histopathologic and radiographic studies of the development of heartworm pulmonary vascular disease in experimentally infected cats, in *Proceedings of the Heartworm Symposium '92*. Batavia, IL, American Heartworm Society, pp 81-89, 1992
6. McCall JW, Dzimiński MT, McTier TL, et al: Biology of experimental heartworm infections in cats, in *Proceedings of the Heartworm Symposium '92*. Austin, TX, American Heartworm Society, pp 71-79, 1992
7. Levy JK, Snyder PS, Taveres LM, et al: Prevalence and risk factors for heartworm infection in cats from northern Florida. *J Am Anim Hosp Assoc* 39:533-537, 2003
8. Labarthe N, Serrao ML, Melo YF, et al: Mosquito frequency and feeding habits in an enzootic canine dirofilariasis area in

- Niteroi, State of Rio de Janeiro, Brazil. Mem Inst Oswaldo Cruz 93:145-154, 1998
9. Carleton RE, Tolbert MK: Prevalence of *Dirofilaria immitis* and gastrointestinal helminths in cats euthanized at animal control agencies in northwest Georgia. Vet Parasitol 119:319-326, 2004
 10. Genchi C, Venco L, Ferrari N, et al: Feline heartworm (*Dirofilaria immitis*) infection: a statistical elaboration of the duration of the infection and the life expectancy in asymptomatic cats. Vet Parasitol 158:177-182, 2008
 11. Atkins CE, DeFrancesco TC, Coats JR, et al: Heartworm infection in cats: 50 cases (1985-1997). J Am Vet Med Assoc 217:355-358, 2000
 12. Knight DH, Lok JB: Seasonality of heartworm infection and implications for chemoprophylaxis. Clin Tech Small Anim Pract 13:77-82, 1998
 13. Bowman DD, Atkins CE: Heartworm biology, treatment, and control. Vet Clin Small Anim 39:1127-1158, 2009
 14. Blagburn BL: Feline heartworm disease: Puzzling and poorly understood. Compend Contin Educ Vet Pract 31:10-11, 2009 (suppl)
 15. Venco L, Genchi C, Genchi M, et al: Clinical evolution and radiographic findings of feline heartworm infection in asymptomatic cats. Vet Parasitol 158:232-237, 2008
 16. Litster AL, Atwell RB: Feline heartworm disease: a clinical review. J Feline Med Surg 10:137-144, 2008
 17. Dillon AR, Warner AE, Brawner W, et al: Activity of pulmonary intravascular macrophages in cats and dogs with and without *Dirofilaria immitis*. Vet Parasitol 158:171-176, 2008
 18. Browne LE, Carter TD, Levy JK, et al: Pulmonary arterial disease in cats seropositive for *Dirofilaria immitis* but lacking adult heartworms in the heart and lungs. Am J Vet Res 66:1544-1549, 2005
 19. Iizuka T, Hoshi K, Ishida Y, et al: Right atriotomy using total venous inflow occlusion for removal of heartworms in a cat. J Vet Med Sci 71:489-491, 2009
 20. Small MT, Atkins CE, Gordon SG, et al: Use of a nitinol gooseneck snare catheter for removal of adult *Dirofilaria immitis* in two cats. J Am Vet Med Assoc 233:1441-1445, 2008
 21. Simon F, Kramer LH, Roman A, et al: Immunopathology of *Dirofilaria immitis* infection. Vet Res Commun 31:161-171, 2007
 22. Dingman P, Levy JK, Kramer LH, et al: Association of *Wolbachia* with heartworm disease in cats and dogs. Vet Parasitol 170:50-60, 2010
 23. Morchon R, Ferreira AC, Martin-Pacho JR, et al: Specific IgG antibody response against antigens of *Dirofilaria immitis* and its *Wolbachia* endosymbiont bacterium in cats with natural and experimental infections. Vet Parasitol 125:313-321, 2004
 24. Kramer L, Grandi G, Leoni M, et al: *Wolbachia* and its influence on the pathology and immunology of *Dirofilaria immitis* infection. Vet Parasitol 158:191-195, 2008
 25. Berdoulay P, Levy JK, Snyder PS, et al: Comparison of serological tests for the detection of natural heartworm infection in cats. J Am Anim Hosp Assoc 40:376-384, 2004
 26. DeFrancesco TC, Atkins CE, Miller MW, et al: Use of echocardiography for the diagnosis of heartworm disease in cats: 43 cases (1985-1997). J Am Vet Med Assoc 218:66-69, 2001
 27. Schafer M, Berry CR: Cardiac and pulmonary artery mensuration in feline heartworm disease. Vet Radiol Ultrasound 36:499-505, 1995
 28. Nelson CT: *Dirofilaria immitis* in cats: anatomy of a disease. Compend Contin Educ Vet Pract 7:382-389, 2008
 29. Atkins CE, Cote E, DeFrancesco TC, et al: Prognosis in feline heartworm infection: comparison to other cardiovascular disease, in Proceedings of the Heartworm Symposium '01. Batavia, IL, American Heartworm Society, pp 41-44, 2001
 30. Bowman DD, Torres CJ, Mannella C: Survey of 11 western states for heartworm (*Dirofilaria immitis*) infection, heartworm diagnostic and prevention protocols, and fecal examination protocols for gastrointestinal parasites. Vet Ther 8:293-304, 2007
 31. Gates MC, Nolan TJ: Factors influencing heartworm, flea, and tick preventative use in patients presenting to a veterinary teaching hospital. Prev Vet Med 93:192-200, 2010
 32. Pfizer Animal Health: Independent market research, 2005
 33. Atkins CE: Feline heartworm disease, in Ettinger SJ (ed): Textbook of Veterinary Internal Medicine, vol 2 (ed 6). Philadelphia, Saunders, pp 1137-1144, 2005