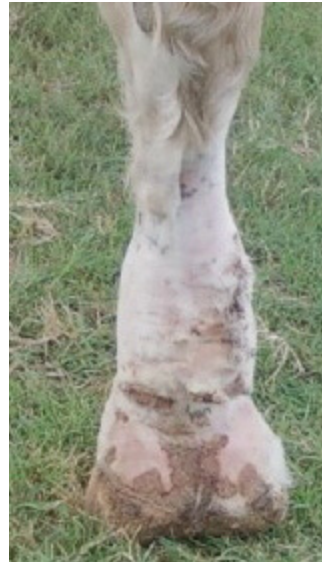

Control of Chorioptic Mange Mites on Horses, Donkeys, and Mules

Several types of mange mites can parasitize horses, donkeys, and mules (equids). These microscopic creatures often cause irritation, skin lesions, and continuous licking or scratching of fetlock areas, and can be a primary or contributing cause for pastern dermatitis. The most common mites found infesting equids are *Chorioptic* sp. Other genera of mange mites, such as *Sarcoptes* sp., *Psoroptes* sp., and *Demodectic* sp., are rarely diagnosed due to their susceptibility to macrocyclic lactone dewormers (ivermectin and moxidectin), the widely-used products in equid husbandry.

Life Cycle and Ecology of Chorioptic Mites

Although all four species of mites have been reported in horses, chorioptic mites pose the most significant problem. Chorioptes are considered skin surface dwellers and feed mostly on skin debris and scales. They are often found on the lower limbs with occasional lesions extending to the abdomen, groin, axilla, anus, and tail. Adults can survive for months wherever skin debris accumulates (e.g., bedding, stable floors, saddle blankets). The clinical signs of mange are more common in warm months and on pastured horses than in winter months and on stalled animals. These mites can be transmitted between animals through direct contact or indirectly by grooming equipment or other objects.



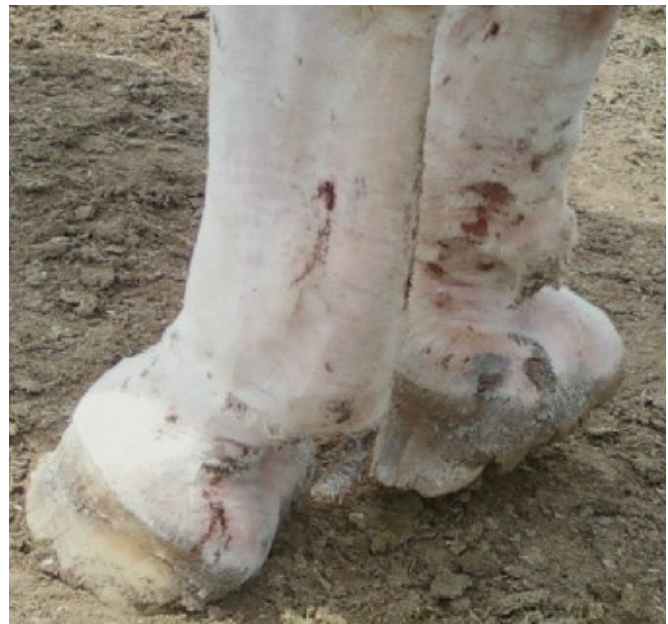1a.

Figures 1a and 1b.

The skin lesions in these pictures are typical of those seen in chronic cases of chorioptic mange. In both cases, the lesions were visible after the legs were clipped.

(a) The rough, crusting lesions on the plantar (rear) surface of the pastern, and between the bulbs of the heels of a Belgian horse

(b) These scab-like lesions are seen on the outside and inside of the pasterns, and on the bulbs of the heel.



1b.



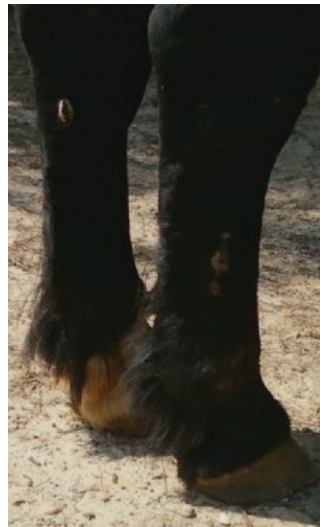Figures 2. This recently clipped Belgian horse is seen scratching rear leg on a feeder.

Symptoms and Signs

Because of their surface feeding, chorioptic mites appear to produce less severe infestations and clinical signs than some mites. Chorioptic lesions are usually limited to the lower legs and pasterns, tail, and perianal area and are associated with pastern dermatitis, a skin condition. Signs and symptoms of infestation include reddening of the skin (erythema), papules, crust formation, hair loss, skin thickening, lower limb edema or swelling, and other irregular skin lesions (Figures 1a and b). Lesions may be associated with itching and irritation, as some affected equids will be scratching, chewing, and licking mite-infested skin; stomping their feet; or rubbing against feeders, posts, fences, or other surfaces (Figure 2). However, *Chorioptes* mite infestation is not considered to be as pruritic as infestation with *Psoroptes* or *Sarcoptes* mites. In severe cases, oozing (which causes hair to mat), open wounds and scabs from scratching, thickened skin, and secondary bacterial or fungal infections may occur. Pastern dermatitis can occur in any breed, but appears to be much more common in the dense-feathered draft (draught) horses or mules. Horses with obvious and thickened tufts of hair on the fetlocks, particularly Belgian, Shire, Clydesdale and Friesian horse breeds, may be more severely affected; however, thin haired, light horse breeds, donkeys, or mules may also become affected (Figures 3a and 3b). The long pastern hair, or feathers, contributes to an environment more conducive for mite



3a.



3b.

Figure 3.

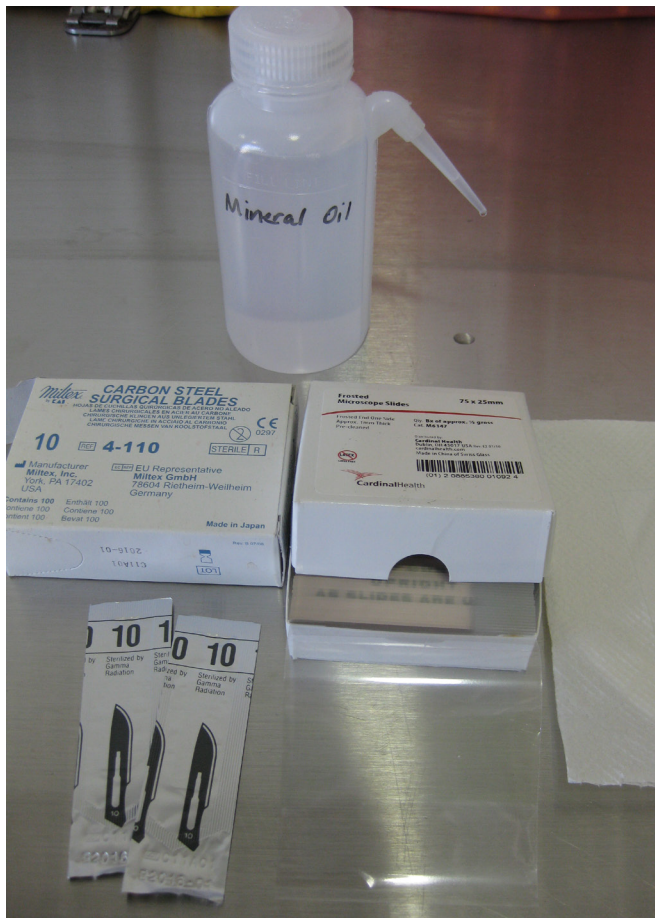
These two pictures show excessive hair or feathers on the pastern areas of a Percheron (a) and a second Percheron horse with feathers which has visible, hyperkeratotic and crusting lesions on and above the fetlock (b).

growth and reproduction, while also allowing for a barrier against many of the commonly used treatments for mites.

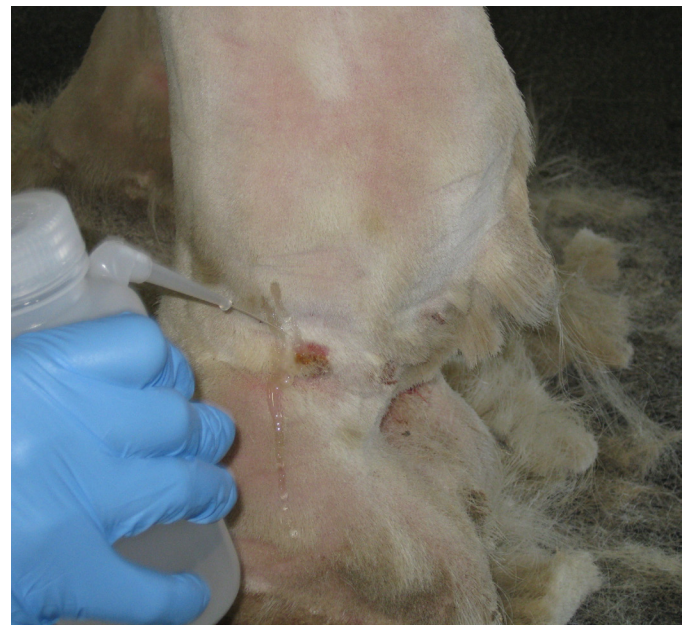The number of mites on infested animals has little to no effect on the severity of the lesions. Hypersensitivity to mites occurs in some animals. In severe cases, only a few mites might result in serious, self-inflicted lesions, whereas animals with a large number of mites might show few or no clinical signs.

Diagnosis


Early and accurate detection is critical in controlling skin infestations. Mange mites are easily visualized with either a magnifying glass or a microscope. The most consistent way of diagnosing mites is by microscopic examination of skin scrapings taken from the affected areas. Scrapes from the scabbing lesions and crusts around the active skin lesions would yield



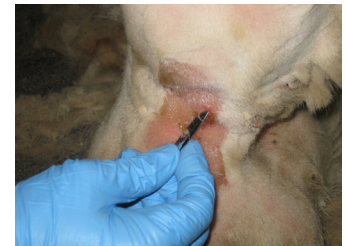4a.



4b.



4c.



4d.

Figure 4.

- (a) Items needed for skin scrapings include mineral oil, microscope slides, and scalpel blades (preferably #10 blades).
- (b) After the area around the lesion has been clipped of excessive hair, lesions should be identified. In this picture, the squeeze bottle holding mineral oil is lightly sprayed on the area of the lesion, saturating the area to be scraped.
- (c) It is preferable that the person taking the sample wear gloves. The scalpel blade should be held firmly at a 90 degree angle to the skin. Areas near the periphery of the lesions should be carefully scraped, collecting a good combination of skin, scales, and other tissue mixed with mineral oil. Although *Chorioptes* mites are surface dwellers, scrapes should be made deep enough to obtain some blood in the samples.
- (d) All scraped tissue is carefully placed on microscopic slide.

the best results (Figures 4a to d). To make the mites more visible, digest or clean the scraped material of skin, hair, and other debris with 10 percent potassium hydroxide (KOH). Chorioptic mites have an oval-shaped and dorsoventrally flattened body, which is about 400 μ m long in females; males are about $\frac{1}{4}$ smaller. Chorioptes have four pairs of legs that are robust and moderately long, except the very short fourth pair in males and the more slender third and fourth pairs in females. All the pairs of legs have short, distal, unjointed stalks (suchers), except the third pair in females, which end in two long setae (Figure 5).

To perform a skin scraping, clip the hair, then saturate the area with mineral oil. Using a #10 scalpel blade, scrape the skin and crusts on the edge of the lesions and apply any material obtained to a glass microscopic slide. Mites can be viewed easily at 40x or 100x magnification.

Because pastern dermatitis is also associated with fungi or bacterial infection, skin cultures or biopsies can ensure an accurate diagnosis. An agricultural or veterinary entomologist, veterinary parasitologist, or veterinarian should be consulted to aid in the diagnosis and identification of parasitic mites.

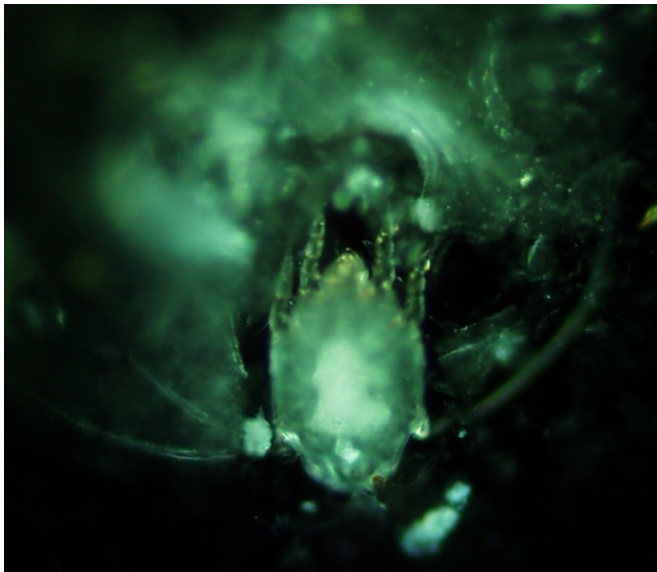


Figure 5. This chorioptic mange mite was scraped from the pastern of a Percheron horse. *Chorioptes* have four pairs of legs that are robust and moderately long, except the shorter fourth pair in males, and the more slender third and fourth pairs in females. All the pairs of legs have short, distal, unjointed stalks (suchers) except the third pair of legs in females, which end in two long setae.

Treatment

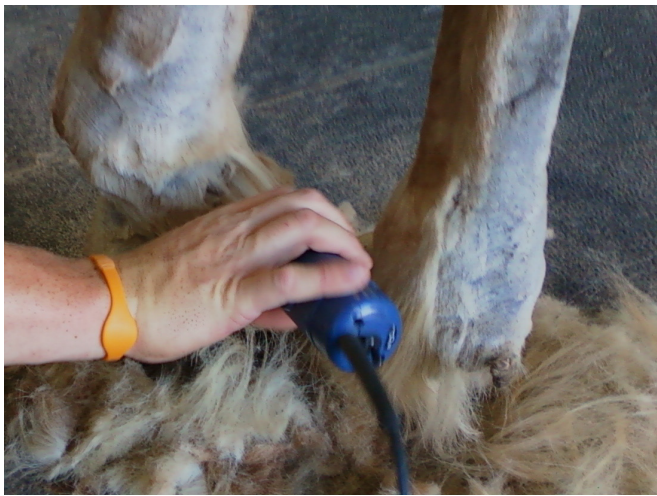Clipping or shaving the long hair or feathers on the pasterns makes checking the skin easier, lesions more visible, cleaning of affected areas more thorough, and penetration and exposure for direct application treatments better. While owners may prefer not to clip the feathers, particularly in show horses, doing so will drastically improve the chances of treatment success. Removing excess hair will enhance the contact time and improve the efficacy of mite control chemicals (Figure 6a and 6b). Thorough cleaning of the affected areas with shampoos that aid in the removal of skin debris, such as keratolytic shampoos and selenium sulfide shampoo, will usually aid in mite removal and the control of secondary fungal or bacterial infections and minimize the clinical signs or symptoms. Properly restrain the animal while cleaning, grooming, or removing hair to ensure safety. The use of sedation, stocks, or other handling equipment may be required.

Insecticides, endectocides, and other chemical agents have all been employed in attempts to control this mange infestation in equids. Chorioptic mange appears to be only partially susceptible to macrocyclic lactone drugs (such as ivermectin and moxidectin) approved for routine de-worming in horses. Because of the surface feeding habits of *Chorioptes*, drug exposure is low. The macrocyclic lactones may effectively reduce mite numbers, but are rarely curative. There is no advantage to injecting these products instead administering them orally. One study showed greater crusting of lesions when moxidectin was used in the treatment regimen.

Parasiticides approved for cows or dogs have been used with mixed success when applied topically and in an extra-label fashion. Doramectin, fipronil, and eprinomectin all show some efficacy, but complete herd removal might be difficult.

Direct application of insecticides or other chemical agents may vary in effectiveness. There are many anecdotal reports of mite control success when lime sulfur is applied directly to the infested areas of the skin as either a shampoo or spray. At least one study confirms its effectiveness when applied to the infested skin areas. The value of direct application of coumaphos appears to be questionable, while the use of cypermethrin, permethrin, or other pyrethroid insecticides may be useful in mite control on individual animals, but are rarely effective in removal of the problem from a farm.

The efficacy of all therapies appear to be enhanced when combined with clipping the long hair around affected areas, and shampooing or scrubbing to remove all crusts, scales, and other skin debris before the application of chemical agents.



6a.



6b.

Figure 6. Clipping allows for lesion exposure and identification; removes the protective barrier that the thick hair coat provides; facilitates scrubbing, cleaning, and crust removal; and permits direct contact of medications with the skin. After hair removal and scrubbing the pastern area with a scale removing shampoo, medications or insecticides can be applied. Safety of the person clipping the affected areas of the horse is critical, as this procedure may place the caregiver in awkward, dangerous places. **(a)** The caregiver should consider consulting a veterinarian to sedate some animals. **(b)** The near leg has been clipped from mid-cannon down, exposing several scab-like lesions. A comparison of the near and far leg of this Belgian horse demonstrates the contrast of heavily haired, feathered lower leg versus one that is clipped, cleaned, and ready to be treated.

Prevention and Control

As mites can be spread by direct or indirect contact, care should be taken to avoid sharing brushes, combs, tack, or other objects between affected and non-affected animals. Affected animals should be separated from those that appear to have no active signs of the disease. Insecticide application (e.g., pyrethrins, carbamates) to tack and grooming equipment, stalls, and lounging areas may be of value in reducing re-infestation of recently treated animals, and the spread of the condition.

When multiple horses co-habit pastures, barns, or working areas, all should be treated. The clipping of excess hair in affected regions, such as the pasterns, and treating all horses may aid in the management of mites and this condition. Premise spraying with pyrethrins and cleaning saddles, grooming equipment, and other tack will also help reduce the recurrence.

Some animals with few or no clinical signs may harbor chorioptic mites, and serve as carrier animals. Since carrier animals play a role in the continuation of an outbreak, identification and treatment of these non-symptomatic equids are indicated. Whenever treating what appears to be resistant cases, the caregiver should contact a veterinarian, agricultural entomologist, or a parasitologist to ensure the correct diagnosis is made, mites are properly identified, and no confounding or concurrent conditions exist (such as fungal or bacterial infections, or fly bite dermatitis).

References

- Knottenbelt, D.C.: 9 - *Metazoan/Parasitic Diseases in Pascoe's Principles of Equine Dermatology*, 2nd ed.; Knottenbelt D.C., ed. Saunders/Elsevier, 191-197, 2009.
- Osman, S.A., A. Hanaty, and S.E. Amar. *Clinical and Therapeutic Studies on Mange in Horses*. *Vet Parasitol* 141:191-195, 2006.
- Paterson, S., and K. Coumbe. *An Open Study to Evaluate Topical Treatment of Equine Chorioptic Mange with Shampooing and Lime Sulphur Solution*. *Vet Dermatol* 20:623-629, 2009.
- Geburek, F., E. Deegen, M. Hewicker-Trautwein, and B. Ohnesorge. Verrucous Pastern Dermatitis Syndrome in Heavy Draught Horses. Part II: Clinical Findings. (in German). *Dtsch Tierarztl Wochenschr* 112:243-251, 2005.
- Rendle, D.I., H.J. Cottle, S. Love, K.J. Hughes. Comparative Study of Doramectin and Fipronil in the Treatment of Equine Chorioptic Mange. *Vet Rec* 161:335-338, 2007.
- Ural, K., B. Ulutas, S. Kar. Eprinomectin Treatment of Psoroptic Mange in Hunter/jumper and Dressage Horses: a Prospective, Randomized, Double-blinded, Placebo-controlled Clinical Trial. *Vet Parasitol* 156:353-357, 2008.
- Geburek, F., E. Deegen, M. Hewicker-Trautwein, B. Ohnesorge. The Development of Verrucous Pastern Dermatitis Syndrome in Heavy Draught Horses. Part I: Review of the literature. (in German). *Dtsch Tierarztl Wochenschr* 112:211-214, 2005.
- Cremers, H.J. The Incidence of Chorioptes Bovis (Acarina: Psoroptidae) on the Feet of Horses, Sheep, and Goats in the Netherlands. *Vet Q* 7:283-289, 1985.
- Colles, C.M., K.M. Colles, J.R. Galpin. Equine Pastern Dermatitis. *Equine Vet Educ* 22:566-570, 2010.
- Mignon, B., B. Losson. Dermatitis in a horse associated with the Poultry Mite (*Dermanyssus gallinae*). *Vet Dermatol* 19:38-43, 2008.
- Pugh D.G., Xing Ping Hu: Mange Mite Infestations and Control in New World Camelids (Artiodactyla P: Camelidae). International Camelid Health Conference for Veterinarians, The Ohio State University, Columbus Ohio, March 21-25, 2012. pp SA: 60-66.
- Rufenacht, S., P.J. Roosje, H. Sager, M.G. Doherr, R. Straub, P. Goldinger-Muller, V. Gerber. Combined Moxidectin and Environmental Therapy Do Not Eliminate Chorioptes Bovis Infestation in Heavily Feathered Horses. *Vet Dermatol* 22:17-23. 2011.
- J.D. Littlewood, J.F. Rose, S. Paterson. Oral Ivermectin Paste for the Treatment of Chorioptic Mange in Horses. *Vet Rec* 137:661-663, 1995.
- Boersema, J.H. [Effectiveness of Coumaphos Against Chorioptes Bovis in a Horse with Foot-mange (author's transl)]. (in Dutch). *Tijdschr Diergeneeskd* 103:377-380, 1978.



ANR-1444

David Gartrell Pugh, Veterinary Clinic Fellow, **Xing Ping Hu**, *Extension Entomologist*, Professor, Entomology and Plant Pathology, **Kelly Hughes Bourke**, Veterinary Clinic Fellow, all at Auburn University.

Use pesticides only according to label directions. Follow all directions, precautions, and restrictions that are listed. Do not use pesticides in ways other than those specified on the label.

Trade names are used only to give specific information. The Alabama Cooperative Extension System does not endorse or guarantee any product and does not recommend one product instead of another that might be similar.

For more information, call your county Extension office. Look in your telephone directory under your county's name to find the number.

Published by the Alabama Cooperative Extension System (Alabama A&M University and Auburn University), an equal opportunity educator and employer.

New Feb 2013, ANR-1444

© 2013 by the Alabama Cooperative Extension System. All rights reserved.

www.aces.edu