



Disponible en ligne sur

ScienceDirect
www.sciencedirect.com

Elsevier Masson France

EM|consulte
www.em-consulte.com


64th International Days of Clinical Endocrinology – Henri-Pierre Klotz: Hormones & Fertility

Turner Syndrome and Fertility

Mette Viuff^{a,b}, Claus H. Gravholt^{a,c,*}^a Department of Molecular Medicine, Aarhus University Hospital, Aarhus N, Denmark^b Department of Gynaecology and Obstetrics, Aarhus University Hospital, Aarhus N, Denmark^c Department of Endocrinology, Aarhus University Hospital, Aarhus, Denmark

INFO ARTICLE

Keywords :

Ovarian dysgenesis
 Estradiol
 Testosterone
 Infertility
 Cryo preservation
 Anti mullerian hormone
 Inhibin B

ABSTRACT

Turner syndrome (TS) is tightly associated with hypergonadotropic hypogonadism and ovarian dysgenesis, typically resulting in infertility in the great majority of patients. Therefore females with TS are usually treated with female sex steroids from 11–12 years of age until the normal age of natural menopause of around 53–54 years of age. Infertility is rated among females with TS as a distressing concern and a detractor from a good quality of life. Options for motherhood for females with TS has expanded during recent years. Originally, only adoption was an option, unless of course for the small minority of TS females that still has ovarian function and are capable of achieving pregnancy through normal means. Oocyte donation has become the mainstream option in many countries and seems to work well, especially if patients have been treated with optimal estrogen and gestagen for a prolonged time before the intervention. It comes with an increased risk of cardiovascular complications and TS oocyte donation pregnancies are viewed as high risk pregnancies necessitating increased vigilance. Oocyte cryopreservation of own oocytes is also becoming an option in a select group of TS and has special challenges. Ovarian tissue cryopreservation is a promising new techniques that has been applied successfully in children with cancer. Currently, several trials are running around the world evaluating this techniques in TS. The genetics and genomics behind the ovarian dysgenesis seen in TS is not understood, but new studies have elucidated global changes in DNA methylation and RNA expression in blood from persons with TS and it is likely that similar changes are present in the ovaries. We still, however, need more thorough research to fully uncover the genetic background of ovarian failure in TS. Gene expression studies and methylation analysis from ovarian TS tissues still needs to be performed.

© 2022 Les Auteurs. Publié par Elsevier Masson SAS. Cet article est publié en Open Access sous licence CC BY (<http://creativecommons.org/licenses/by/4.0/>).

1. Introduction

Hypergonadotropic hypogonadism is one of the most consistent traits in Turner syndrome (TS) affecting up to 95% of the all TS women. Through decades, a TS diagnosis was equivalent to a life with infertility. Despite a broad range of several other comorbidities, dealing with infertility is one of the most detrimental factors affecting quality of life in both young women with TS and their parents [1,2]. However, during the past decades new possibilities for assisted reproductive techniques have become available, which may improve fertility and pregnancy outcomes in TS women. Furthermore, genetic research towards understanding the basal development and origin of ovarian failure has evolved.

2. Ovarian failure and the impact of sex hormone insufficiency

A condition for obtaining pregnancy is a completed puberty with maturation of both ovaries and the uterus. Most girls and women with Turner syndrome undergoes premature ovarian failure during childhood or early adolescence, before sufficient pubertal maturation. Spontaneous menarche is only present in 4–12% of 45,X females, although more frequent among mosaic karyotypes (28–45%) [3–5]. Only a minority continue to have regular menstrual bleedings into adulthood (3–9%, depending on karyotype) [4]. Hence, gonadal dysfunction leads to underdeveloped secondary sex characteristics, such as diminished breast development and uterine growth.

According to international guidelines, TS girls should be treated with estrogen from the age of 11–12 years old and later progesterone is added to ensure breakthrough bleedings [6].

Besides ensuring uterine growth [7], estrogen has a wide range of beneficial effects across the entire body and receptors are present

DOI de l'article original : <https://doi.org/10.1016/j.ando.2022.05.004>.

* Corresponding author at: Department of Endocrinology, Aarhus University Hospital, Aarhus, Denmark.

Adresse e-mail : ch.gravholt@dadlnet.dk (C.H. Gravholt).

<https://doi.org/10.1016/j.ando.2022.06.001>

0003-4266/© 2022 The Authors. Published by Elsevier Masson SAS. This is an open access article under the CC BY license (<http://creativecommons.org/licenses/by/4.0/>).

in the endometrium, ovaries, brain, heart, kidney, adrenal glands, liver, lungs, intestinal mucosa, bones, skin, endothelial cells, adipose tissue and immune system [8,9]. It improves liver functioning, thyroid functioning, bone structure, decreases the risk of fractures and hypertension [10,11]. Estrogen therapy is essential in order to obtain optimal uterine growth and endometrial development ideal for embryo transfer during adult life [12,13]. Furthermore estrogen ensures widening of the hips which is advantageous when giving birth [14].

For long androgens has been understudied in relation to TS, although androgens are decreased by approximately 30–50% in TS women compared with normal menstruating females [15,16]. New evidence suggests that androgens might affect follicle maturation in early stages [17,18]. Androgen production is controlled by luteinizing hormone (LH) during the gonadotropin-dependent stages of folliculogenesis [19], with a so-called therapeutic window, since low levels of LH stimulates androgen production, and high levels inhibits production [20].

The role of progesterone and especially substitution of progesterone in TS is also severely understudied, and currently there are no studies that point to the best choice of a gestagen to be used for substitution.

3. The nature of Turner syndrome oocytes and ovarian reserve

During normal development of the female foetus, formation of germ cells and oocytes begins shortly after sexual differentiation at week 6, reaching a maximum of up to five million germ cells by week 8–12 [21,22]. Once the foetus enters second trimester the human ovary enters meiosis and puts an end to formation of additional oocytes. During second and third trimester of the normal pregnancy a gradual loss of oocytes occurs, being reduced to approximately 400,000 oocytes at birth [23].

In Turner syndrome, the tipping point of germ cell creation and depletion occurs at the same time as in eukaryotic women, however, at a much more accelerated speed [24,25]. Both oogenesis and folliculogenesis are compromised in TS females. In ovaries from 45,X TS fetuses, oogonia were observed, however with no occurrence of primordial, preantral, or antral follicles compared with eukaryotic female foetal ovaries [25], and connective tissue predominates in the ovaries. Some TS fetuses might even reach depletion before or around birth. Nevertheless the majority probably reaches “menopause” during childhood or early adulthood.

In postnatal ovaries, the presence of follicles is related to karyotype, age, signs of spontaneous puberty, and serum concentrations of gonadotropins and anti-Müllerian hormone (AMH), with 26%–60% of ovaries presenting with some follicles histologically in girls and young women with TS [26–29]. A high rate of abnormal follicle morphology was detected, and follicle fluid from small antral follicles had lower concentrations of estrogen and testosterone and higher concentrations of AMH compared with controls [27].

When assessing oocyte quality, it is also of great importance to know the chromosomal content of both oocytes and stromal cells in TS primordial follicles. Peek et al investigated 46 oocytes in 10 TS women discovering that most oocytes were eukaryotic (90%), while the granulosa cells were largely monosomic [28], demonstrating mosaicism confined to within the ovaries. This reveals that the ovarian content of X chromosome material is not always equivalent to the karyotypes performed on lymphocytes from a blood sample. Furthermore a case report of a girl diagnosed with 45,X, presented with cryptic mosaicism in the ovary [30]. The take home message being that karyotype is not always associated with oocyte quality and follicles from 45,X women might be available and useable for assisted reproductive techniques.

4. Genetics and infertility in Turner syndrome

X chromosome monosomy and infertility is undoubtedly intertwined, and X chromosome deletions and X-autosome balanced translocations have been associated with POI [31]. Thus giving rise to the definition of a POI critical region from Xq13-Xq21 (POI2) to Xq23-q27 (POI1) [31]. Several candidate genes on the X chromosome have been suggested to contribute to ovarian function in Turner syndrome. In particular *KDM6A*, *USP9X*, *ZFX*, *BMP15* [32] (Fig. 1).

KDM6A (a histone demethylase) is involved in gonadal dysgenesis, reestablishment of pluripotency and germ cell development [33]. The gene is both differentially expressed and methylated in Turner syndrome [34]. Haploinsufficiency is associated with altered histone modifications potentially affecting transcriptional regulation of genes central for reproduction [33]. *USP9X* escapes X inactivation and is a ubiquitin-specific protease. Disturbances of ubiquitin are considered a plausible mechanism because the *Drosophila* orthologue of *USP9X* is required for eye development and oogenesis [35]. *USP9X* is differentially methylated in Turner syndrome [34]. *ZFX* is a DNA binding gene, which acts as a transcriptional factor, and knockout of *ZFX* in mice is related to decreased number of germ cells in both males and females [36]. *ZFX* is differentially expressed in TS compared with control females [34,37]. *BMP15* encodes bone morphogenetic protein 15, which stimulated AMH synthesis and stimulates folliculogenesis and is expressed in the oocyte [38]. It belongs to a large family of proteins that play a regulating role in ovarian function and *BMP15* knockout female mice are subfertile with decreased ovulation rates [39]. Lastly, it has been proposed that epigenetic modifications in itself leads to ovarian failure. Hence that *XIST*, through X inactivation, plays a pivotal role in regulation of ovarian functioning on the X chromosome [35]. However, most analyses to date are performed on blood from TS adults. Gene expression from TS ovarian tissue has still to be investigated in order to establish a reliable pathophysiology of infertility in TS.

5. Pregnancy potential and predictive markers

The question remains how we predict which TS women who are eligible for fertility treatment using own oocytes and which ones we immediately should refer to other options such as adoption or oocyte donation. In eukaryotic females, AMH and antral follicle count, assessed by vaginal ultrasound, are used as predictive markers of fertility [40]. AMH is produced by the granulosa cells, hence serum level is equivalent to the size of the growing follicle pool, and, indirectly, also of the primordial follicle pool, reflecting the ovarian reserve [41]. FSH and BMP is the prime stimulator of synthesis, while estrogen inhibits AMH and AMHR2 receptor expression [38]. Follicle fluid from young TS girls have high concentrations of AMH along with lower concentrations of estrogen and testosterone [27], maybe reflecting the abnormal function of follicle cells, or maybe due to a rescue effect, since AMH has been shown to prevent follicular atresia [27,38].

Measurement of AMH has also been applied to TS women and correlates significantly with ovarian function in pubertal TS girls (12–25 years) [42]. AMH levels are associated with karyotype, spontaneous pubertal development, LH/FSH values and the presence of follicles [26,42–45]. Hence it seems useful as a tool for assessing the ovarian reserve in pubertal TS girls. However, in one study performing oocyte cryopreservation in seven TS women, there was no correlation between antral follicle count, AMH or oocytes retrieved, and despite low AMH measurements oocytes were available in all seven TS girls [46].

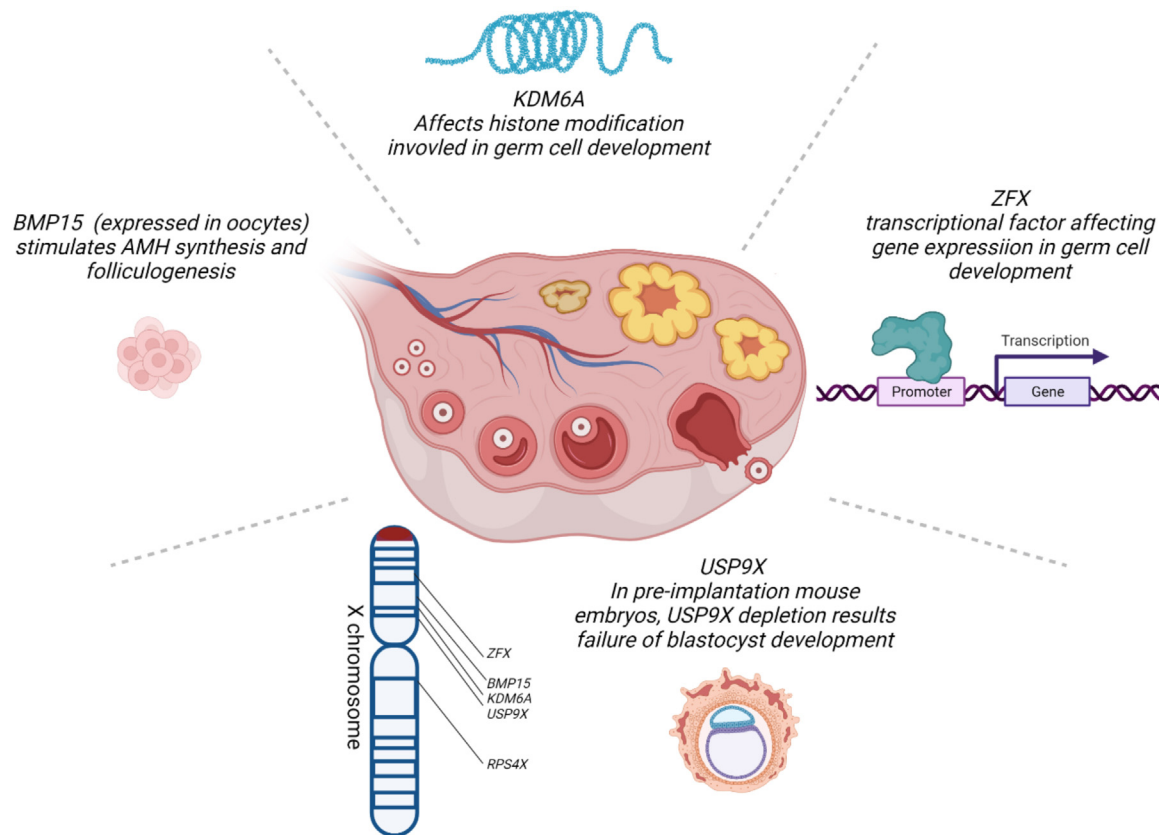


Fig. 1. Some X chromosomal genes proposed involved in Turner syndrome infertility and the location on the X chromosome. *KDM6A* is a histone demethylase that might affect histone modifications potentially affecting transcription of genes central for reproduction. *USP9X* is a ubiquitin-specific protease, and disturbances of ubiquitin could affect oogenesis. *ZFX* is a DNA binding gene, which acts as a transcriptional factor, and knockout of *ZFX* in mice is related to decreased number of germ cells in both males and females. *BMP15* encodes bone morphogenetic protein 15, which stimulated AMH synthesis and folliculogenesis.

So far no evidence exist towards the use of AMH in younger pre-pubertal girls, and since the ovarian demise starts at an early age, we are in need for a predictive marker useful in younger TS children.

Since inhibin B is secreted from the developing follicles during mid-childhood, it has been suggested as a predictor of ovarian function in prepubertal children with Turner syndrome [47]. It is believed that serum AMH and inhibin B levels reflects ovarian reserve independent from the hypothalamo-pituitary-gonadal axis [42,48]. Spontaneous puberty has been correlated with higher levels of AMH and inhibin B, however inhibin B has been demonstrated detectable without any signs of spontaneous puberty in TS women [47].

6. Assisted reproductive techniques, oocyte donation or adoption?

Spontaneous conceptions are rare and most women with Turner syndrome depend on assisted reproductive technologies or alternative options such as fostering and adoption, to become a parent. Although reports of spontaneous pregnancies in both 45,X and mosaic TS women has been published with an incidence between 2–7% [6,45,49,50], oocyte donation has previously been and is still the most frequently used option in TS women [6]. It results in fewer miscarriages compared to pregnancies using own oocytes [51], and the clinical pregnancy rate are 30–46% depending on method (fresh/frozen) and therefore similar to corresponding rates among eukaryotic oocyte recipients [52].

However, pregnancies achieved with donated oocytes are in general associated with a higher incidence of gestational hypertension, pre-eclampsia compared with conventional IVF [53], and up to 35% of TS women receiving oocyte donation develops hypertensive disorders [13]. Since TS women lacks endogenous estrogen production, it is pivotal that appropriate estrogen replacement therapy has been initiated to ensure uterine growth and enhance the chances of implantation [6]. In TS girls between 16–24 years old, 4 mg oral 17-beta-estradiol induced a steeper increase in uterine volume, and uterine growth depended both on dose and duration of treatment [7] and has also beneficial effects on body composition [54]. Furthermore, during the months leading up to a pregnancy, estrogen treatment must be applied in order to ensure an appropriate endometrial thickness, and the endometrium of TS women tends to respond poorer to estrogen treatment compared to eukaryotic POI women [55], decreasing the chances of implantation. The endometrial response to estrogen treatment has to be monitored by serial ultrasonographic measurements determining the appropriate timing of implantation. Furthermore, fluid in the endometrial cavity is often seen in patients exposed to estrogen after prolonged hypoestrogenism e.g., premature ovarian failure, postmenopausal women, and TS, due to the initiation of glandular activity in the endometrium [56]. Hence, low-dose transdermal estrogen treatment with gradually increasing dose may be the solution to endometrial collections in patients undergoing oocyte donation, as demonstrated in a case report [57]. This emphasizes the importance of sufficient hormone replacement therapy, initiated during puberty, well before fertility request [58].

Oocyte cryopreservation is associated with higher incidence of miscarriages and chromosomal abnormalities [51,59], but is often preferred in order to ensure own genetic offspring, and the

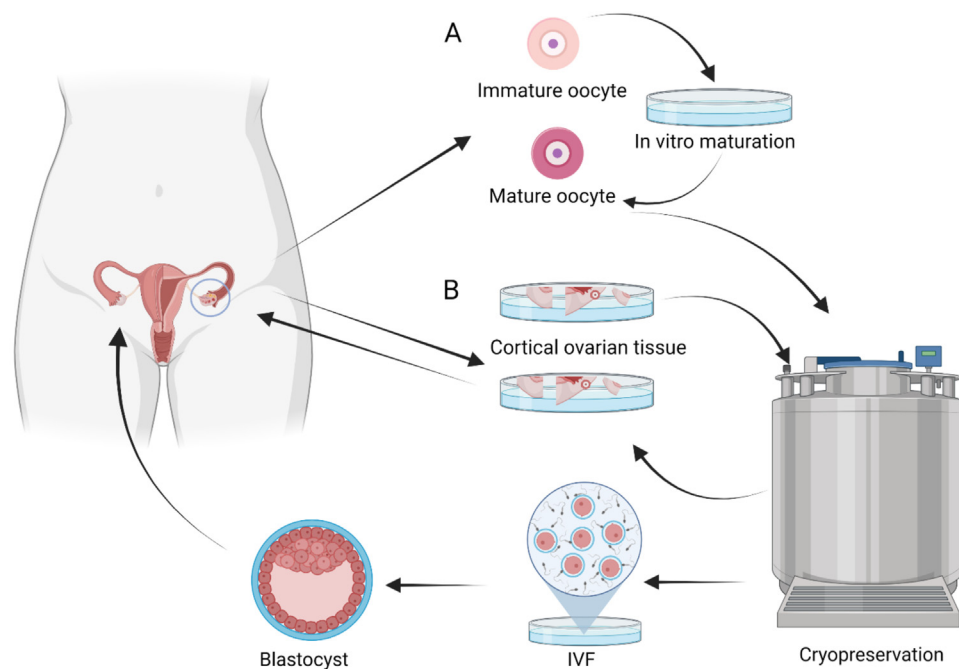


Fig. 2. (A) Oocyte cryopreservation and (B) Cortical cryopreservation. A. Oocyte cryopreservation requires ovarian hyperstimulation followed by retrieving of oocytes and cryopreserving. Thawed oocytes are fertilized and blastocyst stages are transferred to the uterus. B. Using cortical cryopreservation, small pieces of ovarian cortex is cryopreserved. After thawing, cortical tissue is auto transplanted into the abdomen followed by ovarian hyperstimulation, transvaginal oocyte retrieving, fertilization and transfer of blastocyst stages into the uterus.

technique has been successfully applied in women with Turner syndrome [45]. Due to chromosomal aberrations in offspring, prenatal genetic screening should be considered, or at least prenatal testing with chorionic villus sampling during first trimester [60].

During the process of oocyte cryopreservation, mature oocytes are retrieved, vitrified, and cryopreserved after ovarian hyperstimulation (Fig. 2). The method, however, is only applicable during a short time-window from post-puberty until ovarian decline. Hence, this method can only be applied in a very small subgroup of TS women. The first live-born child after vitrification of oocytes in a 45,X/46,XX woman with normal AMH and regular menstrual cycles has just been published [61].

In contrast, ovarian tissue cryopreservation (OTC) seems promising in order to retain fertility in TS women (Fig. 2). The big advantage being that it can be applied to a larger age-group (from 2 years and up) and independent of pubertal stage. The disadvantage being, that it requires a surgical procedure performed in preferable young children. OTC has led to live-born children in surviving cancer patients [62–64], however in TS the procedure is still experimental. So far OTC on TS women has been performed in a cohort from Denmark, Canada and the Netherlands [28,45,65,66]. But so far no live-born children has been reported.

7. Maternal morbidity and mortality during pregnancy

Maternal and fetal complications are inevitably increased in TS pregnancies compared with other women, irrespective of the conception method. A Canadian population based cohort study reported an three-fold increase in neonatal morbidity, but no severe maternal mortality or adverse cardiovascular events in TS women compared with the general female Canadian population [67]. The risk of ischemic placental disease (preeclampsia, placental abruption, and intrauterine growth restriction) and preterm birth before week 37 was increased 3-fold in TS women [67], supporting similar findings in a Swedish register study [68].

Women with TS are predisposed for a wide range of cardiovascular diseases such as hypertension, bicuspid aortic valve and aortic aneurisms and dissections [10,69,70]. All risk factors for adverse outcomes during a pregnancy, and aortic aneurisms can be a fatal pregnancy complication [71,72].

However, newer reports on pregnancy outcomes in women with Turner syndrome from France ($n = 480$), Canada, USA and the Netherlands ($n = 68$), and Finland, Denmark and Sweden ($n = 106$) reported either none or very few cardiovascular events, with a total of only one case of aortic dissection [13,73,74]. This is probably due to improved pre-pregnancy counselling and restriction of access in women with an a priori high risk of cardiovascular complications.

According to guidelines a multidisciplinary (fetal medicine specialists, obstetrician, gynecologist, endocrinologist and cardiologist) screening includes imaging of the thoracic aorta and heart within 2 years before planned pregnancy and evaluation of blood pressure measurement, thyroid functions and blood glucose [6,75]. Relative contraindications increasing the risk of dissection, should be respected, such as bicuspid aortic valve, elongation of the transverse aorta, coarctation of the aorta and hypertension [75], and a careful pre-pregnancy assessment should always be performed. Hypertensive complications during pregnancy is prevalent in 10–60% of all TS pregnancies, underlining the importance of frequent blood pressure measurements during pregnancy [13,76,77].

8. Future perspectives

Decades have passed since Turner syndrome was first described in the 1930s, and in regards of hypogonadism and infertility, many new interesting options have become available. One of the promising ART techniques is ovarian tissue cryopreservation, since it can be used to preserve fertility in all age groups independent of pubertal maturation. Even though we have reached far in understanding the genetics and pathogenesis, we still need more thorough research to comprehend the genetic background of ovarian failure

in TS. Gene expression studies and methylation analysis from ovarian TS tissues still needs to be performed. Maybe in the future, we will be able to preserve the high number of fetal TS oocytes before ovarian diminish begins.

For now, discussion of fertility preservation options is advised as early as possible, even at time of TS diagnosis, and TS girls should be monitored closely assessing continuously ovarian reserve.

Funding

Novo Nordisk Foundation [NNF150C0016474, NNF200C0060610], Familien Hede Nielsens Fond, “Fonden til lægevidenskabens fremme”, and Independent Research Fund Denmark [0134-00406A]. MV was supported by a PhD grant from Aarhus University.

Ethics

No patients were directly involved in the preparing this review.

Disclosure of interest

The authors declare that they have no competing interest.

Références

- [1] Sutton EJ, McInerney-Leo A, Bondy CA, Gollust SE, King D, Biesecker B. Turner syndrome: four challenges across the lifespan. *American journal of medical genetics Part A* 2005;139A:57–66.
- [2] Sylven L, Magnusson C, Hagenfeldt K, von Schoultz B. Life with Turner's syndrome—a psychosocial report from 22 middle-aged women. *Acta endocrinologica* 1993;129:188–94.
- [3] Negreiros LP, Bolina ER, Guimaraes MM. Pubertal development profile in patients with Turner syndrome. *J Pediatr Endocrinol Metab* 2014;27:845–9.
- [4] Pasquino AM, Passeri F, Pucarelli I, Segni M, Munnich G. Spontaneous pubertal development in Turner's syndrome. Italian study group for Turner's syndrome. *The Journal of clinical endocrinology and metabolism* 1997;82:1810–3.
- [5] Lunding SA, Aksglaede L, Anderson RA, Main KM, Juul A, Hagen CP, et al. AMH as Predictor of Premature Ovarian Insufficiency: A Longitudinal Study of 120 Turner Syndrome Patients. *The Journal of clinical endocrinology and metabolism* 2015;100:1030–8.
- [6] Gravholt CH, Andersen NH, Conway GS, Dekkers OM, Geffner ME, Klein KO, et al. Clinical practice guidelines for the care of girls and women with Turner syndrome: proceedings from the 2016 Cincinnati International Turner Syndrome Meeting. *Eur J Endocrinol* 2017;177:1–70.
- [7] Cleemann L, Holm K, Fallentin E, Møller N, Kristensen B, Skouby SO, et al. Effect of Dosage of 17 β -Estradiol on Uterine Growth in Turner Syndrome—A Randomized Controlled Clinical Pilot Trial. *The Journal of clinical endocrinology and metabolism* 2020;105.
- [8] Patel S, Homaei A, Raju AB, Meher BR. Estrogen: The necessary evil for human health, and ways to tame it. *Biomed Pharmacother* 2018;102:403–11.
- [9] Richards JS. Ovarian Cycle. In: Litwack G, editor. *ProQuest Ebook Central*. Elsevier Science & Technology; 2018.
- [10] Viuff MH, Berglund A, Juul S, Andersen NH, Stochholm K, Gravholt CH. Sex Hormone Replacement Therapy in Turner Syndrome: Impact on Morbidity and Mortality. *The Journal of clinical endocrinology and metabolism* 2020;105:468–78.
- [11] Klein KO, Rosenfield RL, Santen RJ, Gawlik AM, Backeljauw PF, Gravholt CH, et al. Estrogen Replacement in Turner Syndrome: Literature Review and Practical Considerations. *The Journal of clinical endocrinology and metabolism* 2018;103:1790–803.
- [12] Hawkins LK, Correia KF, Srouji SS, Hornstein MD, Missmer SA. Uterine length and fertility outcomes: a cohort study in the IVF population. *Human reproduction (Oxford, England)* 2013;28:3000–6.
- [13] Hagman A, Loft A, Wennerholm UB, Pinborg A, Bergh C, Aittomaki K, et al. Obstetric and neonatal outcome after oocyte donation in 106 women with Turner syndrome: a Nordic cohort study. *HumReprod* 2013;28:1598–609.
- [14] Kumar A, Banerjee A, Singh D, Thakur G, Kasarpalkar N, Gavali S, et al. Estradiol: A Steroid with Multiple Facets. *Horm Metab Res* 2018;50:359–74.
- [15] Gravholt CH, Svenstrup B, Bennett P, Sandahl Christiansen J. Reduced androgen levels in adult turner syndrome: influence of female sex steroids and growth hormone status. *Clin Endocrinol (Oxf)* 1999;50:791–800.
- [16] Zuckerman-Levin N, Frolova-Bishara T, Militianu D, Levin M, Aharon-Peretz J, Hochberg Z. Androgen replacement therapy in Turner syndrome: a pilot study. *The Journal of clinical endocrinology and metabolism* 2009;94:4820–7.
- [17] Gleicher N, Weghofer A, Barad DH. The role of androgens in follicle maturation and ovulation induction: friend or foe of infertility treatment? *Reprod Biol Endocrinol* 2011;9:116.
- [18] Yang MY, Fortune JE. Testosterone stimulates the primary to secondary follicle transition in bovine follicles in vitro. *Biol Reprod* 2006;75:924–32.
- [19] Palermo R. Differential actions of FSH and LH during folliculogenesis. *Reprod Biomed Online* 2007;15:326–37.
- [20] Campbell BK, Baird DT, Webb R. Effects of dose of LH on androgen production and luteinization of ovine theca cells cultured in a serum-free system. *J Reprod Fertil* 1998;112:69–77.
- [21] Gondos B, Westergaard L, Byskov AG. Initiation of oogenesis in the human fetal ovary: ultrastructural and squash preparation study. *Am J Obstet Gynecol* 1986;155:189–95.
- [22] Mamsen LS, Lutterodt MC, Andersen EW, Byskov AG, Andersen CY. Germ cell numbers in human embryonic and fetal gonads during the first two trimesters of pregnancy: analysis of six published studies. *Human reproduction (Oxford, England)* 2011;26:2140–5.
- [23] Gougeon A, Ecochard R, Thalabard JC. Age-related changes of the population of human ovarian follicles: increase in the disappearance rate of non-growing and early-growing follicles in aging women. *Biol Reprod* 1994;50:653–63.
- [24] Weiss L. Additional evidence of gradual loss of germ cells in the pathogenesis of streak ovaries in Turner's syndrome. *Journal of medical genetics* 1971;8:540–4.
- [25] Reynaud K, Cortvrint R, Verlinde F, De Schepper J, Bourgain C, Smits J. Number of ovarian follicles in human fetuses with the 45, X karyotype. *Fertility and sterility* 2004;81:1112–9.
- [26] Borgstrom B, Hreinsson J, Rasmussen C, Sheikhi M, Fried G, Keros V, et al. Fertility preservation in girls with turner syndrome: prognostic signs of the presence of ovarian follicles. *The Journal of clinical endocrinology and metabolism* 2009;94:74–80.
- [27] Mamsen LS, Charkiewicz K, Anderson RA, Telfer EE, McLaughlin M, Kelsey TW, et al. Characterization of follicles in girls and young women with Turner syndrome who underwent ovarian tissue cryopreservation. *Fertility and sterility* 2019;111(6):1217–25.
- [28] Peek R, Schleeidoorn M, Smeets D, van de Zande G, Groenman F, Braat D, et al. Ovarian follicles of young patients with Turner's syndrome contain normal oocytes but monosomic 45,X granulosa cells. *Human reproduction (Oxford, England)* 2019;34:1686–96.
- [29] Hreinsson JG, Otaala M, Fridstrom M, Borgstrom B, Rasmussen C, Lundqvist M, et al. Follicles are found in the ovaries of adolescent girls with Turner's syndrome. *The Journal of clinical endocrinology and metabolism* 2002;87:3618–23.
- [30] Nadesapillai S, van der Velden J, Smeets D, van de Zande G, Braat D, Fleischer K, et al. Why are some patients with 45,X Turner syndrome fertile? A young girl with classical 45,X Turner syndrome and a cryptic mosaicism in the ovary. *Fertility and sterility* 2021;115:1280–7.
- [31] Qin Y, Jiao X, Simpson JL, Chen Z-J. Genetics of primary ovarian insufficiency: new developments and opportunities. *Human reproduction update* 2015;21:787–808.
- [32] Fortuño C, Labarta E. Genetics of primary ovarian insufficiency: a review. *Journal of Assisted Reproduction and Genetics* 2014;31:1573–85.
- [33] Berletch JB, Deng X, Nguyen DK, Distche CM. Female Bias in RhoX6 and 9 Regulation by the Histone Demethylase KDM6A. *PLOS Genetics* 2013;9 [e1003489].
- [34] Trolle C, Nielsen MM, Skakkebaek A, Lamy P, Vang S, Hedegaard J, et al. Widespread DNA hypomethylation and differential gene expression in Turner syndrome. *Scientific reports* 2016;6:34220.
- [35] Simpson JL. Genetic and Phenotypic Heterogeneity in Ovarian Failure. *Annals of the New York Academy of Sciences* 2008;1135:146–54.
- [36] Luoh SW, Bain PA, Polakiewicz RD, Goodheart ML, Gardner H, Jaenisch R, et al. Zfx mutation results in small animal size and reduced germ cell number in male and female mice. *Development* 1997;124:2275–84.
- [37] Rajpathak SN, Vellarikkal SK, Patowary A, Scaria V, Sivasubbu S, Deobagkar DD. Human 45, X fibroblast transcriptome reveals distinct differentially expressed genes including long noncoding RNAs potentially associated with the pathophysiology of Turner syndrome. *PLoS One* 2014;9 [e100076].
- [38] di Clemente N, Racine C, Pierre A, Taieb J. Anti-Müllerian Hormone in Female Reproduction. *Endocrine reviews* 2021;42:753–82.
- [39] Yan C, Wang P, DeMayo J, DeMayo FJ, Elvin JA, Carino C, et al. Synergistic roles of bone morphogenetic protein 15 and growth differentiation factor 9 in ovarian function. *Mol Endocrinol* 2001;15:854–66.
- [40] Tsakos E, Tolikas A, Daniilidis A, Asimakopoulos B. Predictive value of anti-müllerian hormone, follicle-stimulating hormone and antral follicle count on the outcome of ovarian stimulation in women following GnRH-antagonist protocol for IVF/ET. *Archives of gynecology and obstetrics* 2014;290:1249–53.
- [41] Visser JA, de Jong FH, Laven JSE, Themmen APN. Anti-Müllerian hormone: a new marker for ovarian function. *Reproduction* 2006;131:1–9.
- [42] Hagen CP, Aksglaede L, Sorensen K, Main KM, Boas M, Cleemann L, et al. Serum levels of anti-müllerian hormone as a marker of ovarian function in 926 healthy females from birth to adulthood and in 172 Turner syndrome patients. *J ClinEndocrinolMetab* 2010;95:5003–10.
- [43] Hamza RT, Mira MF, Hamed AI, Ezzat T, Sallam MT. Anti-Müllerian hormone levels in patients with turner syndrome: Relation to karyotype, spontaneous puberty, and replacement therapy. *Am J Med Genet A* 2018;176:1929–34.
- [44] Visser JA, Hokken-Koelega AC, Zandwijken GR, Limacher A, Ranke MB, Fluck CE. Anti-Müllerian hormone levels in girls and adolescents with Turner syndrome are related to karyotype, pubertal development and growth hormone treatment. *HumReprod* 2013;28:1899–907.
- [45] Schleeidoorn M, van der Velden J, Braat D, Beerendonk I, van Golde R, Peek R, et al. TurnerFertility trial: PROTOCOL for an observational cohort study to

- describe the efficacy of ovarian tissue cryopreservation for fertility preservation in females with Turner syndrome. *BMJ Open* 2019;9 [e030855].
- [46] Talaulikar VS, Conway GS, Pimblett A, Davies MC. Outcome of ovarian stimulation for oocyte cryopreservation in women with Turner syndrome. *FertilSteril* 2019;111:505–9.
- [47] Gravholt CH, Naeraa RW, Andersson AM, Christiansen JS, Skakkebaek NE, Inhibin A and B in adolescents and young adults with Turner's syndrome and no sign of spontaneous puberty. *Human reproduction (Oxford, England)* 2002;17:2049–53.
- [48] Ruzsala A, Wójcik M, Starzyk J. Evaluation of the usefulness of antimüllerian hormone and inhibin B as markers of ovarian activity in patients with Turner syndrome - preliminary results. *Pediatr Endocrinol Diabetes Metab* 2020;26:84–8.
- [49] Hadnott TN, Gould HN, Gharib AM, Bondy CA. Outcomes of spontaneous and assisted pregnancies in Turner syndrome: the U.S. National Institutes of Health experience. *Fertility and sterility* 2011;95:2251–6.
- [50] Mortensen KH, Rohde MD, Uldbjerg N, Gravholt CH. Repeated spontaneous pregnancies in 45, X Turner syndrome. *Obstet Gynecol* 2010;115:446–9.
- [51] Bryman I, Sylven L, Berntorp K, Innala E, Bergstrom I, Hanson C, et al. Pregnancy rate and outcome in Swedish women with Turner syndrome. *Fertility and sterility* 2011;95(8):2507–10.
- [52] Foudila T, Söderström-Anttila V, Hovatta O. Turner's syndrome and pregnancies after oocyte donation. *Human Reproduction* 1999;14:532–5.
- [53] Stoop D, Baumgarten M, Haentjens P, Polyzos NP, De Vos M, Verheyen G, et al. Obstetric outcome in donor oocyte pregnancies: a matched-pair analysis. *Reprod Biol Endocrinol* 2012;10:42.
- [54] Cleemann L, Holm K, Kobbernagel H, Kristensen B, Skouby SO, Jensen AK, et al. Dosage of estradiol, bone and body composition in Turner syndrome: a 5-year randomized controlled clinical trial. *Eur J Endocrinol* 2017;176:233–42.
- [55] Yaron Y, Ochshorn Y, Amit A, Yovel I, Kogosowki A, Lessing JB. Patients with Turner's syndrome may have an inherent endometrial abnormality affecting receptivity in oocyte donation. *Fertility and sterility* 1996;65:1249–52.
- [56] Li TC, Dockery P, Ramsewak SS, Klentzeris L, Lenton EA, Cooke ID. The variation of endometrial response to a standard hormone replacement therapy in women with premature ovarian failure. *An ultrasonographic and histological study. British journal of obstetrics and gynaecology* 1991;98:656–61.
- [57] Goyal N, Jayakrishnan K. Successful Pregnancy after Frozen Embryo Transfer after Recurrent Endometrial Collection in a Patient with Mosaic Turner Syndrome. *J Hum Reprod Sci* 2021;14:91–3.
- [58] Gravholt CH, Viuff MH, Brun S, Stochholm K, Andersen NH. Turner syndrome: mechanisms and management. *Nat Rev Endocrinol* 2019;15:601–14.
- [59] Tarani L, Lampariello S, Raguso G, Colloridi F, Pucarelli I, Pasquino AM, et al. Pregnancy in patients with Turner's syndrome: six new cases and review of literature. *Gynecol Endocrinol* 1998;12:83–7.
- [60] Ye M, Yeh J, Kostera I, Li L. Progress in Fertility Preservation Strategies in Turner Syndrome. *Front Med (Lausanne)* 2020;7:3.
- [61] Strypstein L, Van Moer E, Nekkebroeck J, Segers I, Tournaye H, Demeestere I, et al. First live birth after fertility preservation using vitrification of oocytes in a woman with mosaic Turner syndrome. *J Assist Reprod Genet* 2022.
- [62] Donnez J, Dolmans MM. Ovarian cortex transplantation: 60 reported live births brings the success and worldwide expansion of the technique towards routine clinical practice. *J Assist Reprod Genet* 2015;32:1167–70.
- [63] Van der Ven H, Liebhentron J, Beckmann M, Toth B, Korell M, Krussel J, et al. Ninety-five orthotopic transplantations in 74 women of ovarian tissue after cytotoxic treatment in a fertility preservation network: tissue activity, pregnancy and delivery rates. *Human reproduction (Oxford, England)* 2016;31:2031–41.
- [64] Jensen AK, Kristensen SG, Macklon KT, Jeppesen JV, Fedder J, Ernst E, et al. Outcomes of transplantations of cryopreserved ovarian tissue to 41 women in Denmark. *Human reproduction (Oxford England)* 2015;30:2838–45.
- [65] Kristensen SG, Wakimoto Y, Colmorn LB, Dueholm M, Pors SE, Macklon KT, et al. Use of cryopreserved ovarian tissue in the Danish fertility preservation cohort. *Fertility and sterility* 2021;116:1098–106.
- [66] Huang JY, Tulandi T, Holzer H, Lau NM, Macdonald S, Tan SL, et al. Cryopreservation of ovarian tissue and in vitro matured oocytes in a female with mosaic Turner syndrome: Case Report. *Human reproduction (Oxford England)* 2008;23:336–9.
- [67] Ramage K, Grabowska K, Silversides C, Quan H, Metcalfe A. Maternal, pregnancy, and neonatal outcomes for women with Turner syndrome. *Birth Defects Research* 2020;112:1067–73.
- [68] Hagman A, Kallen K, Barrenas ML, Landin-Wilhelmsen K, Hanson C, Bryman I, et al. Obstetric outcomes in women with Turner karyotype. *The Journal of clinical endocrinology and metabolism* 2011;96:3475–82.
- [69] El-Mansoury M, Barrenas ML, Bryman I, Hanson C, Larsson C, Wilhelmsen L, et al. Chromosomal mosaicism mitigates stigmata and cardiovascular risk factors in Turner syndrome. *Clin Endocrinol (Oxf)* 2007;66:744–51.
- [70] Mortensen KH, Andersen NH, Gravholt CH. Cardiovascular phenotype in Turner syndrome—integrating cardiology, genetics, and endocrinology. *Endocrine reviews* 2012;33:677–714.
- [71] Immer FF, Bansi AG, Immer-Bansi AS, McDougall J, Zehr KJ, Schaff HV, et al. Aortic dissection in pregnancy: analysis of risk factors and outcome. *Ann Thorac Surg* 2003;76:309–14.
- [72] Garvey P, Elovitz M, Landsberger EJ. Aortic Dissection and Myocardial Infarction in a Pregnant Patient with Turner Syndrome. *Obstetrics & Gynecology* 1998;91:864.
- [73] Bernard V, Donadille B, Zenaty D, Courtillot C, Salenave S, Brac de la Perriere A, et al. Spontaneous fertility and pregnancy outcomes amongst 480 women with Turner syndrome. *Human reproduction (Oxford, England)* 2016;31:782–8.
- [74] Grewal J, Valente AM, Egbe AC, Wu FM, Krieger EV, Sybert VP, et al. Cardiovascular outcomes of pregnancy in Turner syndrome. *Heart* 2021;107:61–6.
- [75] Donadille B, Bernard V, Christin-Maitre S. How can we make pregnancy safe for women with Turner syndrome? *Am J Med Genet C Semin Med Genet* 2019;181:100–7.
- [76] Alvaro Mercadal B, Imbert R, Demeestere I, Englert Y, Delbaere A. Pregnancy outcome after oocyte donation in patients with Turner's syndrome and partial X monosomy. *Human reproduction (Oxford, England)* 2011;26:2061–8.
- [77] Chevalier N, Letur H, Lelannou D, Ohl J, Cornet D, Chalas-Boissonnas C, et al. Materno-Fetal Cardiovascular Complications in Turner Syndrome after Oocyte Donation: Insufficient Prepregnancy Screening and Pregnancy Follow-Up Are Associated with Poor Outcome. *J ClinEndocrinolMetab* 2011;96:260–7.