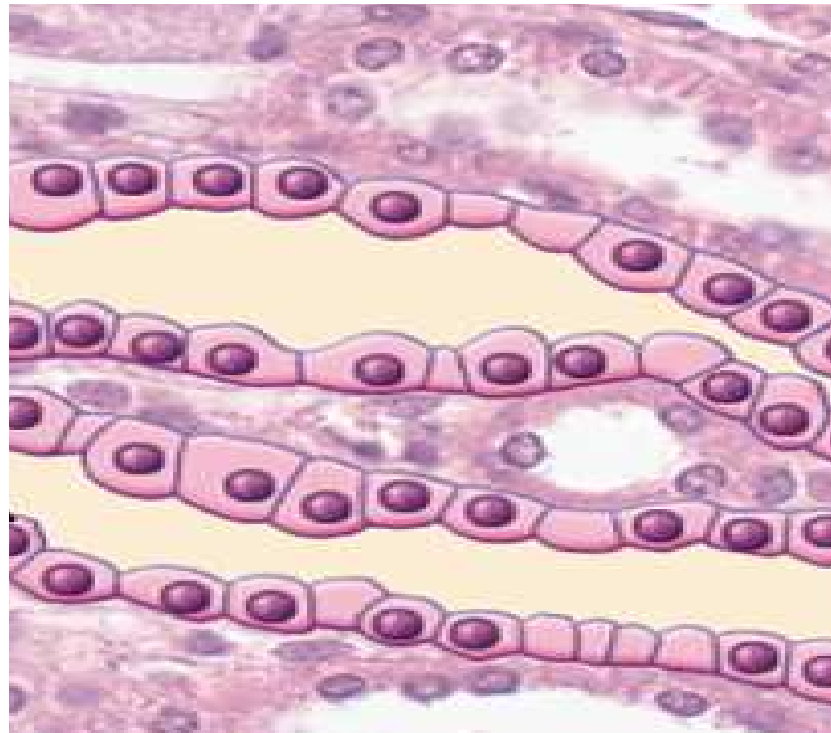


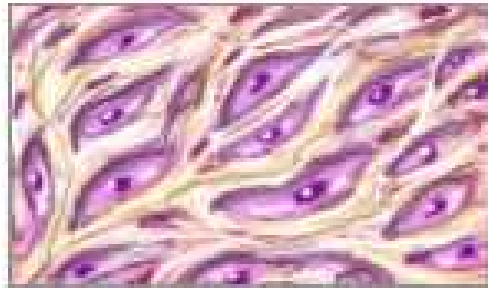Histology **(microscopic anatomy)**



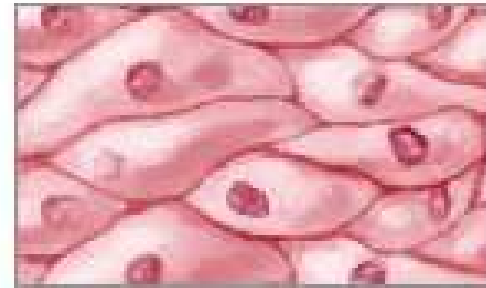The study of tissues

The Study of Tissues


Four types of tissue



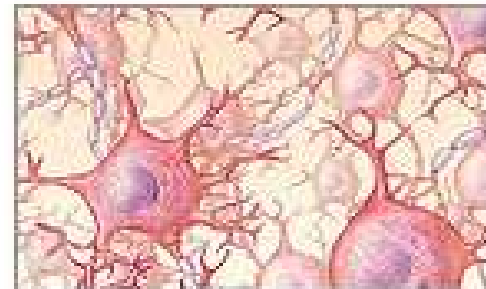
Connective tissue



Epithelial tissue



Muscle tissue



Nervous tissue

The Study of Tissues

Whole body contains only 200 different types of cells

Histology (microscopic anatomy)
study of tissues and how they form organs

Organ = structure with discrete boundaries

composed of 2 or more tissue types

Differences among 4 Tissue Classes

1. Types and functions of cells--
 - For example: Epithelial, CT, Nervous, Muscular
2. Characteristics of the **matrix** (extracellular material)
 - Rubbery, stony, or gelatinous
3. Relative amount of space occupied by cells versus matrix
 - CT vs. muscle and epithelium

Embryonic Tissues

1. Embryo begins as a single cell
 - divides into many cells that form layers (strata)

2. Three primary germ layers

A.ectoderm (outer) gives rise to: epidermis + nervous system

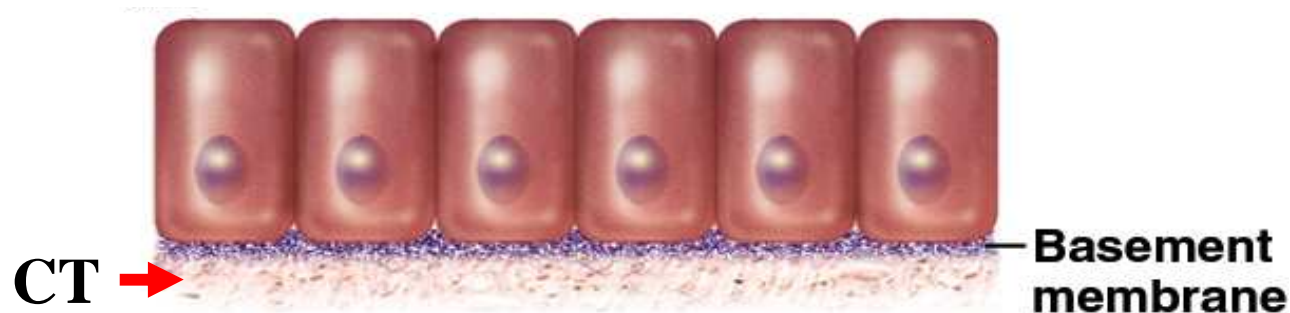B.endoderm (inner): mucous membranes: GI tract and respiratory linings; digestive glands.

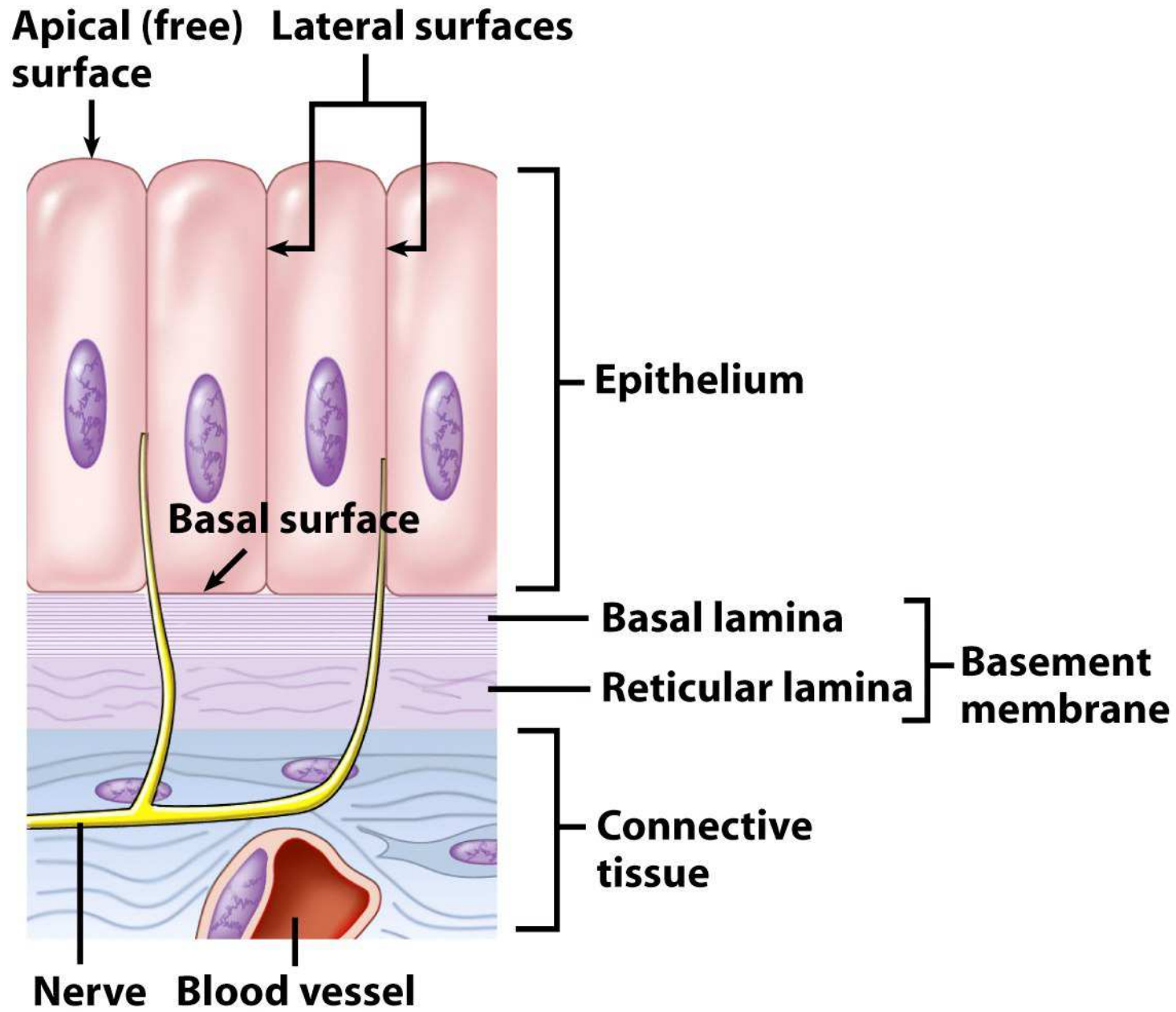
C.mesoderm (middle) forms mesenchyme (gelatinuous tissue) and then give rise to muscle, bone, and blood

-Epithelial tissue

Epithelial Tissue

1. One or more layers of closely adhering cells
2. (Top) Forms a flat sheet with the upper surface exposed to the environment or an internal body cavity
3. (Bottom) Sits on **basement membrane** (basal surface of cells); anchors epithelium to underlying connective tissue
4. **(Nourishment) No room for blood vessels; . . .**





Epithelial Tissue

Arrangement and Cell Shape—

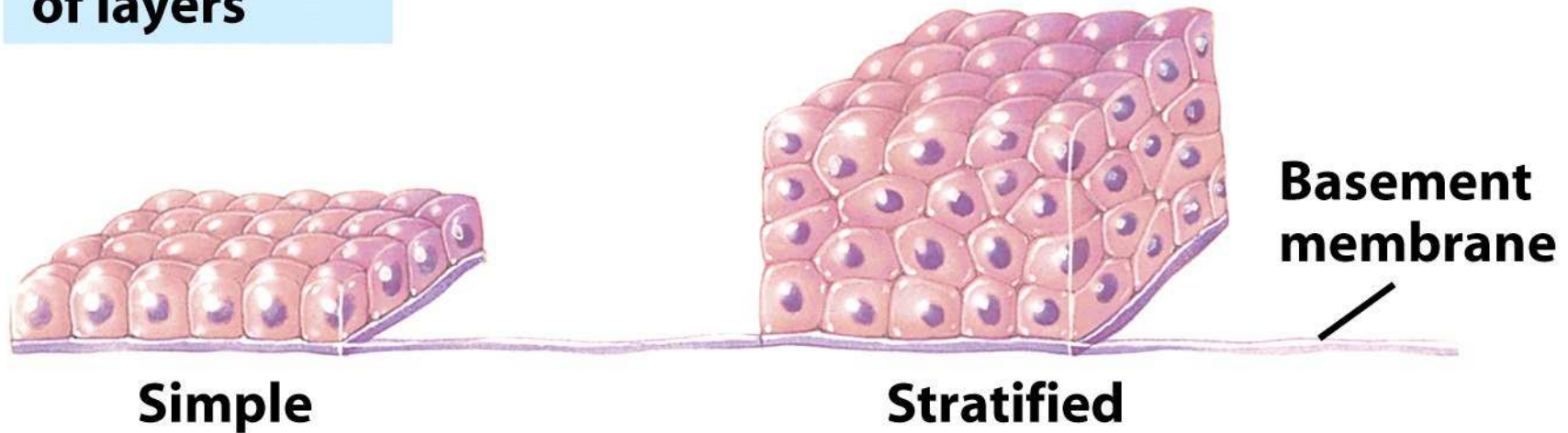
1. Simple epithelium

- contains one layer of cells
- named by shape of cells

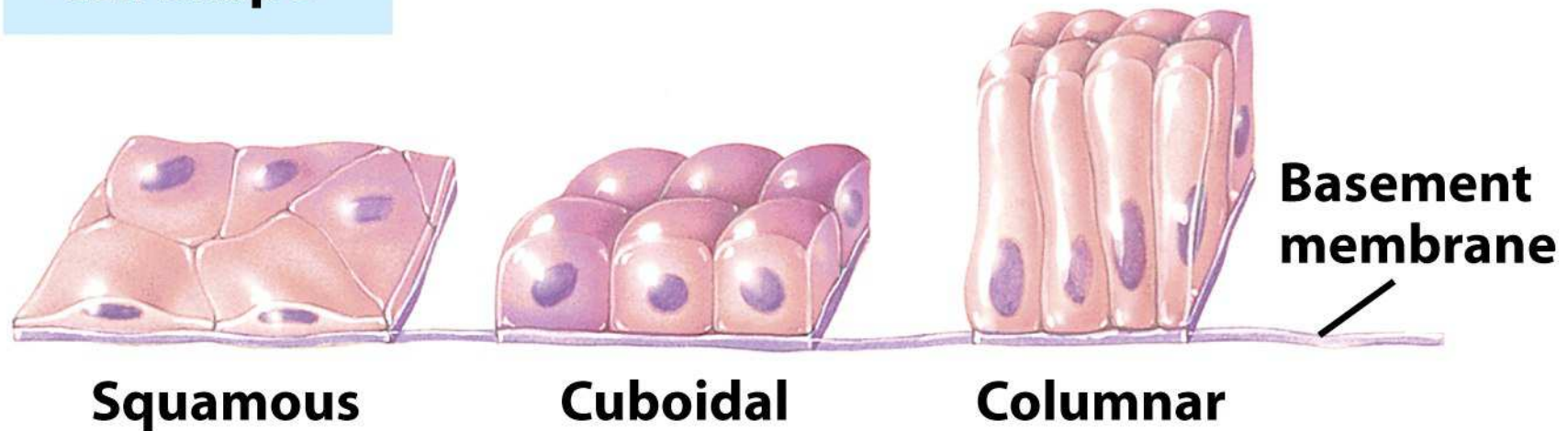
2. Stratified epithelium

- contains more than one layer
- named by shape of *apical cells*

Arrangement of layers



Cell shape



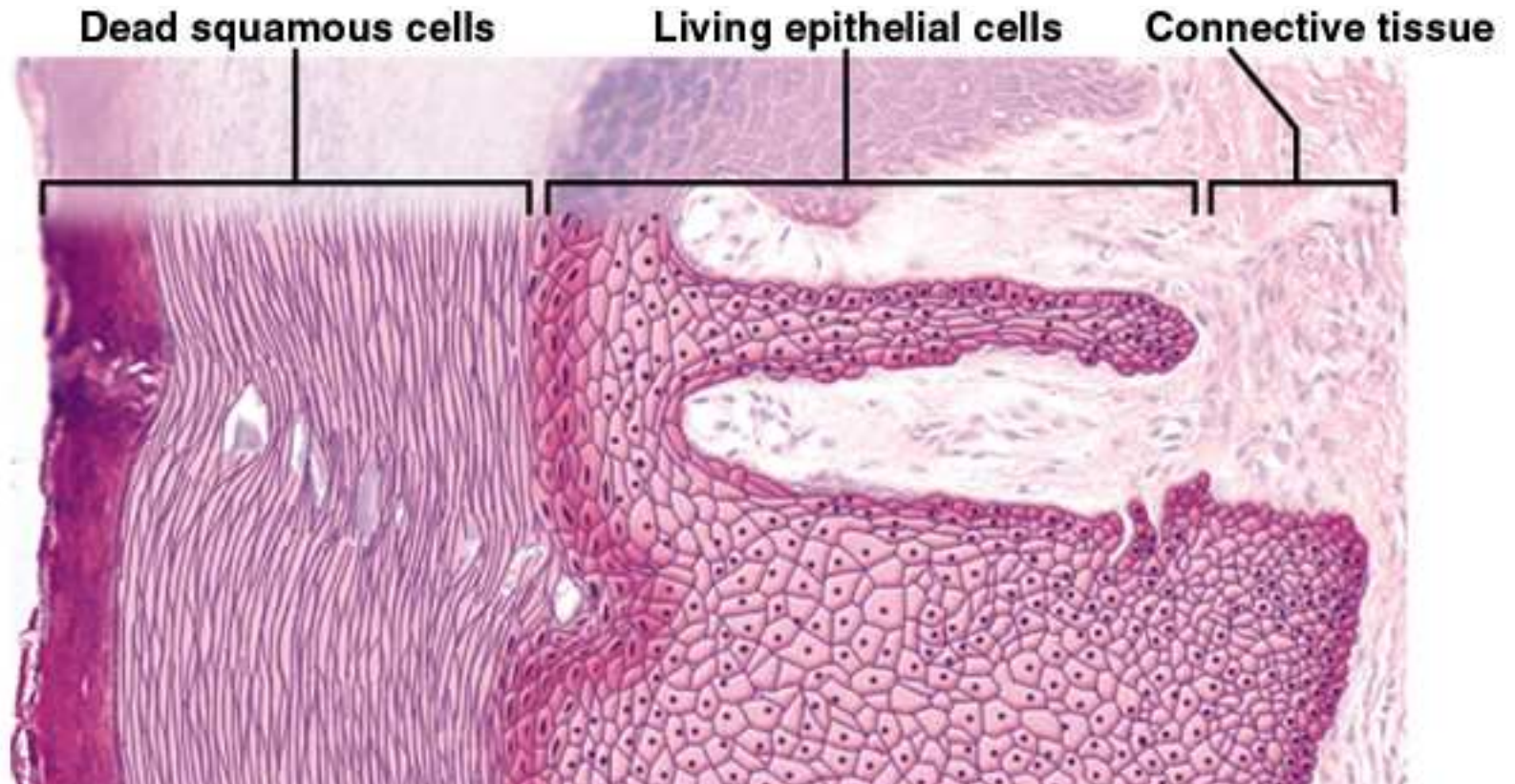
Pseudostratified Epithelium—

1. (Structure) Single row of cells not all of which reach the free surface; nuclei at different levels.
2. (Functions) secretes propels mucus
3. (Locations) most of the upper respiratory system from nasal cavity to bronchi; part of male urethra

§ Stratified Epithelia

- Composed of more than one layer of cells & named for shape of _____ cells
- Deepest cells sit on basement membrane

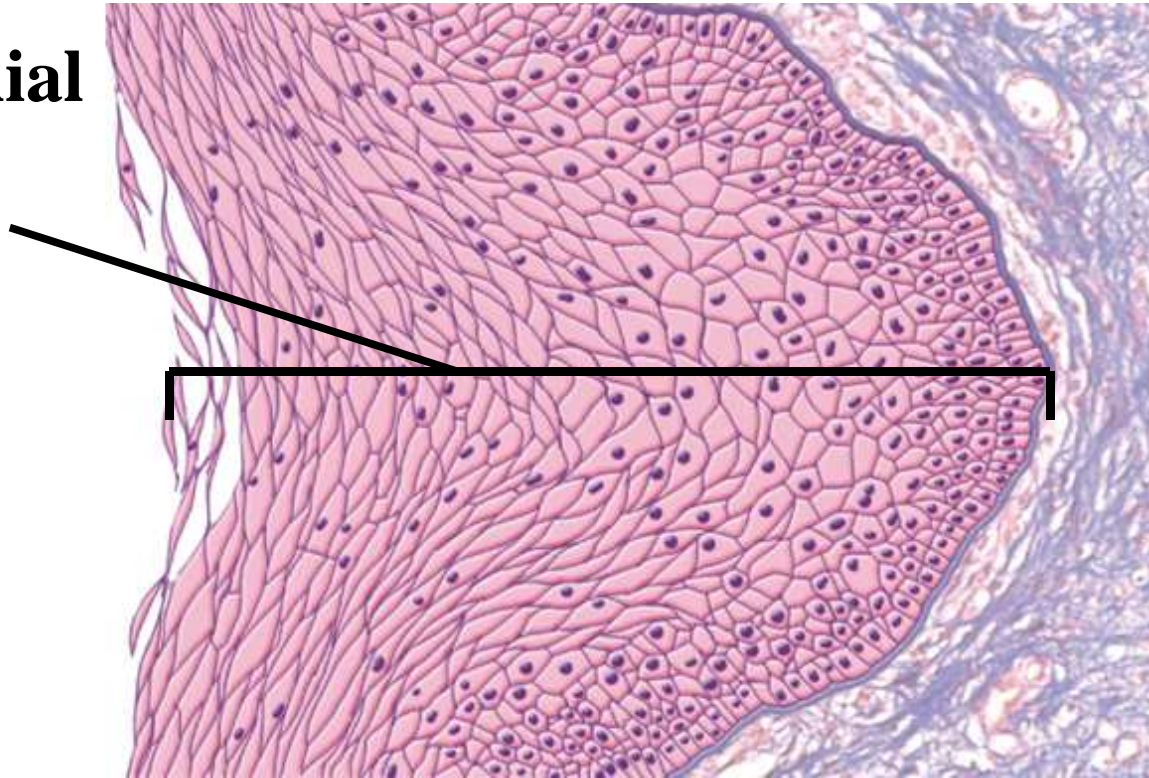
Keratinized Stratified Squamous



- Layers of epithelium covered with compact, squamous cells (no nuclei) packed with protein keratin
- Retards water loss, prevents entrance of organisms
- Forms epidermal layer of skin

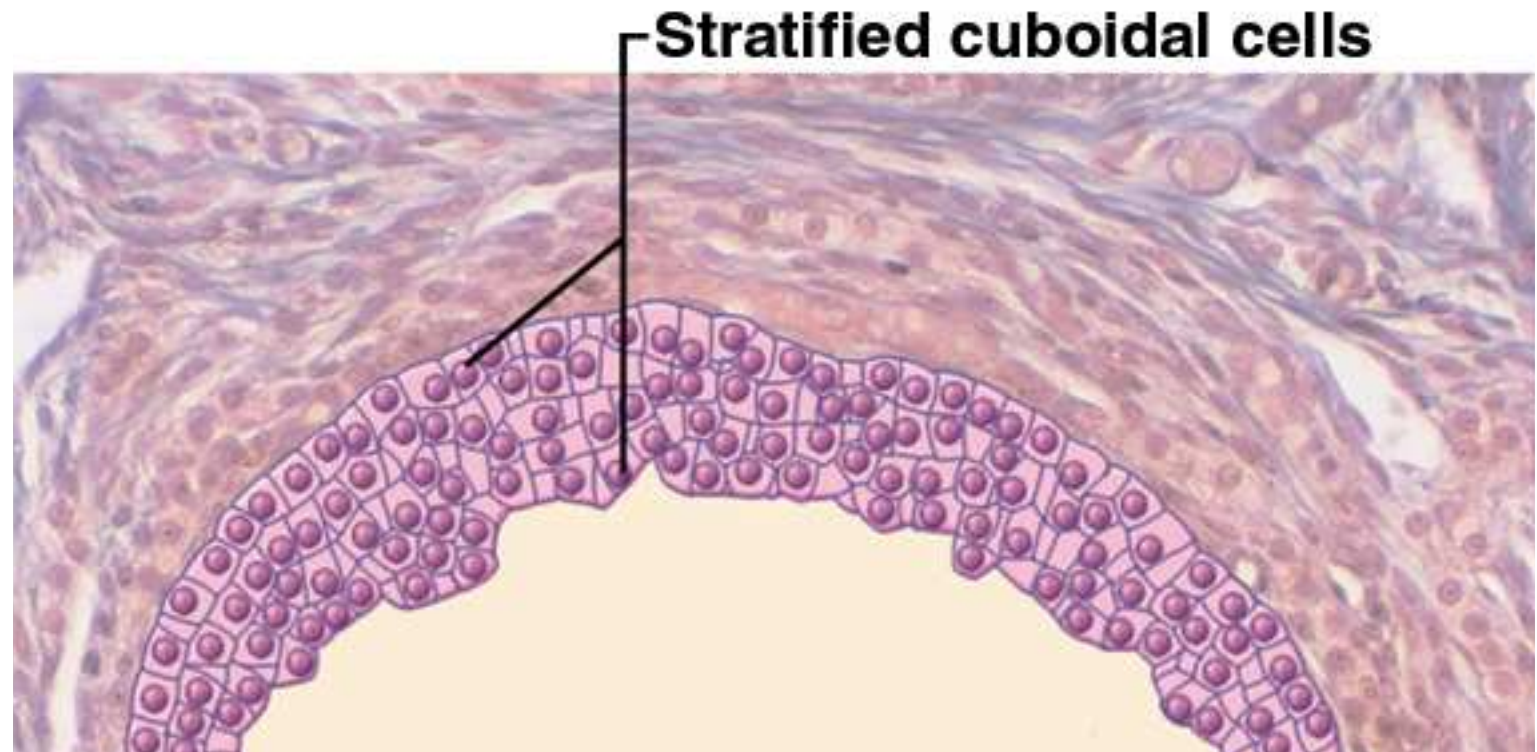
Nonkeratinized Stratified Squamous

**Epithelial
layer**



- Multilayered epithelium that lacks surface layer of dead cells forming moist, slippery layer
- Locations: tongue, oral mucosa, esophagus & vagina

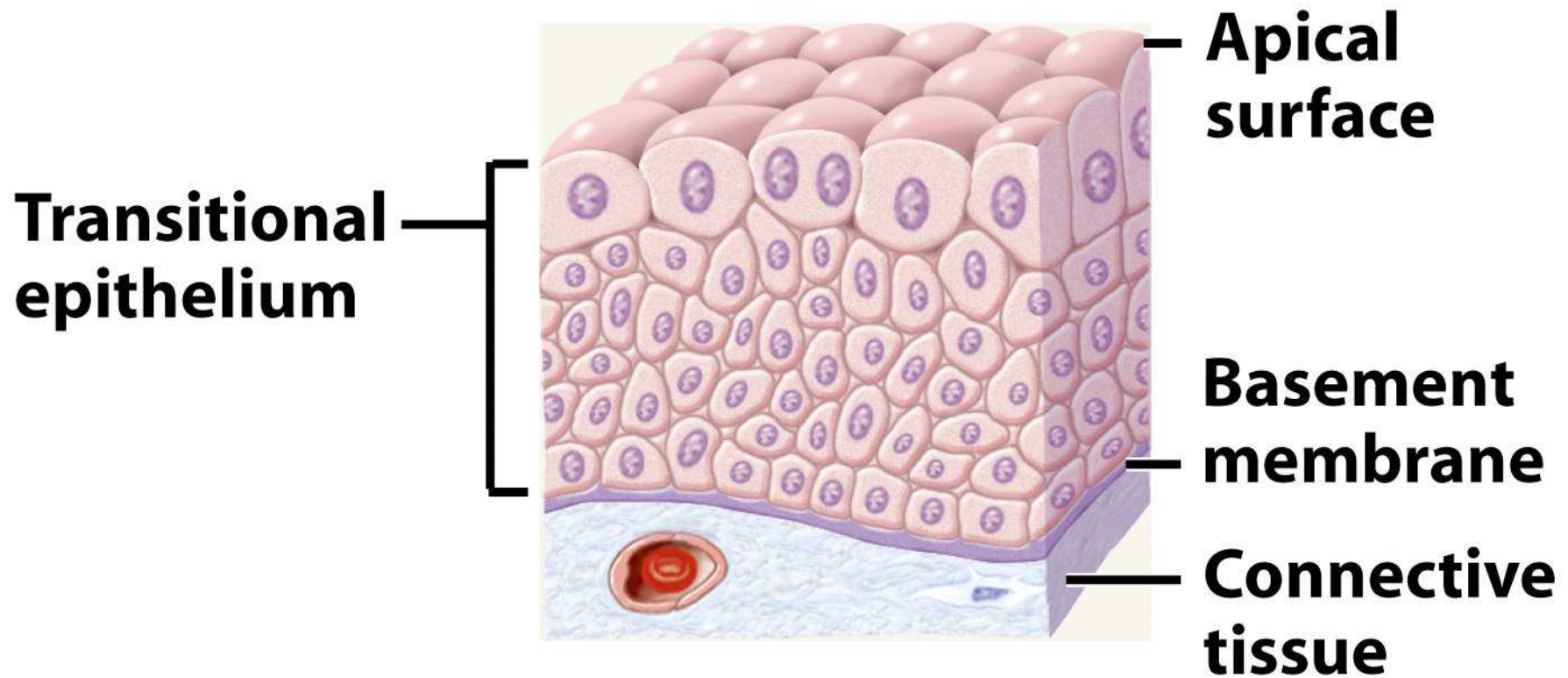
Stratified Cuboidal Epithelium



- (Structure) Two or more layers of cells; surface cells square or round
- (Functions) Secretion and production
- (Locations) Sweat glands, mammary glands, salivary glands, ovarian follicles, seminiferous tubules

Transitional Epithelium

1. (Structure) Multilayered epithelium with **rounded (not flattened)** surface cells
2. (Functions) Allow stretches and distension
3. (Locations) Urinary tract--part of kidney, ureter, urinary bladder, part of the urethra



Relaxed transitional epithelium

-Connective tissue

§ Connective Tissue (CT)

- Most abundant and variable tissue type
- Functions of CT:
 - **Binding of organs --Ex. a tendon connects muscle to bone**
 - **Support, protection, movement -- Ex. bones**
 - **Storage – (energy, electrolytes) Ex. Fats/bones**
 - **Transport -- Ex. Blood**

Ground Substance of C.T.

- Gelatinous or rubbery material found in between cells –
- Consists of 3 classes of large molecules
 - **Glycosaminoglycans** (GAGs) –
 - Polysacharides that attract sodium & hold water
 - **Proteoglycan** is bottlebrush-shaped molecule
 - **Forms thick gel that slows the spread of pathogens**
 - Cell adhesive **glycoproteins**
 - Allow themselves bind to matrix elements

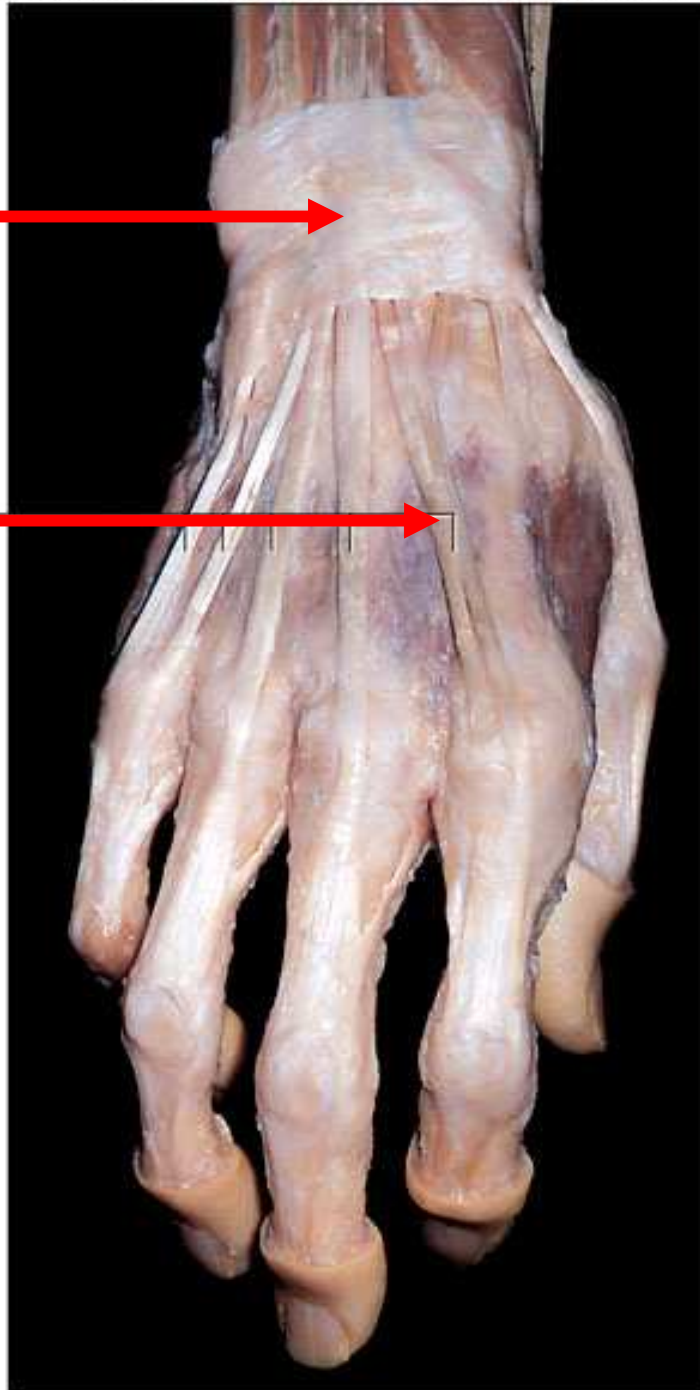
Fibers of C.T.

- **Collagen fibers--called white fibers** **Most abundant protein of the body**
 - **Thick**, tough, resist stretch yet flexible
 - Ex. tendons, ligaments & dermis
- **Elastic fibers--called yellow fibers**
 - recoil like rubberband (elasticity)
 - Ex. skin, lungs & arteries; ability to recoil
- **Reticular fibers**
 - **Thin** collagen fibers coated with glycoprotein
 - Ex. form framework for spleen & lymph nodes

Collagen



**Tendons
(collagen)**



Cells of C.T.

- **Fibroblasts** -- produce fibers & ground substance
- **WBCs** -- wander (mostly in CT) in search of bacteria
 - **Macrophages** – large phagocytic cells-- arise from monocytes (WBC); function? **phagocytosis**
 - **Plasma cells** -- arise from lymphocytes; antibody-producing cells
- **Mast cells** – oval shaped; clustered along blood vessels; secrete heparin and histamine
- **Adipocytes or fat cells** --store triglycerides

-Connective tissue

A. Fibrous CT

Five Types of Fibrous C.T.

Divided into 2 broad categories:

- **Loose CT**

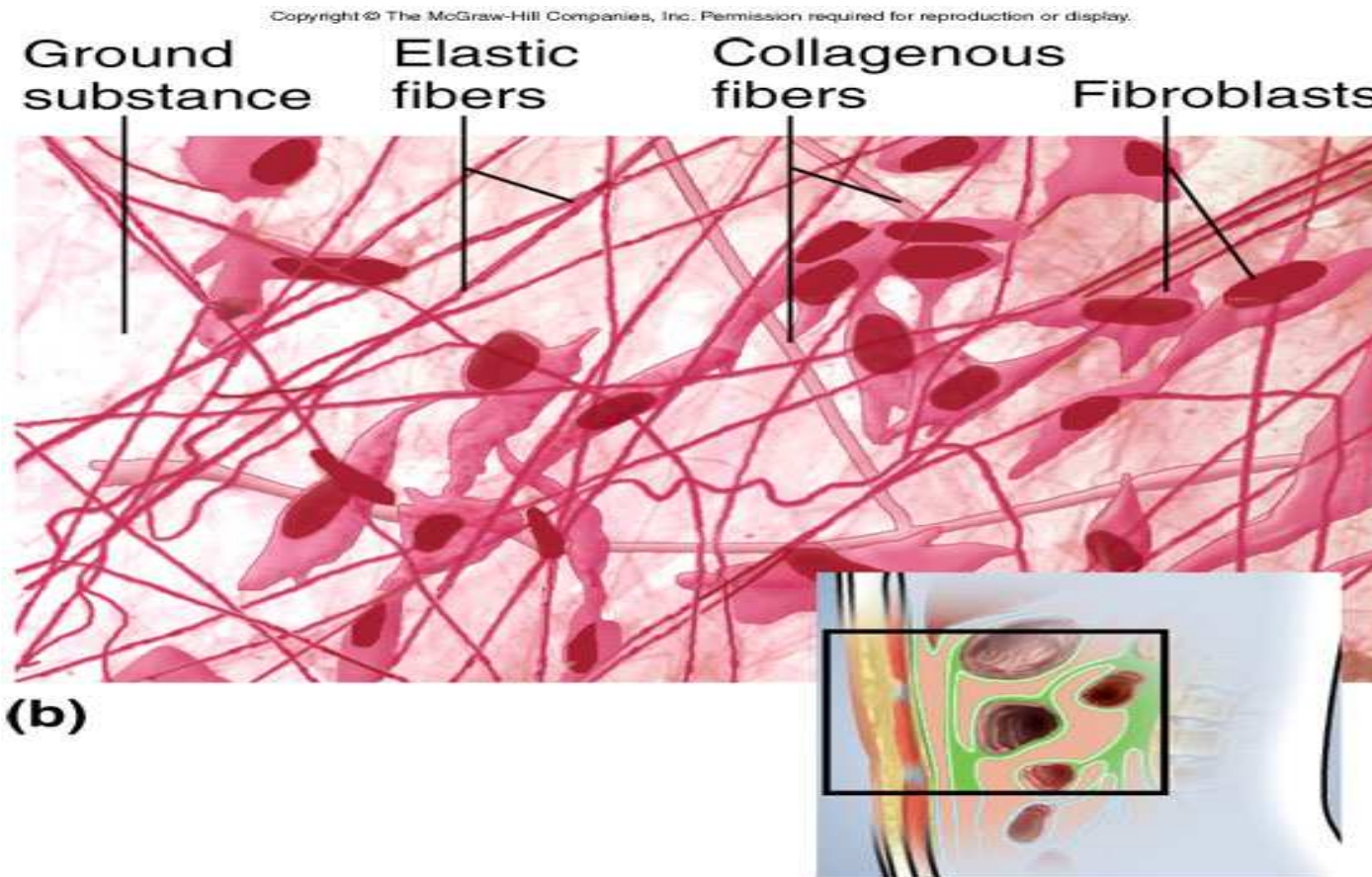
- contains **MORE gel-like ground substance** between cells
- 3 types: **A--areolar, B--reticular, C--adipose tissue**

- **Dense CT**

- **FIBERS** fill the spaces between cells

- 2 types varying in fiber orientation: **D--dense regular, E--dense irregular**

- Areolar Tissue

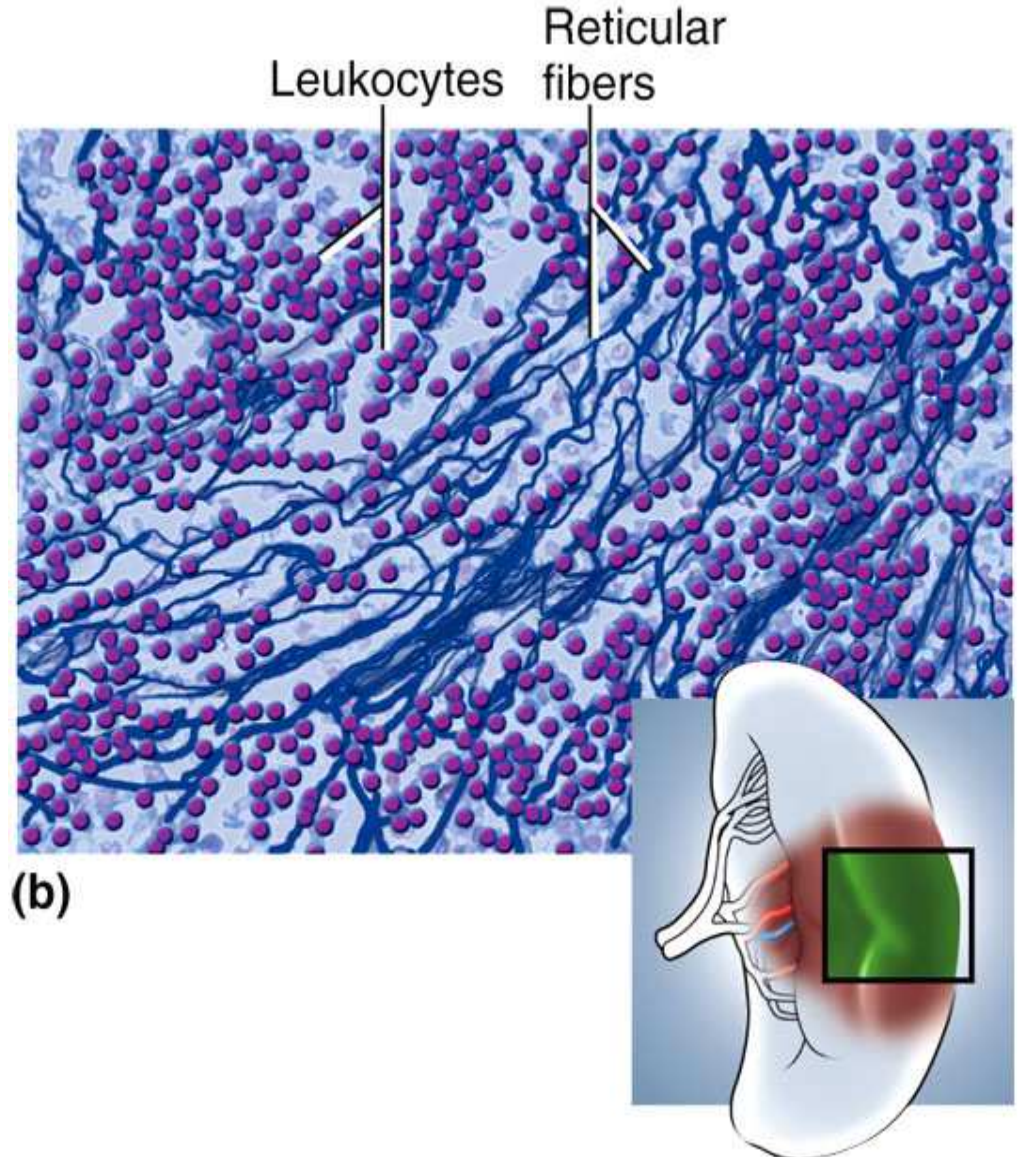


- Loose arrangement of collagenous and elastic fibers; scattered cell types; **abundant ground substance**
- **Locations--** Underlying all epithelia; surrounding nerves, blood vessels, esophagus, trachea

- Reticular Tissue

Copyright © The McGraw-Hill Companies, Inc. Permission required for reproduction or display.

- Forms **structural supportive stroma** for lymphatic organs
- **Locations--** lymph nodes, spleen, thymus & bone marrow



(b)

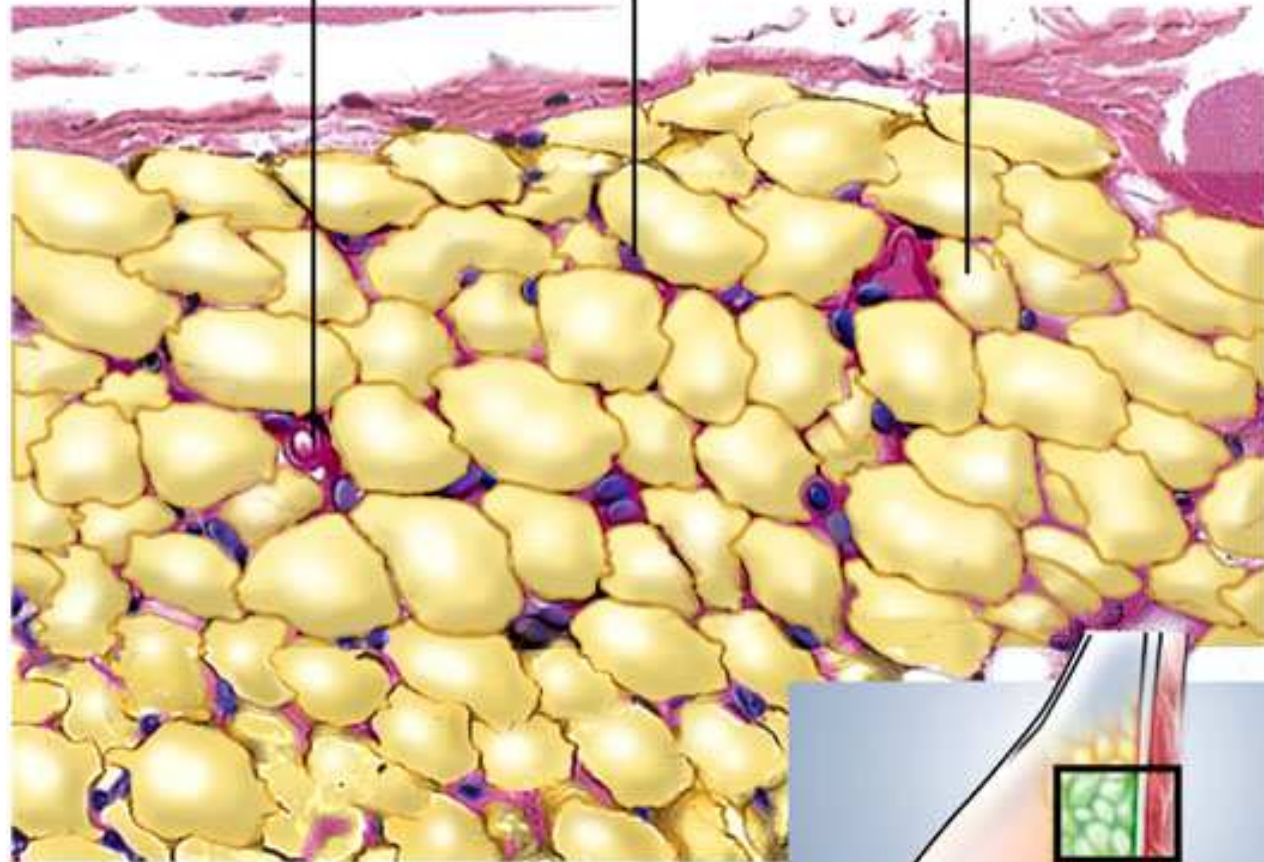
- Adipose Tissue (Fat)

- Large, empty-looking cells dominate with thin margins; nucleus pressed against cell membrane; **often very pale**
- **Functions--** Energy storage, insulation, space filled as cushioning
- **Locations--** Subcutaneous fat beneath skin, breast, heart surface, surrounding organs

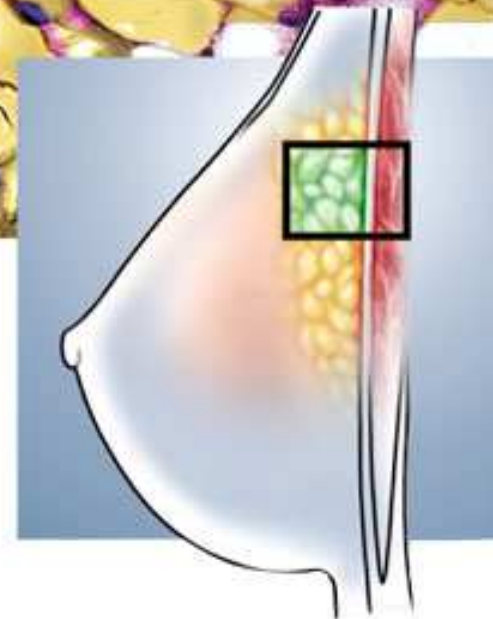
Blood vessel

Adipocyte nucleus

Lipid in adipocyte



(b)

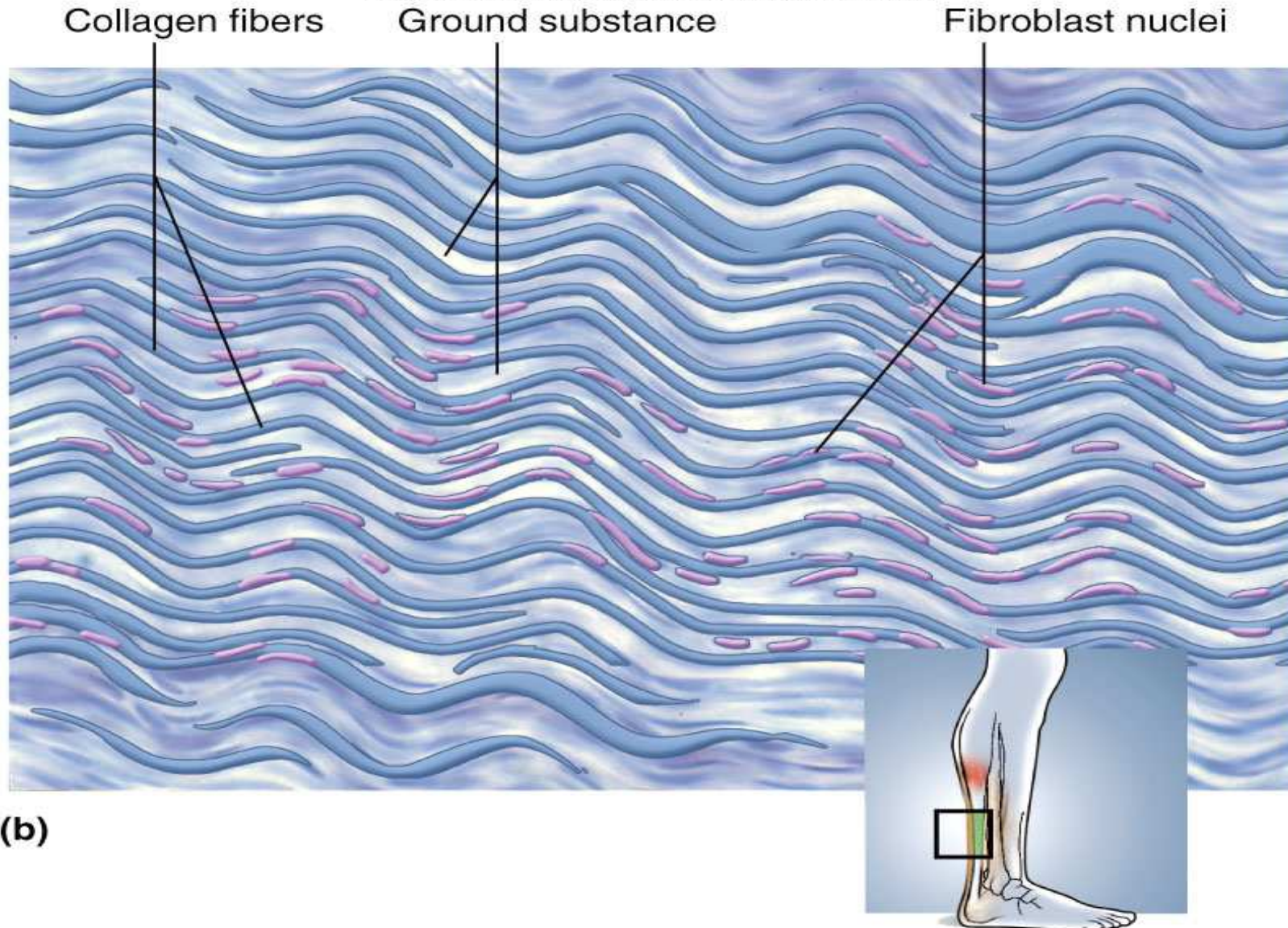


- Dense Regular CT

- Structure-- Mainly densely, **PACKED, PARALLEL FIBERS**; compressed fibroblast nuclei; scanty open space **and blood vessels**
- **Locations--** Tendons & ligaments

- Dense Regular CT

Copyright © The McGraw-Hill Companies, Inc. Permission required for reproduction or display.

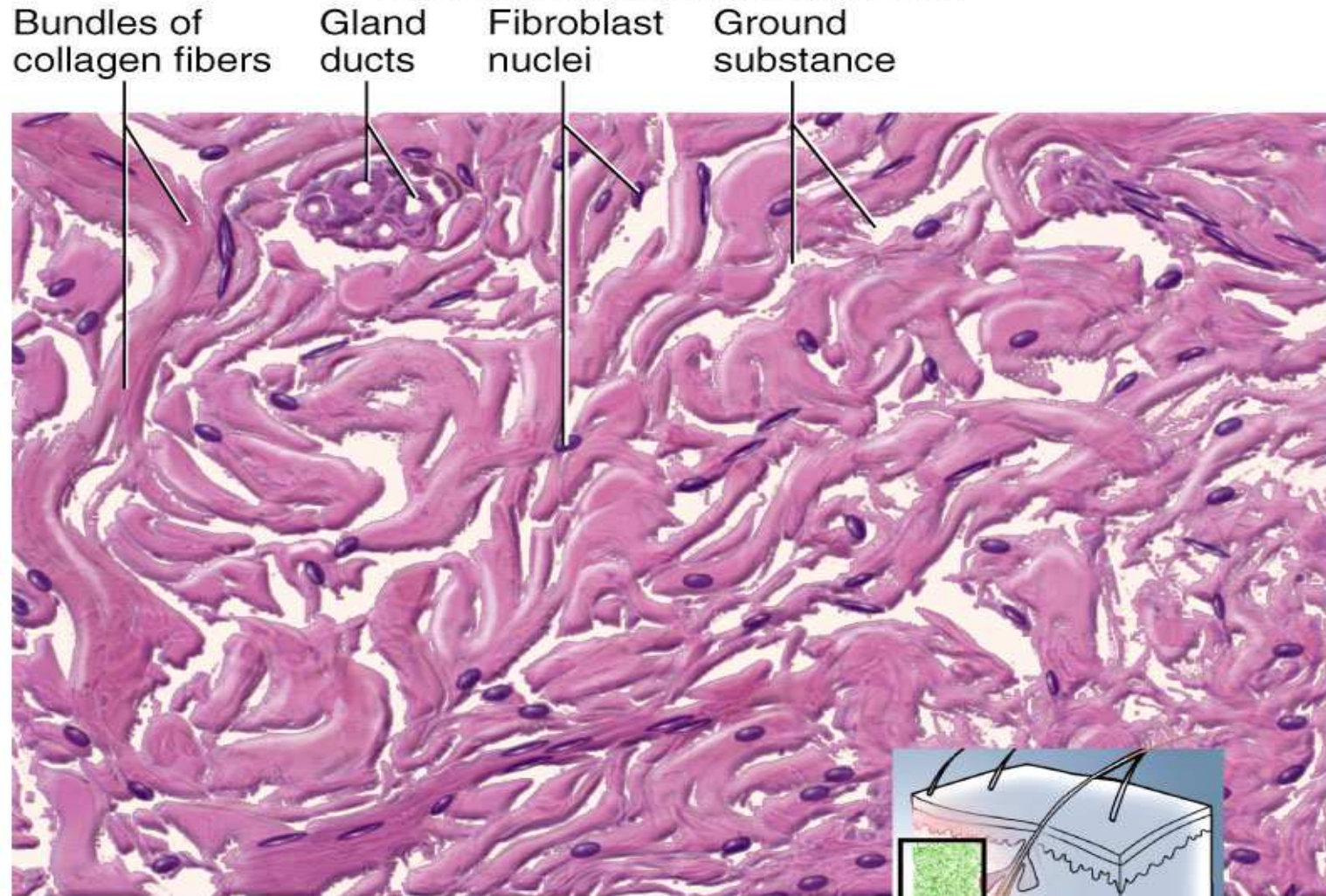


- Dense Irregular CT

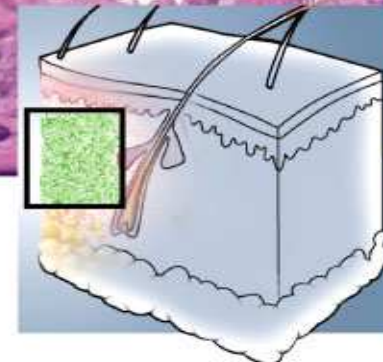
- Densely packed collagen fibers running in **different** directions; scanty open space; few visible cells and blood vessels
- Function-- Withstands stresses applied in **MANY DIFFERENT DIRECTIONS**
- **Locations**-- Deeper portion of skin; capsules around organs (**ex. Liver, kidney etc**); sheaths around cartilages and bones

- Dense Irregular CT

Copyright © The McGraw-Hill Companies, Inc. Permission required for reproduction or display.



(b)



-Connective tissue

B. Cartilage, Bone, Blood

§ Cartilage

- Supportive CT with rubbery matrix
- Chondroblasts produce matrix, surround themselves, and become Chondrocytes
- **No blood vessels**; so diffusion must bring in nutrients & remove wastes;
- 3 types of cartilage depend upon **FIBER TYPES**
 - **A--hyaline, B--elastic, and C--fibrocartilage**

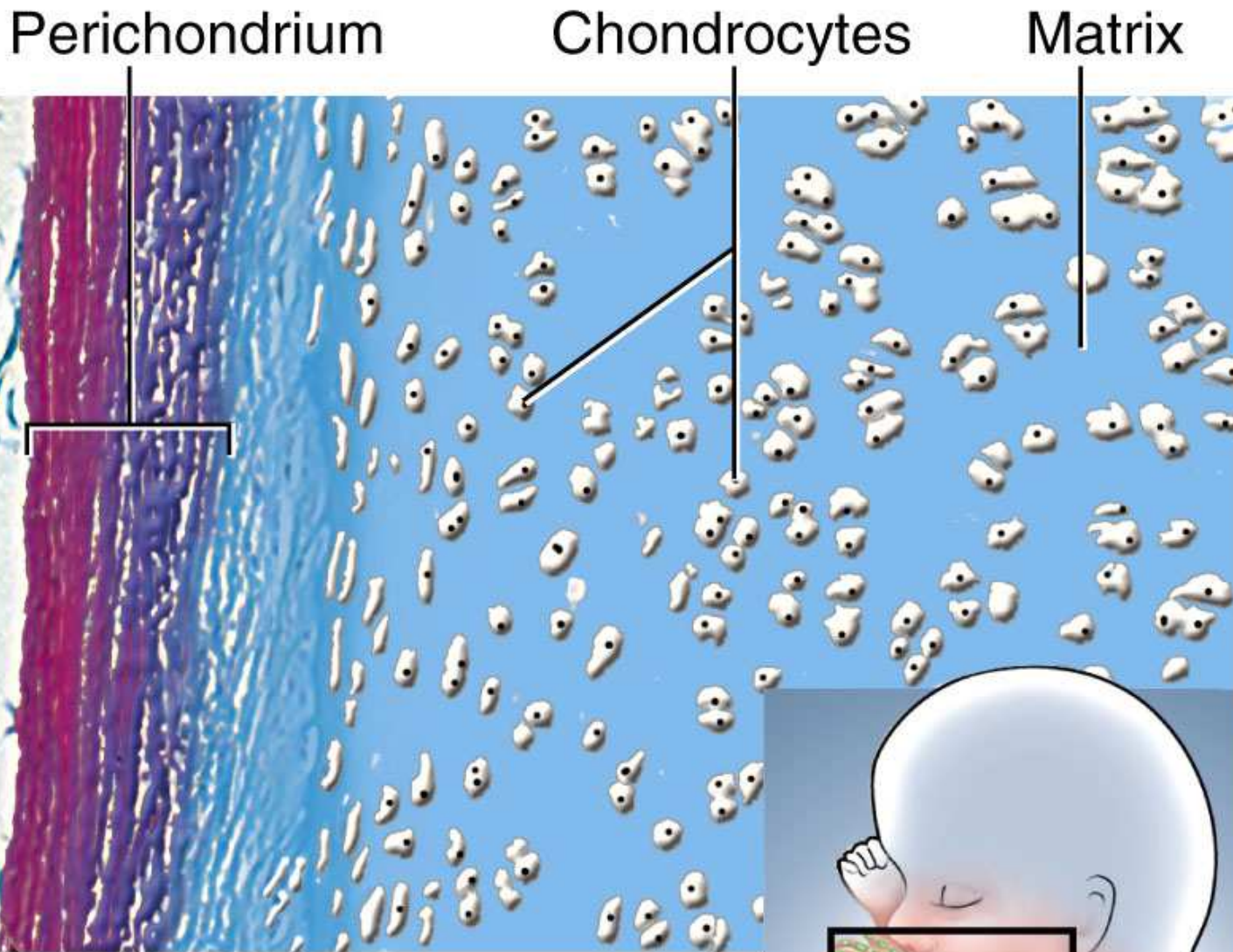


Fig. Fetal skeleton

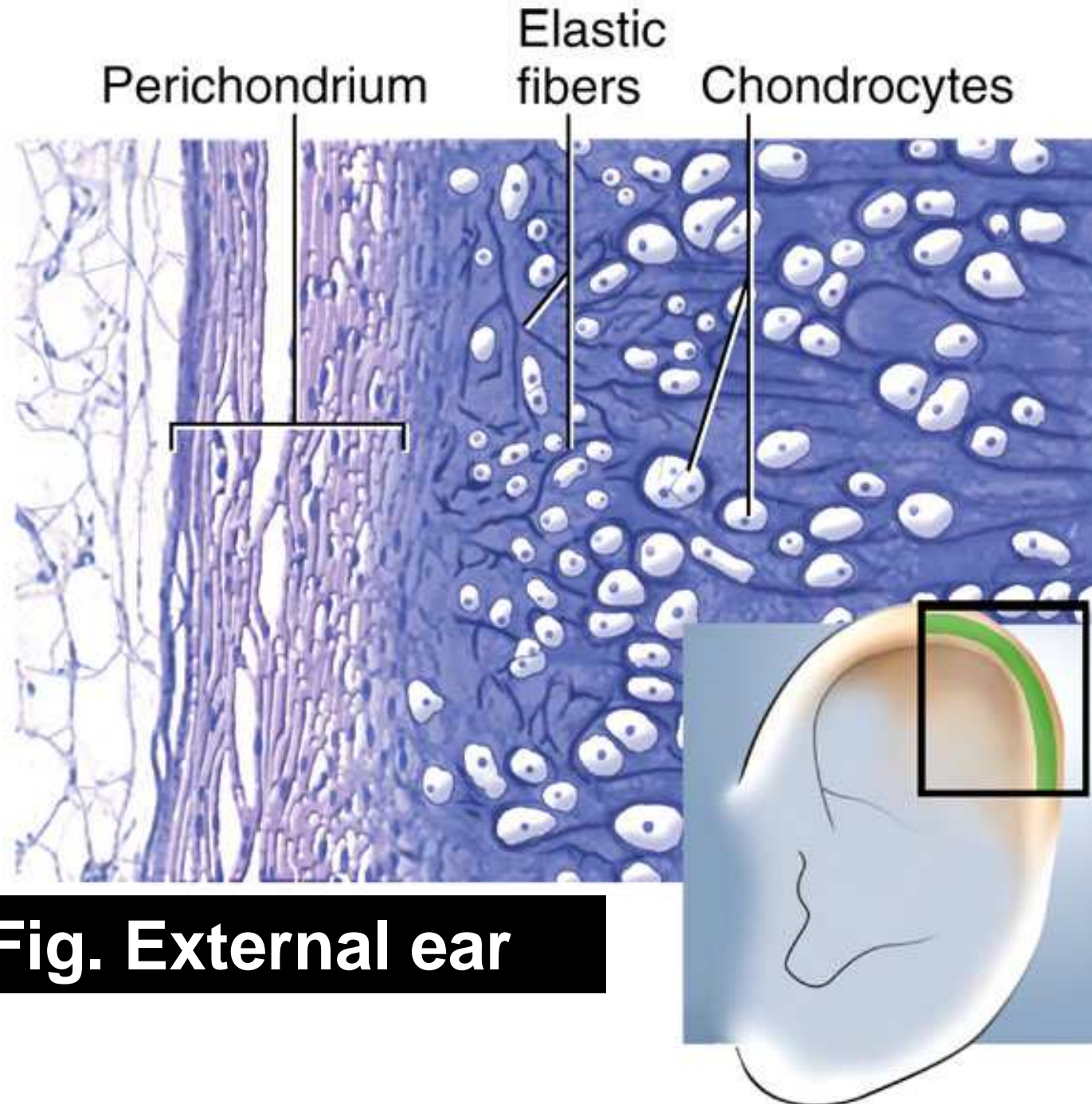


Fig. External ear

Chondrocytes Collagen fibers Lacuna

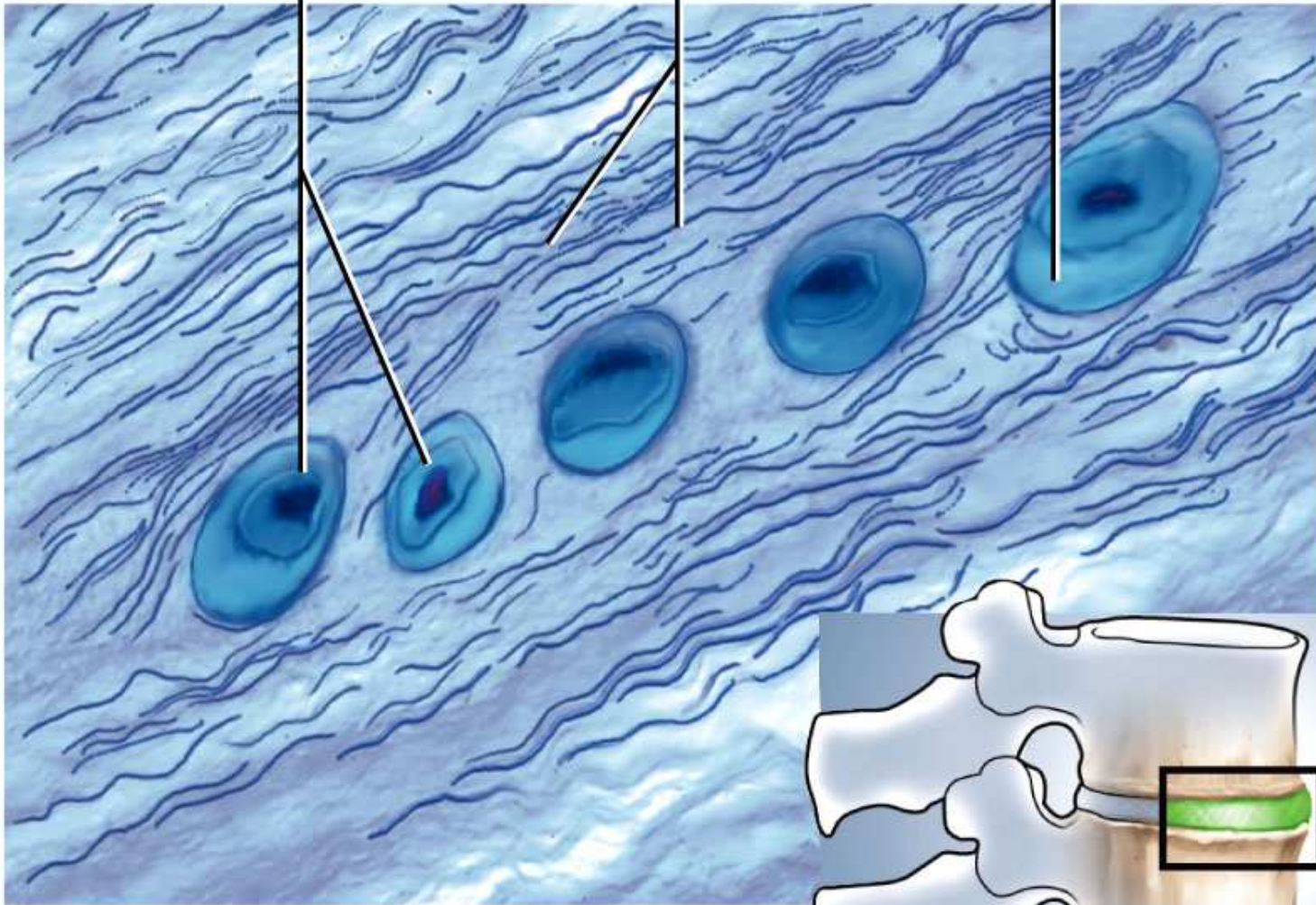


Fig. Intervertebral disc

§ Bone (osseous tissue)

- **Spongy bone** looks spongy in appearance
 - fills **heads** of long bones
 - delicate struts of bone
 - ALWAYS COVERED BY COMPACT BONE
- **Compact (dense) bone** looks solid
 - No space visible to the naked eye
 - External surfaces of ALL bones

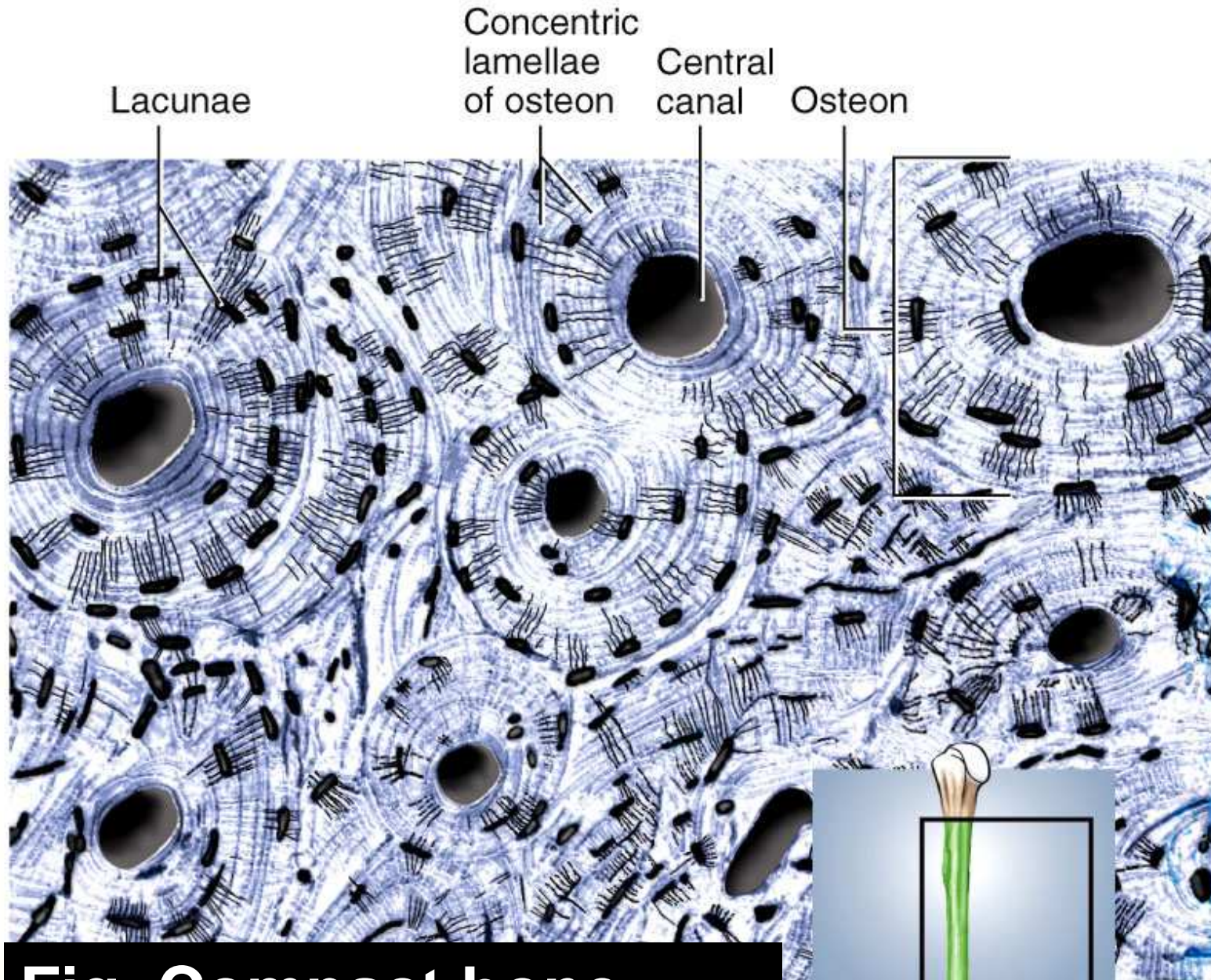
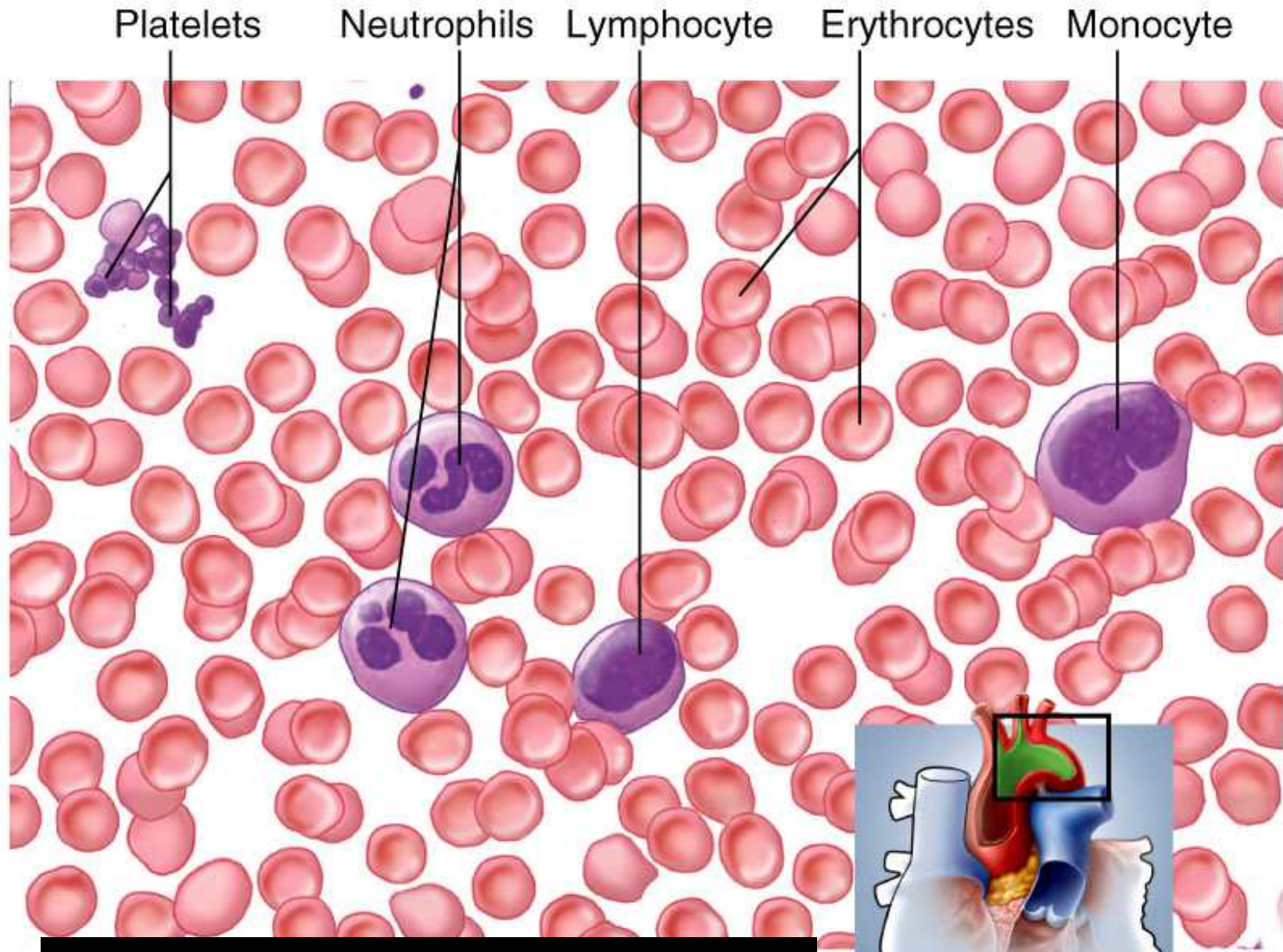


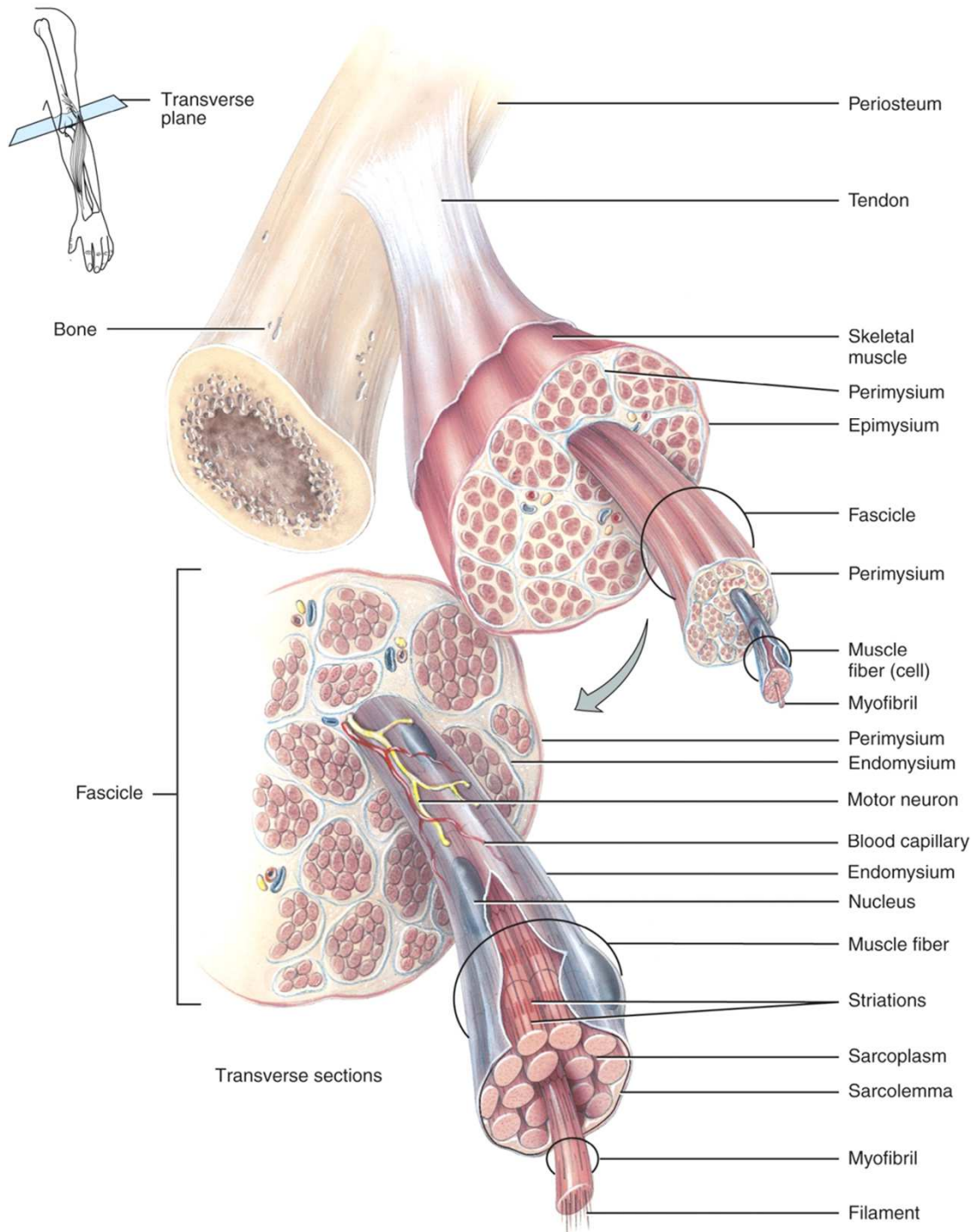
Fig. Compact bone

§ Blood

- Variety of cells and cell fragments; some with nuclei & some without
- RBC, WBC, platelets
- Found in heart and blood vessels



(b) **Fig. Blood smear**

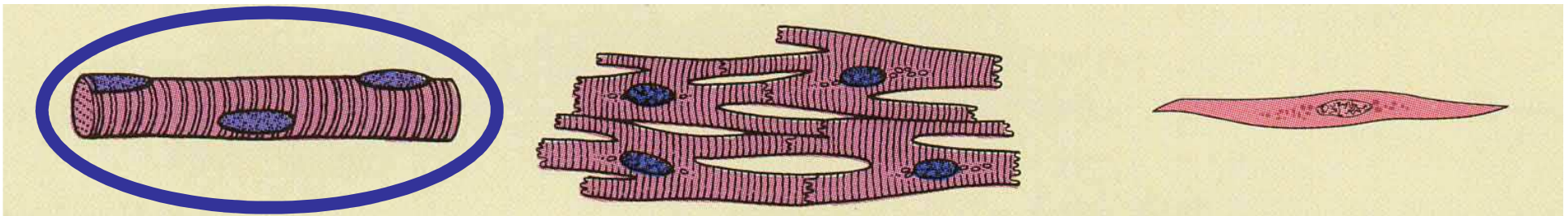


Muscular Tissue

- Alternating contraction and relaxation of cells
- Chemical energy changed into mechanical energy

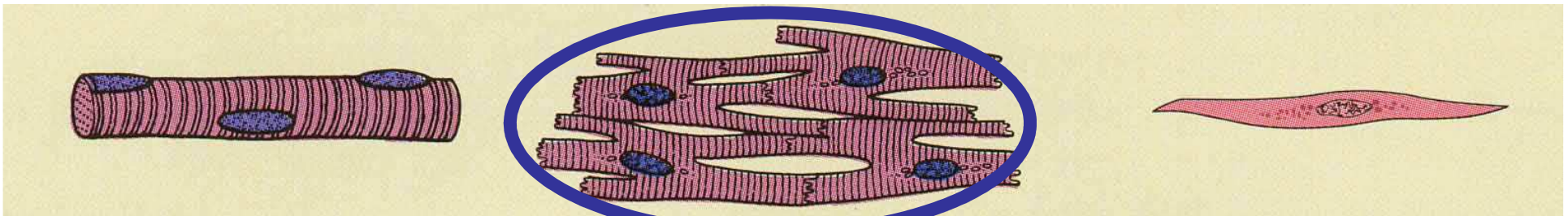
3 Types of Muscle Tissue

- Skeletal muscle
 - attaches to bone, skin or fascia
 - striated with light & dark bands visible with scope
 - voluntary control of contraction & relaxation



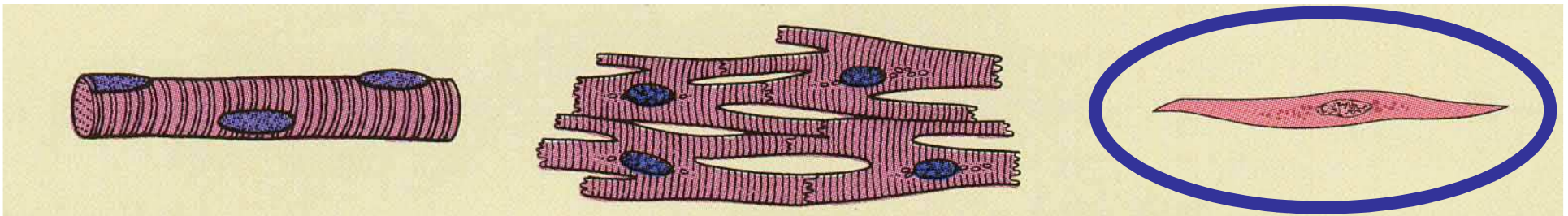
3 Types of Muscle Tissue

- Cardiac muscle
 - striated in appearance
 - involuntary control
 - autorhythmic because of built in pacemaker



3 Types of Muscle Tissue

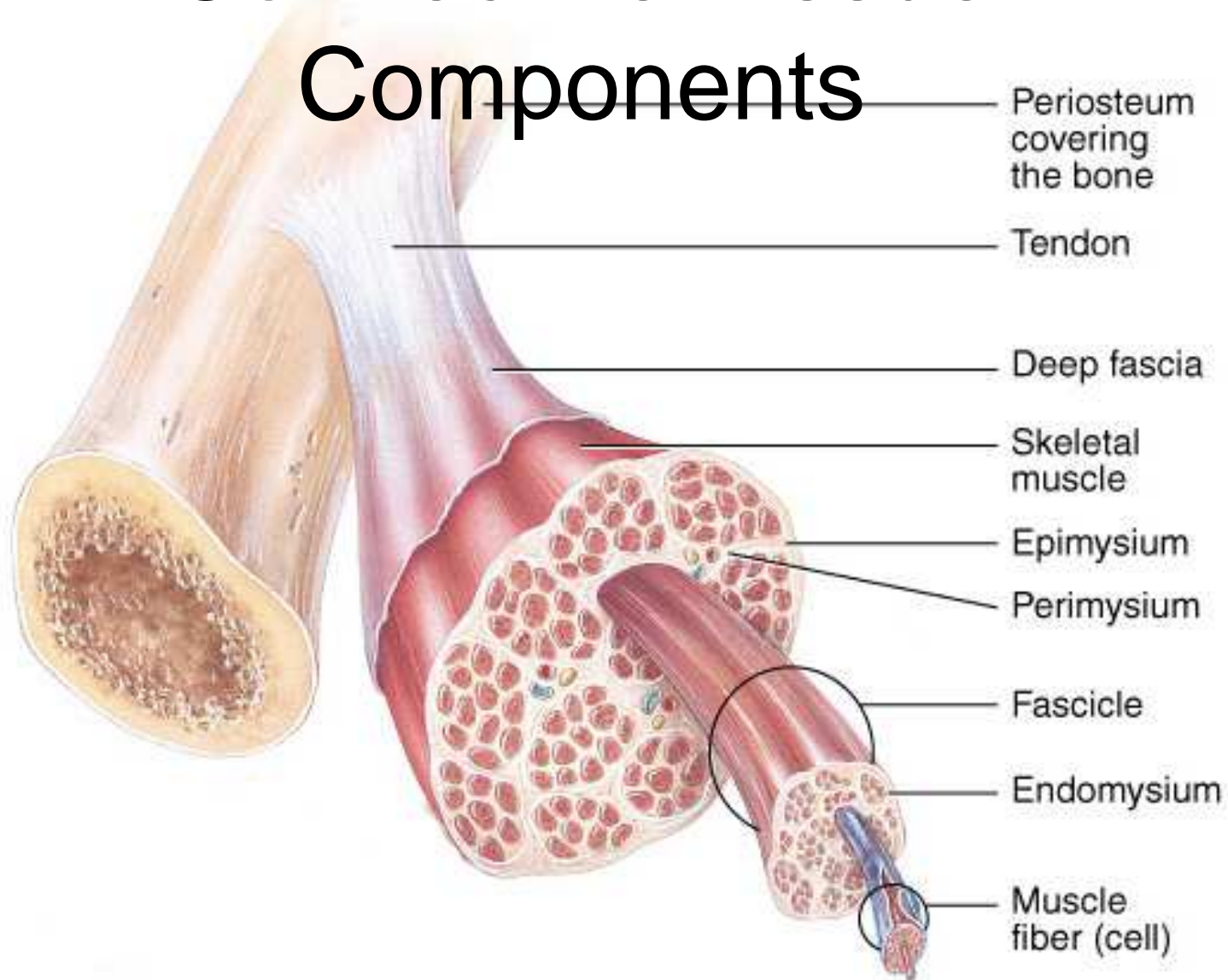
- Smooth muscle
 - attached to hair follicles in skin
 - in walls of hollow organs -- blood vessels & GI
 - nonstriated in appearance
 - involuntary

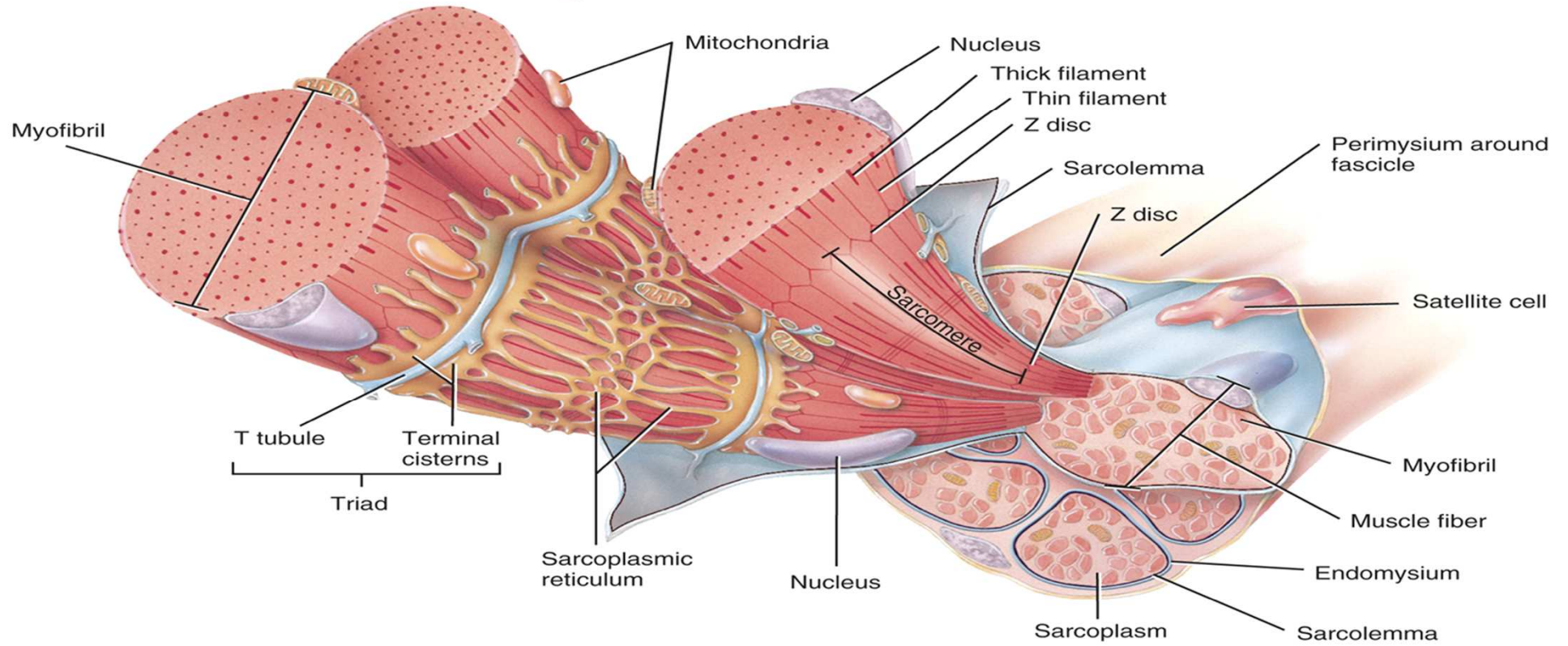
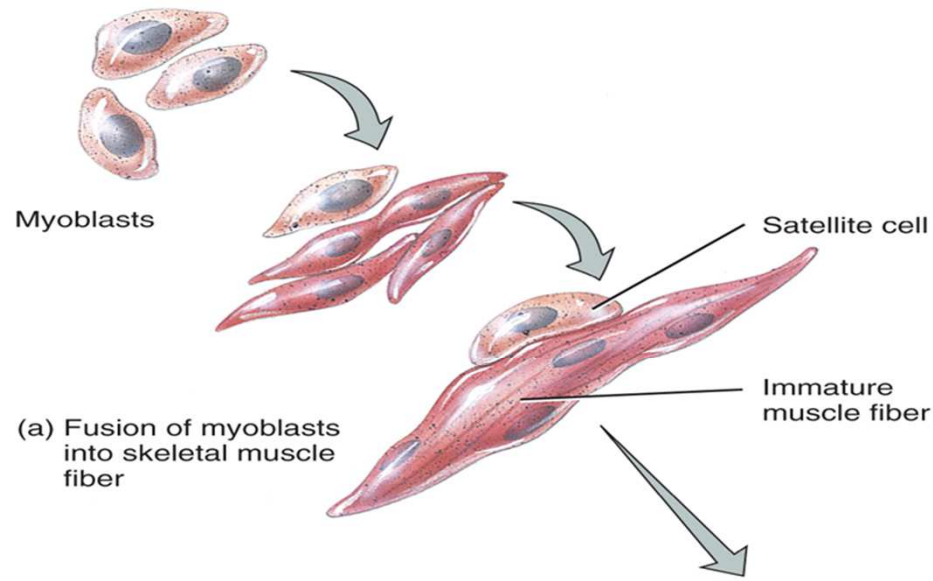


Functions of Muscle Tissue

- Producing body movements
- Stabilizing body positions
- Regulating organ volumes
 - bands of smooth muscle called sphincters
- Movement of substances within the body
 - blood, lymph, urine, air, food and fluids, sperm
- Producing heat
 - involuntary contractions of skeletal muscle (shivering)

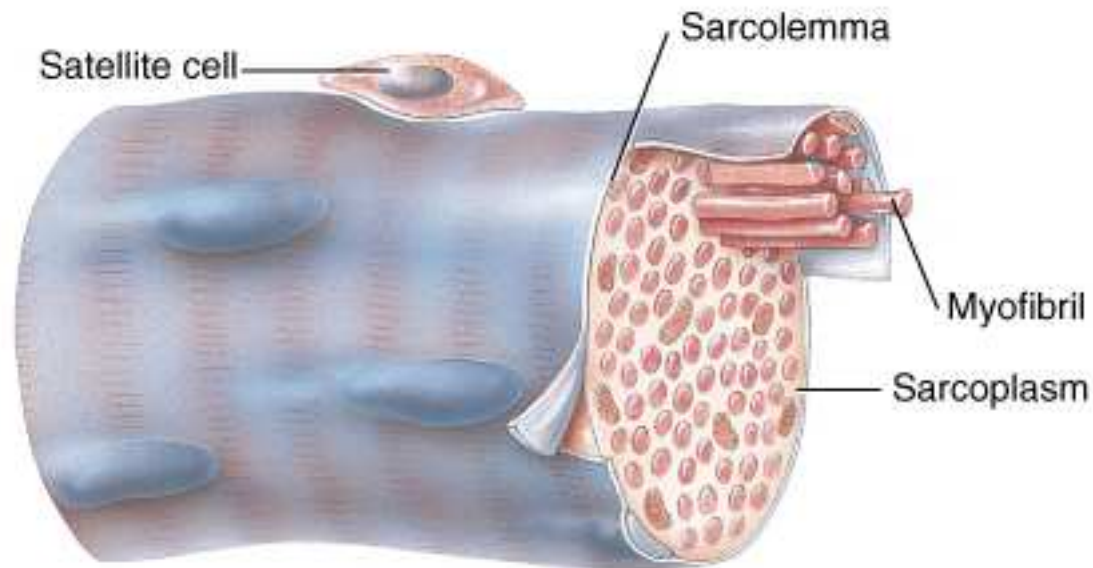
Connective Tissue Components





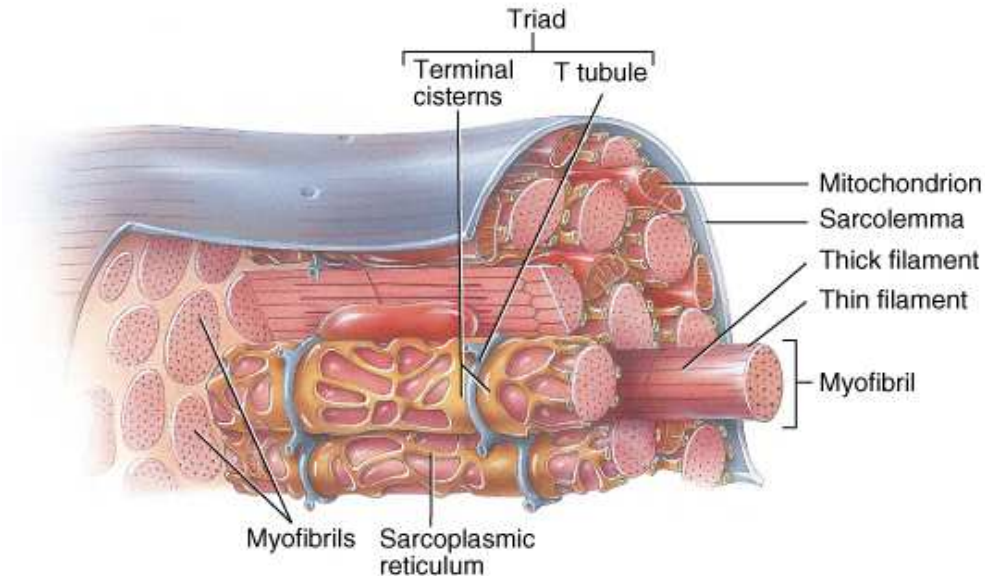
(b) Details of several myofibrils in a muscle fiber

Muscle Fiber or Myofibers



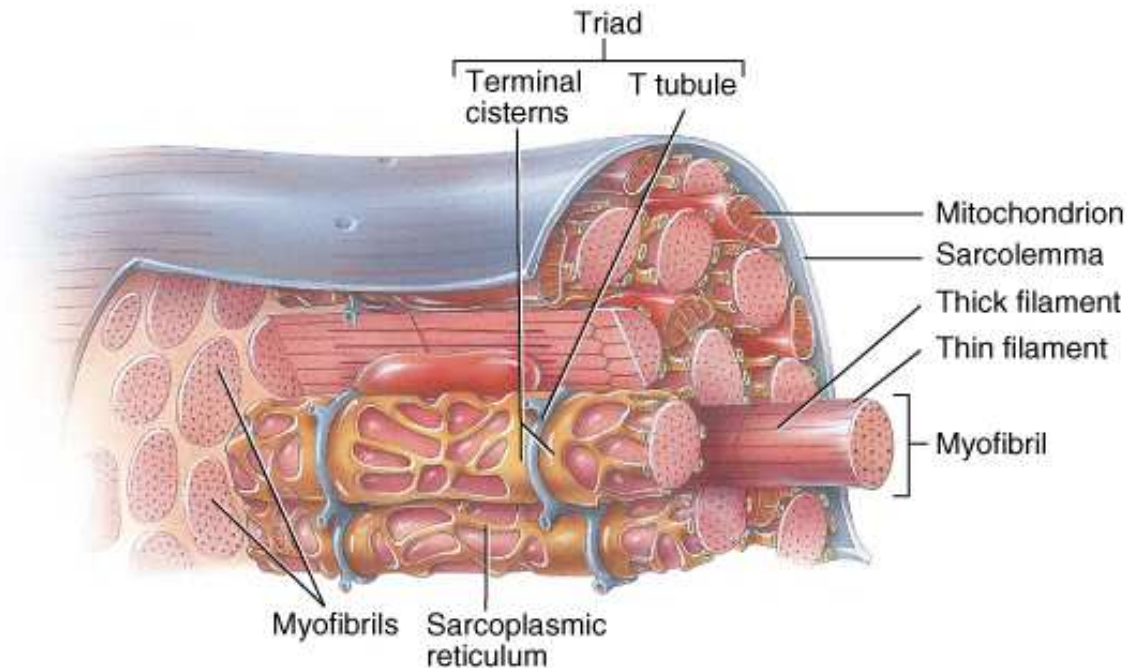
- Muscle cells are long, cylindrical & multinucleated
- Sarcolemma = muscle cell membrane
- Sarcoplasm filled with tiny threads called myofibrils & myoglobin (red-colored, oxygen-binding protein)

Transverse Tubules



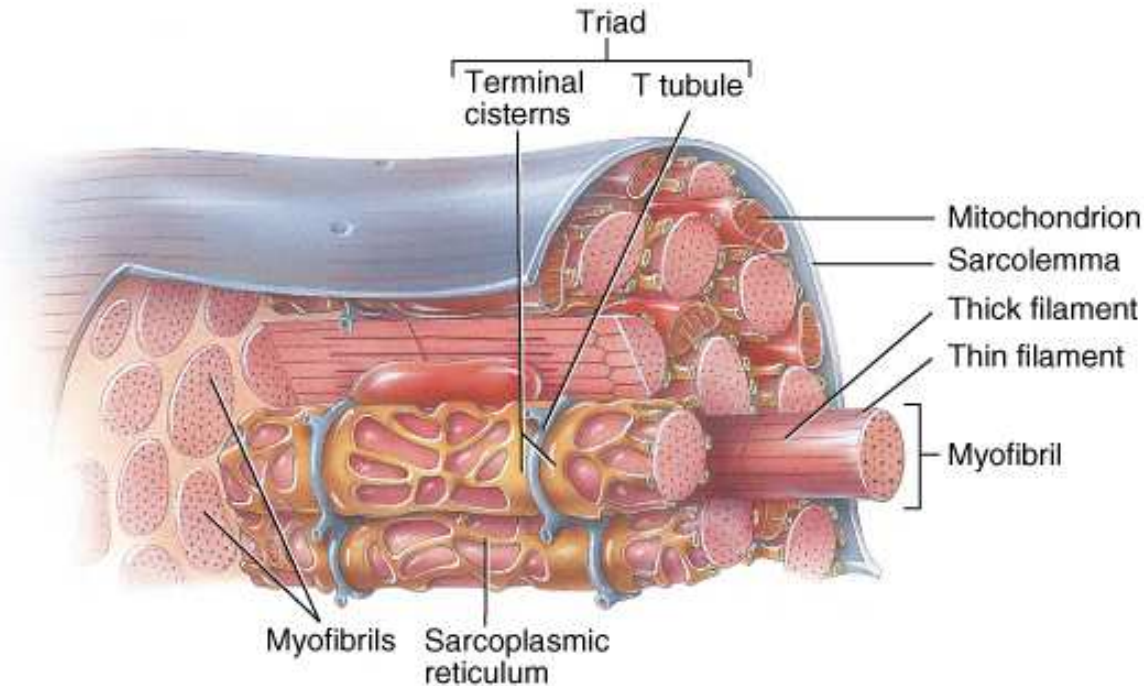
- T (transverse) tubules are invaginations of the sarcolemma into the center of the cell
 - filled with extracellular fluid
 - carry muscle action potentials down into cell
- Mitochondria lie in rows throughout the cell
 - near the muscle proteins that use ATP during contraction

Myofibrils & Myofilaments



- Muscle fibers are filled with threads called myofibrils separated by SR (sarcoplasmic reticulum)
- Myofilaments (thick & thin filaments) are the contractile proteins of muscle

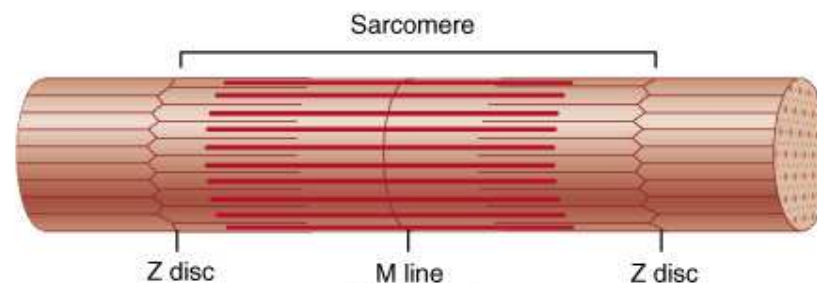
Sarcoplasmic Reticulum (SR)



- System of tubular sacs similar to smooth ER in nonmuscle cells
- Stores Ca^{+2} in a relaxed muscle
- Release of Ca^{+2} triggers muscle contraction

Filaments and the Sarcomere

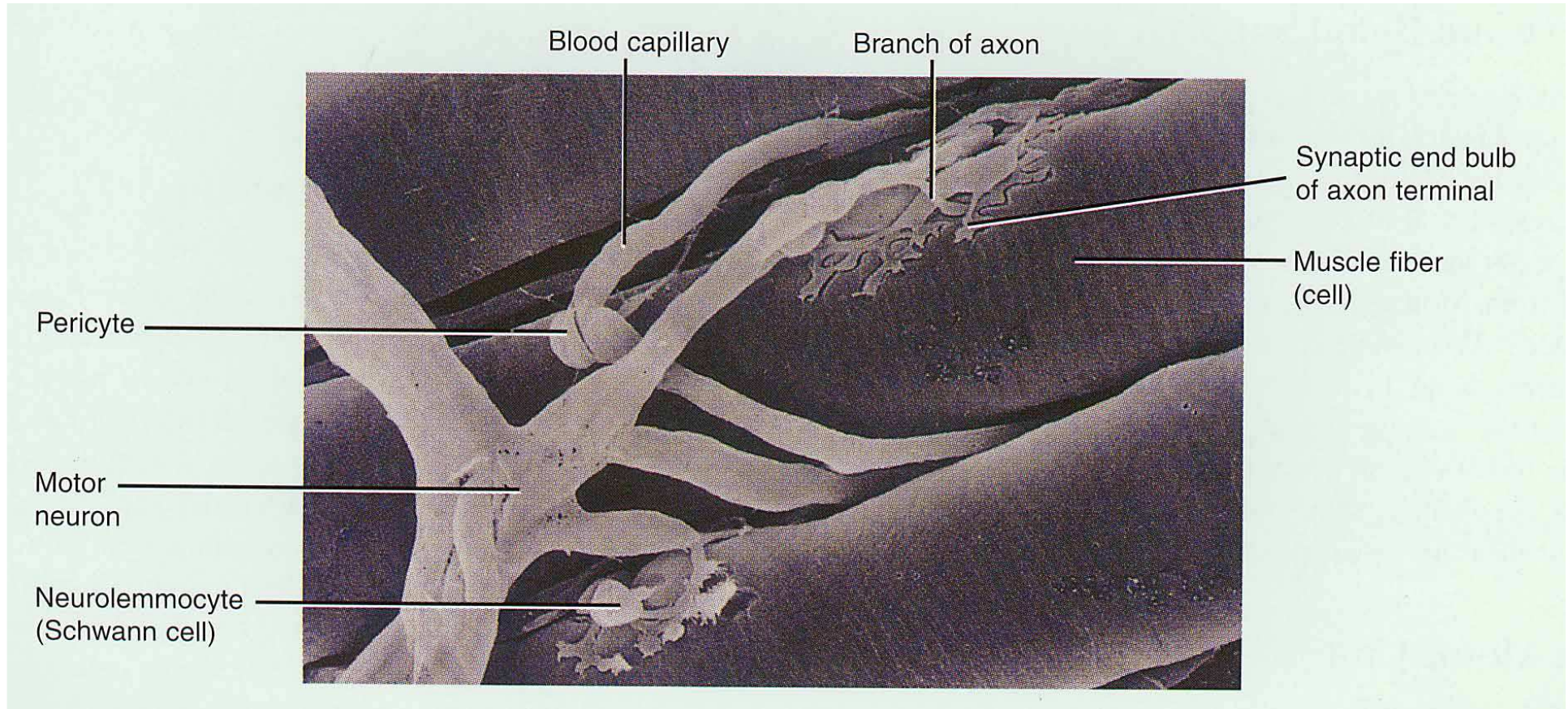
- Thick and thin filaments overlap each other in a pattern that creates striations (light I bands and dark A bands)
- They are arranged in compartments called sarcomeres, separated by Z discs.
- In the overlap region, six thin filaments surround each thick filament



Rigor Mortis

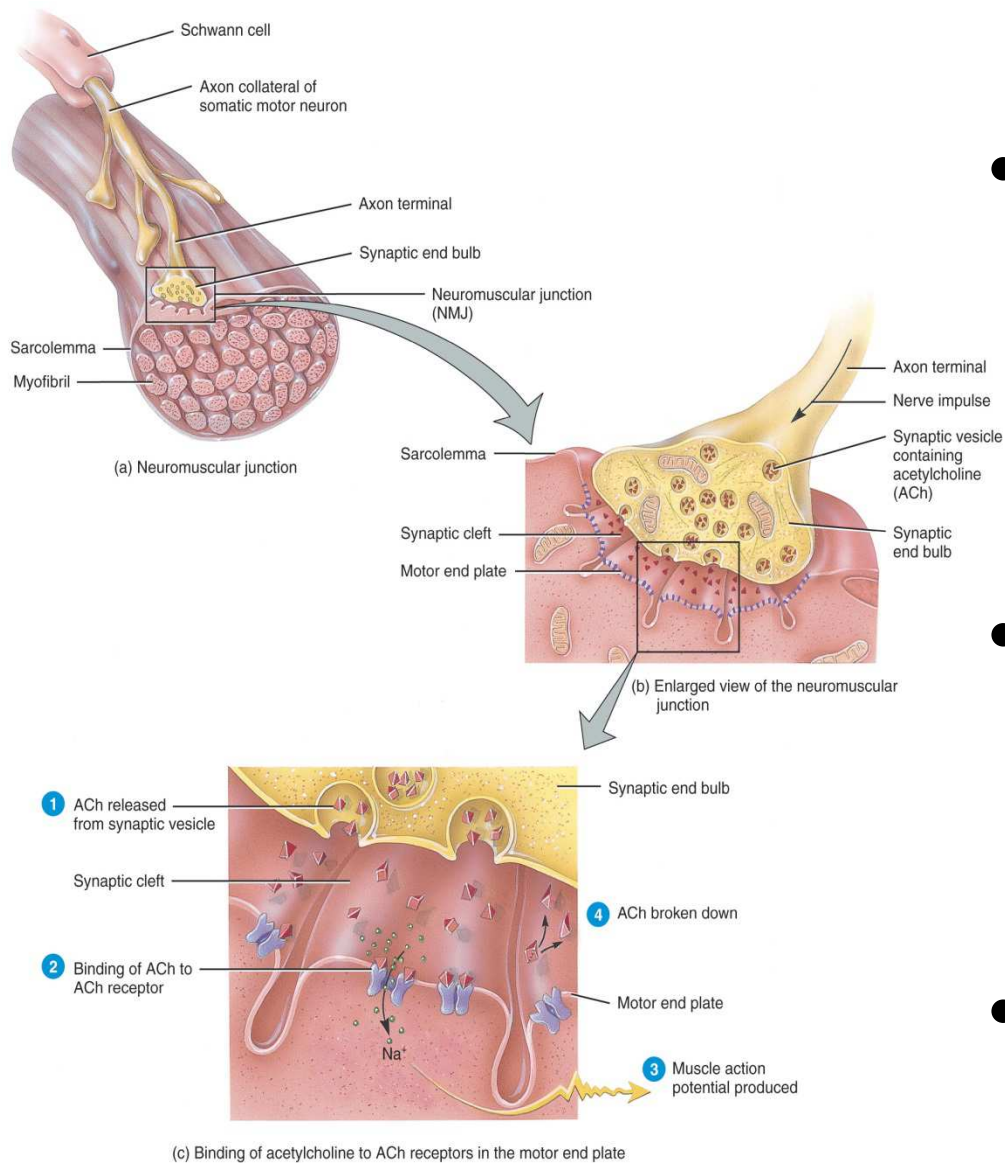
- Rigor mortis is a state of muscular rigidity that begins 3-4 hours after death and lasts about 24 hours
- After death, Ca^{+2} ions leak out of the SR and allow myosin heads to bind to actin
- Since ATP synthesis has ceased, crossbridges cannot detach from actin until proteolytic enzymes begin to digest the decomposing cells.

Neuromuscular Junction (NMJ) or Synapse



- **NMJ = myoneural junction**
 - **end of axon nears the surface of a muscle fiber at its motor end plate region (remain separated by synaptic cleft or gap)**

Structures of NMJ Region

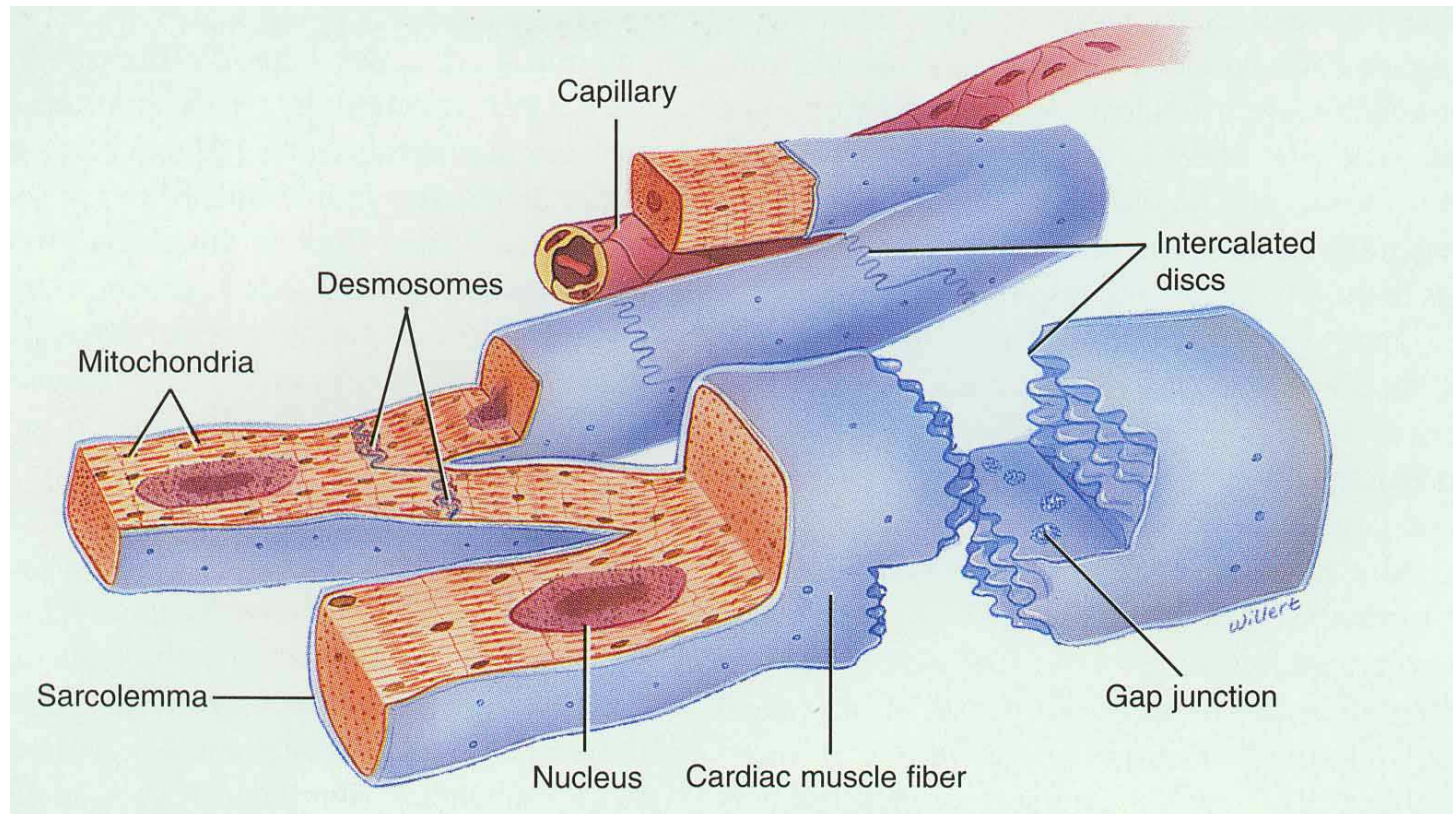


- Synaptic end bulbs are swellings of axon terminals
- End bulbs contain synaptic vesicles filled with acetylcholine (ACh)
- Motor end plate membrane contains 30 million ACh receptors.

Events Occurring After a Nerve Signal

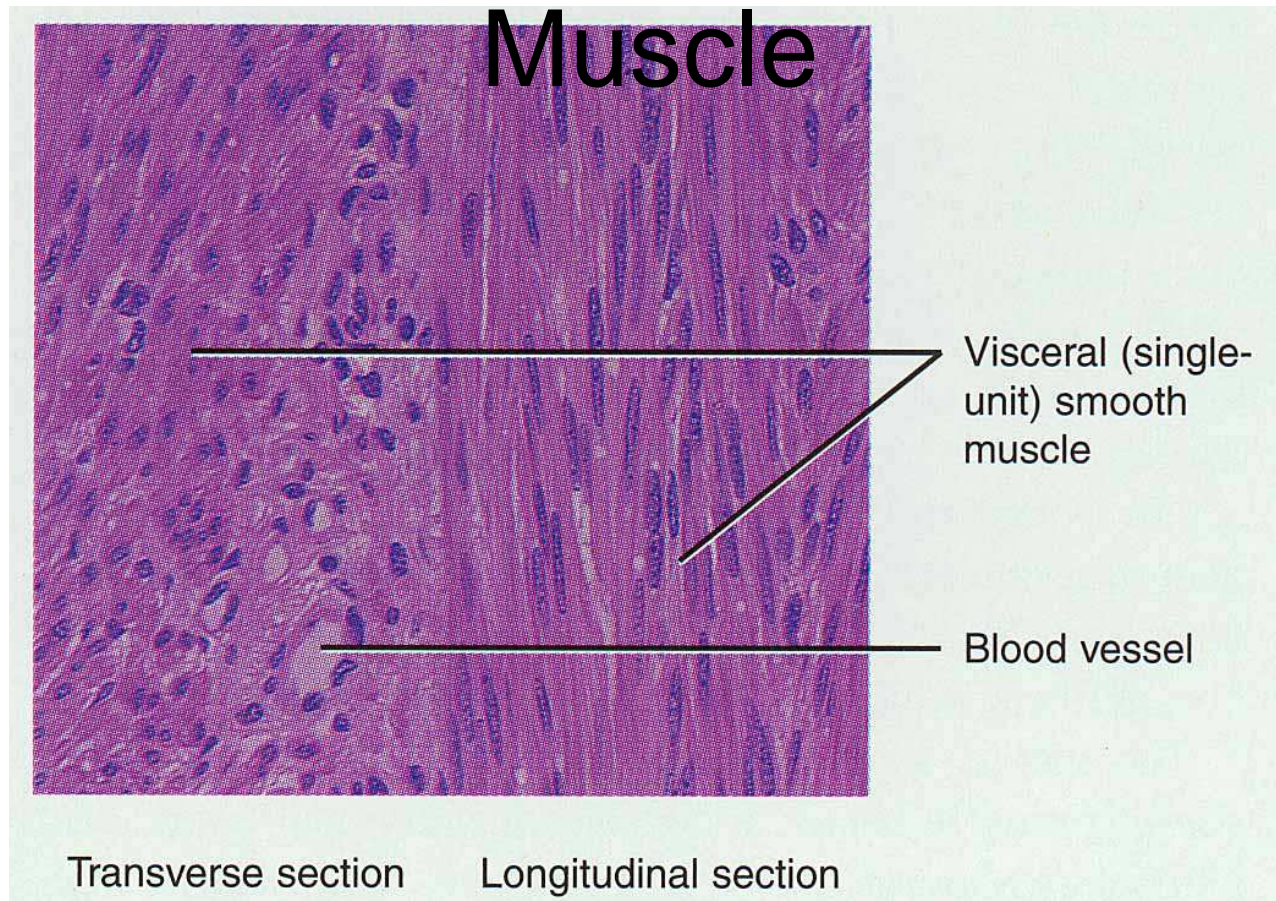
- Arrival of nerve impulse at nerve terminal causes release of ACh from synaptic vesicles
- ACh binds to receptors on muscle motor end plate opening the gated ion channels so that Na^+ can rush into the muscle cell
- Inside of muscle cell becomes more positive, triggering a muscle action potential that travels over the cell and down the T tubules
- The release of Ca^{+2} from the SR is triggered and the muscle cell will shorten & generate force
- Acetylcholinesterase breaks down the ACh attached to the receptors on the motor end plate so the muscle action potential will cease and the muscle cell will relax.

Anatomy of Cardiac Muscle



- Striated , short, quadrangular-shaped, branching fibers
- Single centrally located nucleus
- Cells connected by intercalated discs with gap junctions
- Same arrangement of thick & thin filaments as skeletal

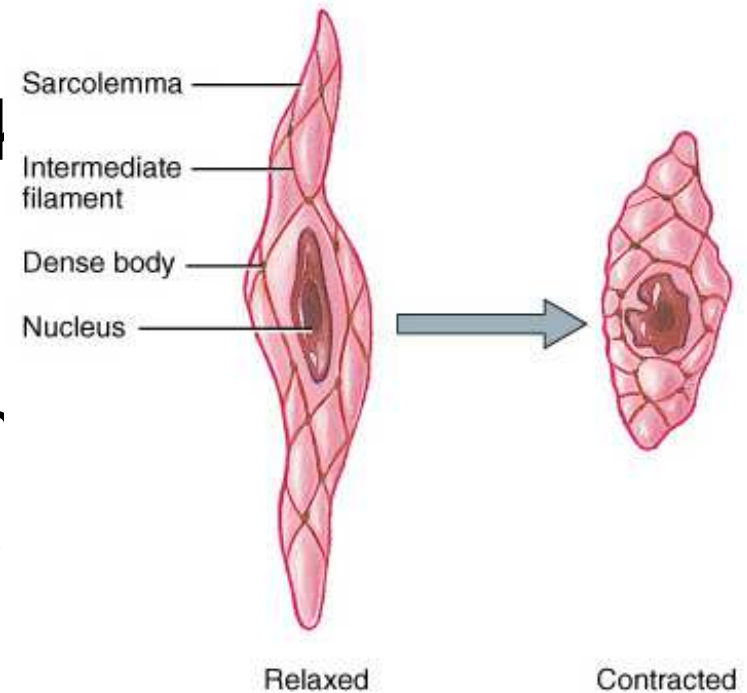
Microscopic Anatomy of Smooth Muscle



- Small, involuntary muscle cell -- tapering at ends
- Single, oval, centrally located nucleus
- Lack T tubules & have little SR for Ca^{+2} storage

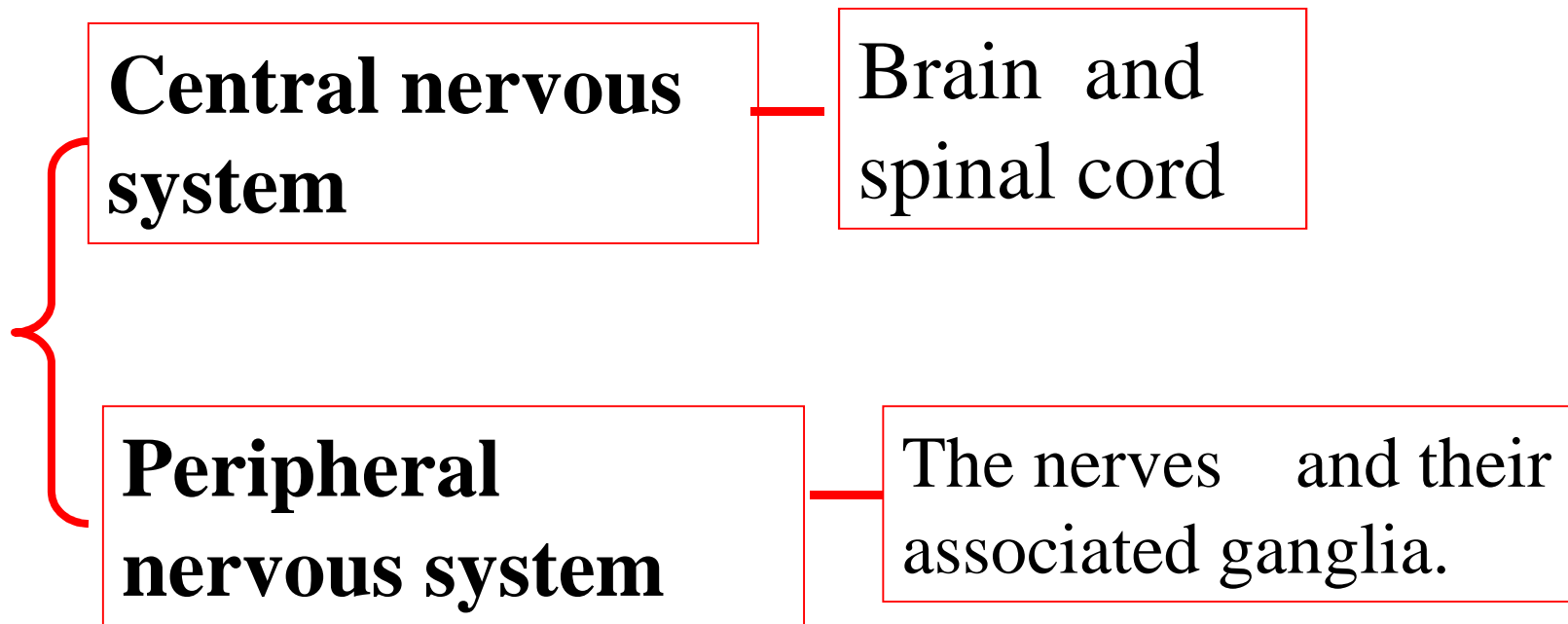
Microscopic Anatomy of Smooth Muscle

- Thick & thin myofilaments not orderly arranged so lack sarcomeres
- Sliding of thick & thin filaments generates tension
- Transferred to intermediate filaments & dense bodies attached to sarcolemma
- Muscle fiber contracts and twists into a helix as it shortens -- relaxes by untwisting

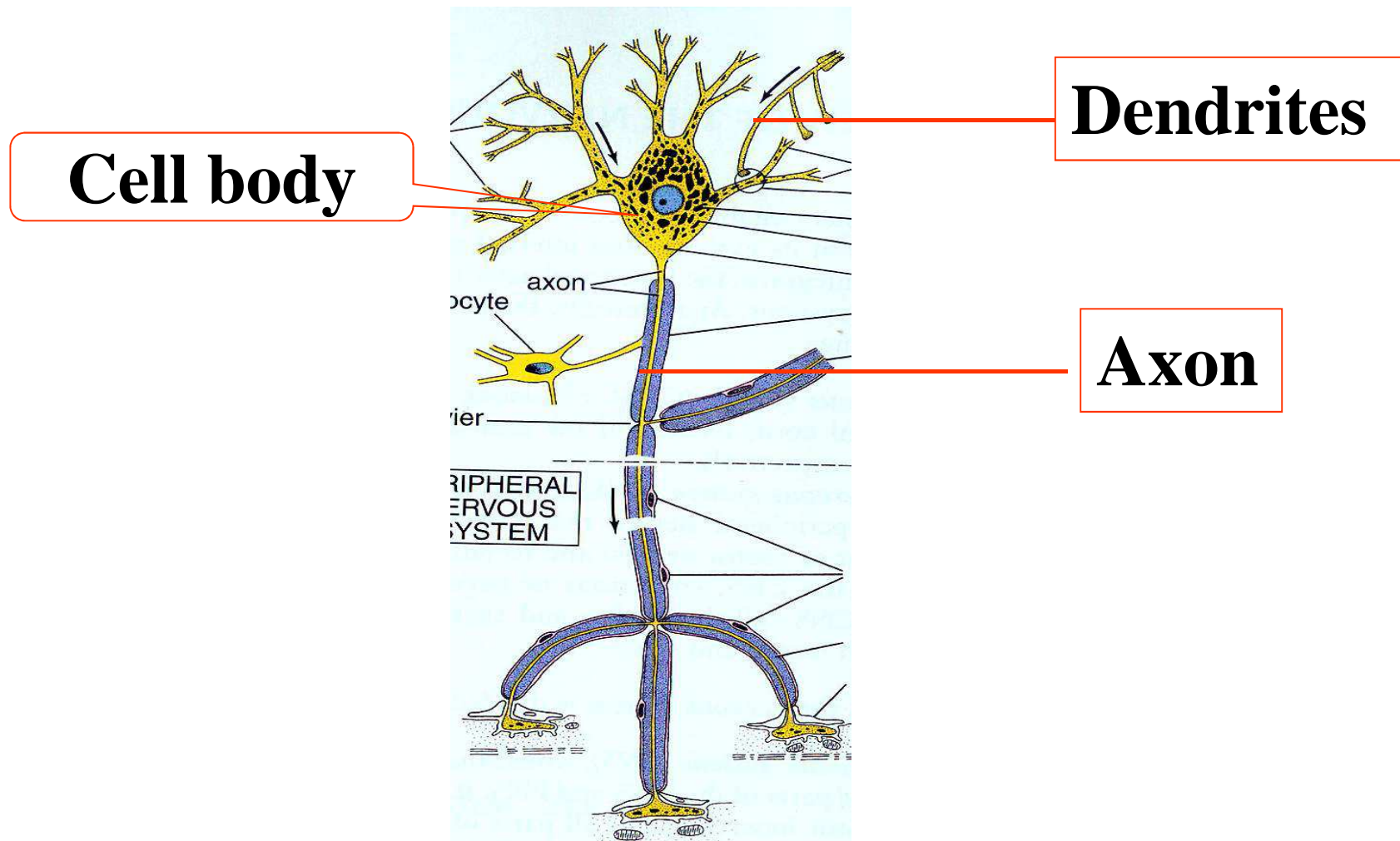


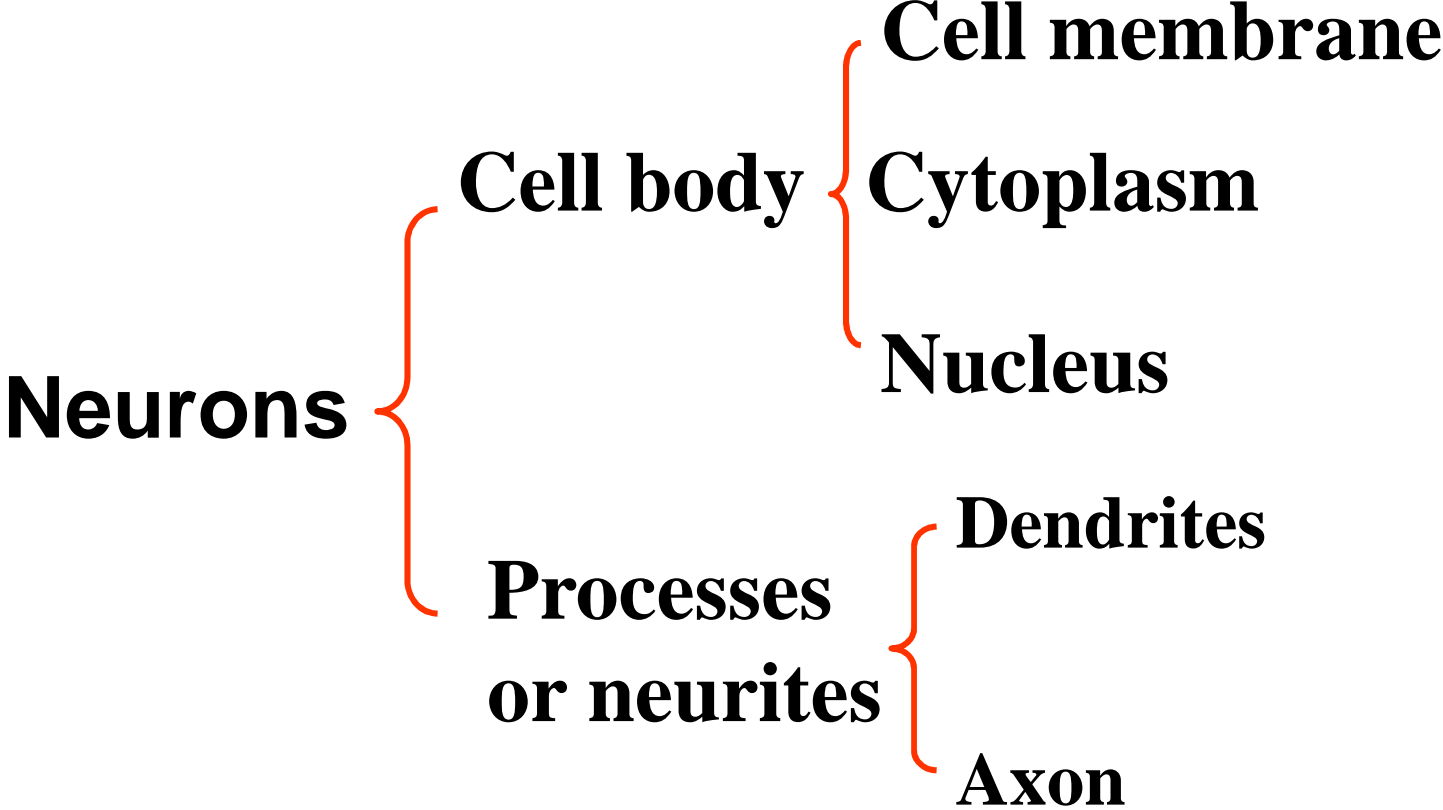
Nervous tissue

Nervous system



1. Microstructure of neuron





Cell body: Perikaryon

The cell body, soma, is the part of neuron that contains nucleus and surrounding cytoplasm, also called perikaryon. It is the trophic center of the neuron. The protein and enzymes synthesis in this area.

Where is cell body

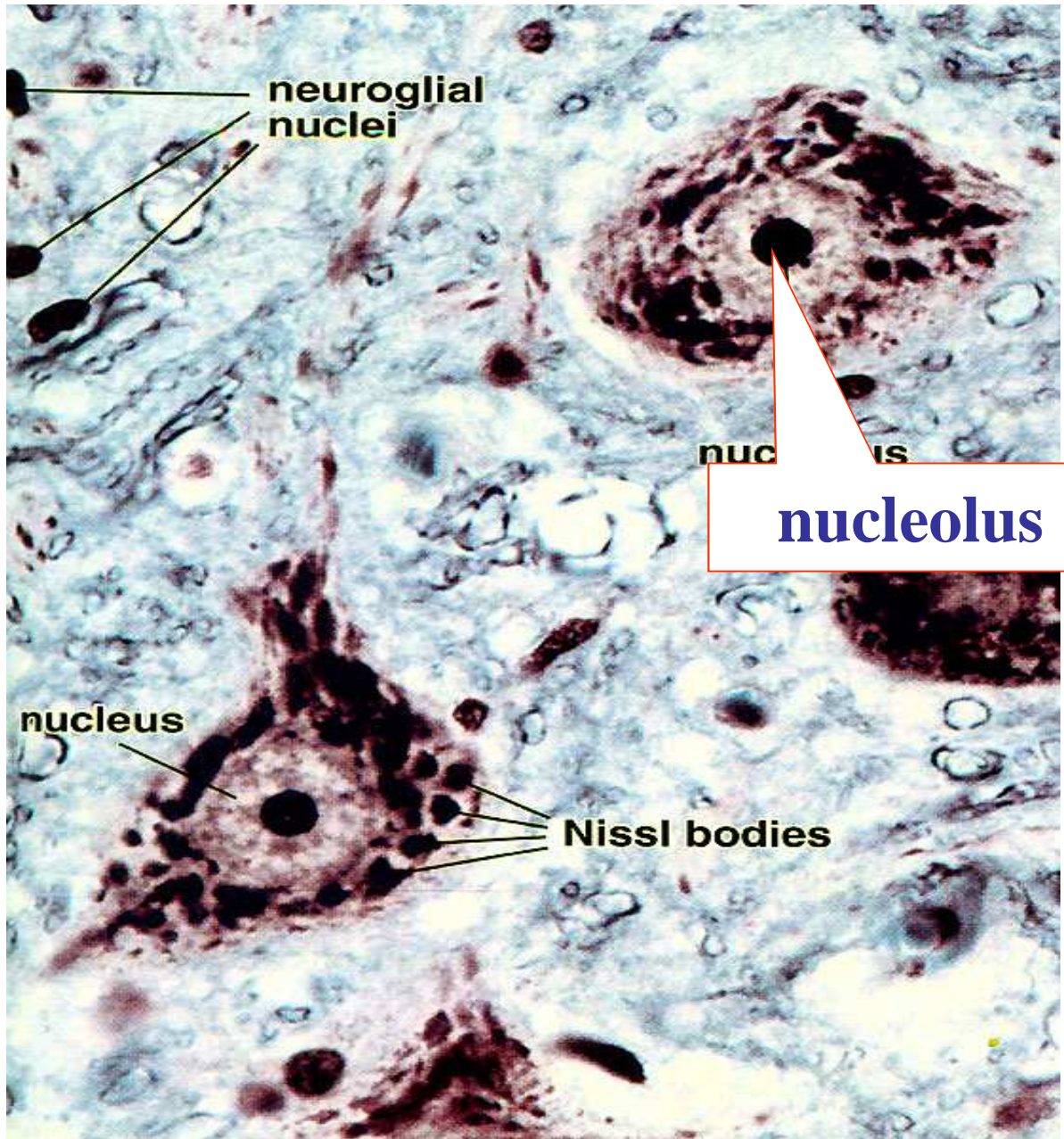
Cell body: Perikaryon

- **Position:** only in grey matter in CNS which also contains dendrites and axons starting from or ending on the cell bodies, ganglia in PNS
- **Shape:** They can be pyramidal, spherical, ovoid or pear-shaped.
- **Size:** Measuring 5-150 μm in diameter.

Microscopic examination

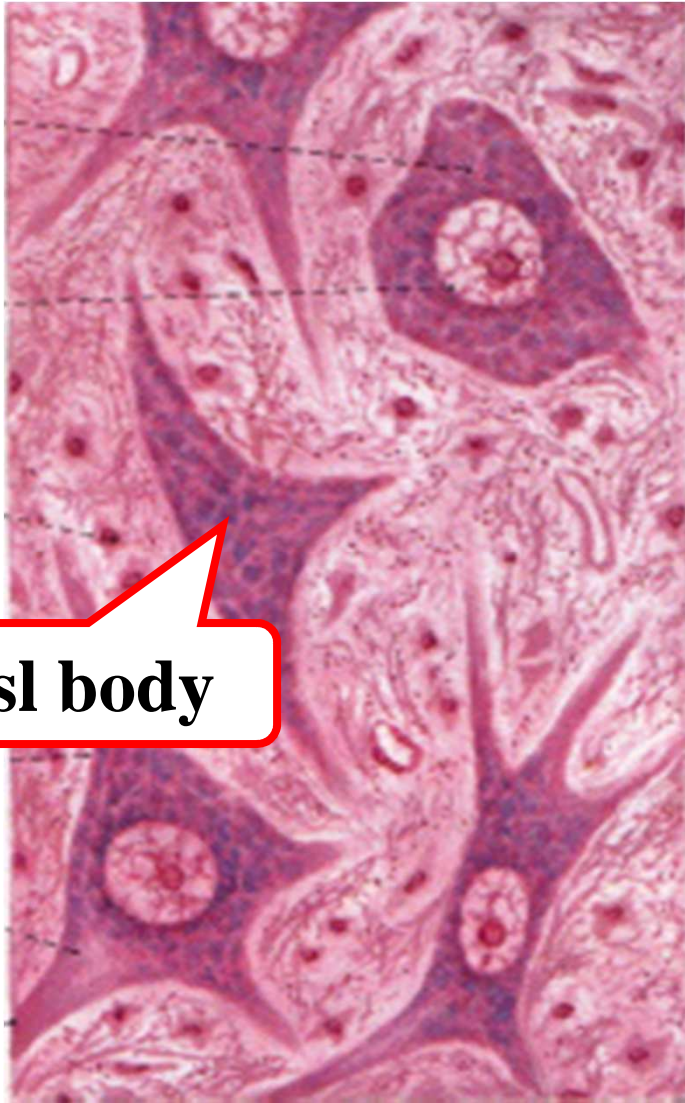Cell body: Perikaryon

- (1) Cell membrane: the structure is as the same as the normal cell. It functions in getting the stimuli and integration and conducting the nerve impulse.
- (2) The **nucleus is large and pale** with H-E stain, prominent nucleoli are very clear.



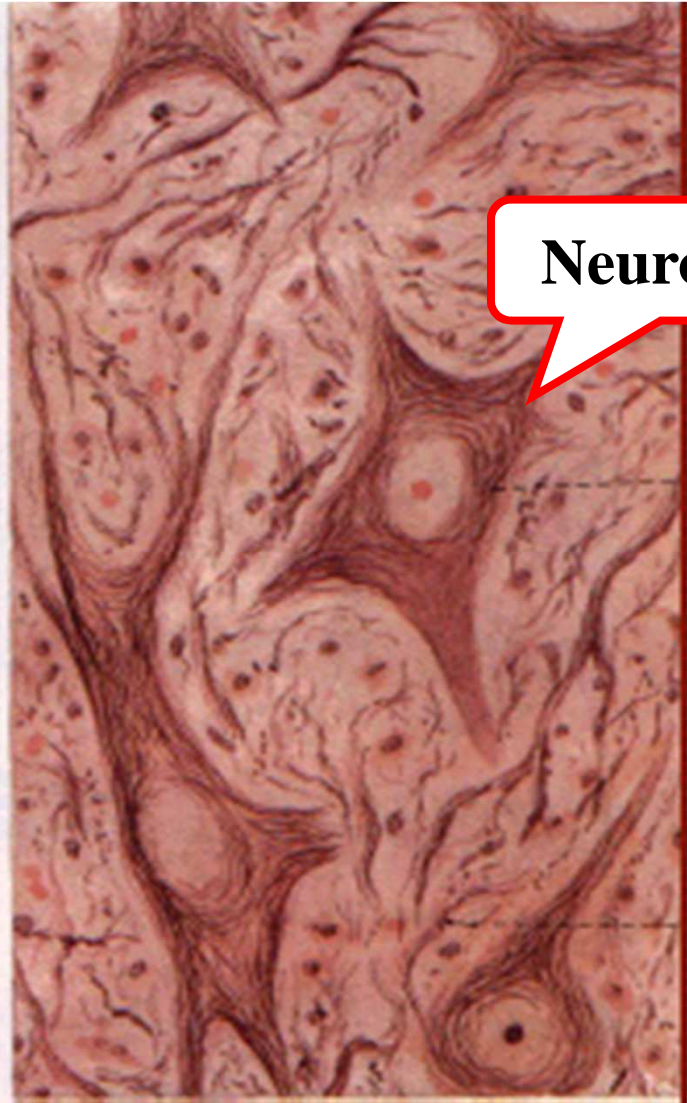Cell body: Perikaryon

(3)Cytoplasm: the cytoplasm has some distinctive characteristics not seen in other cells. The cytoplasm is basophilic and full of neurofibrils.



Nissl body

H-E stains

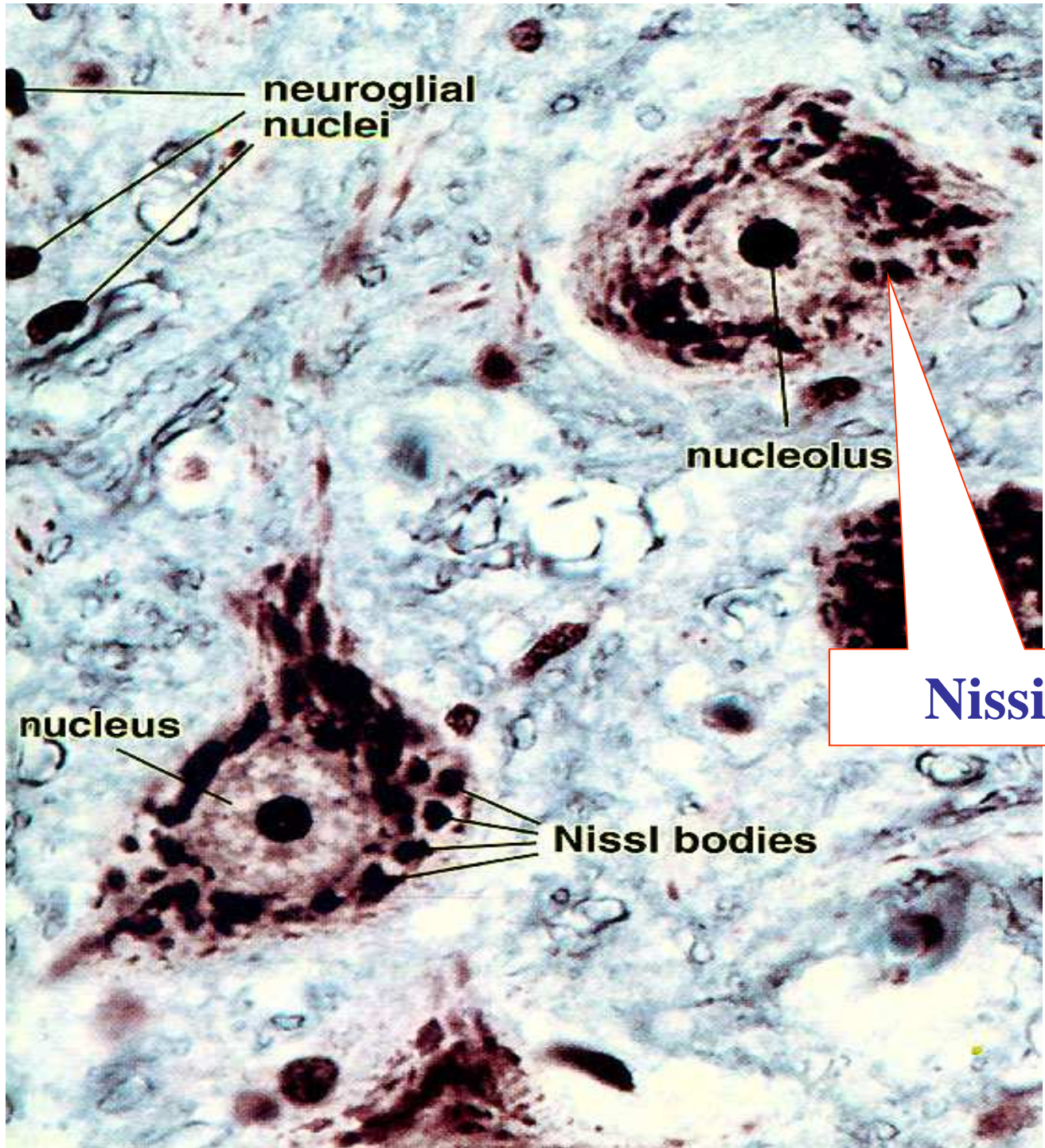


Neurofibril

Silver nitrate

Cell body: Perikaryon

Nissl bodies: The cytoplasm shows the presence of a granular material that stains intensely with basic dyes; this material is the **Nissl substance (also called Nissl bodies or granules).**



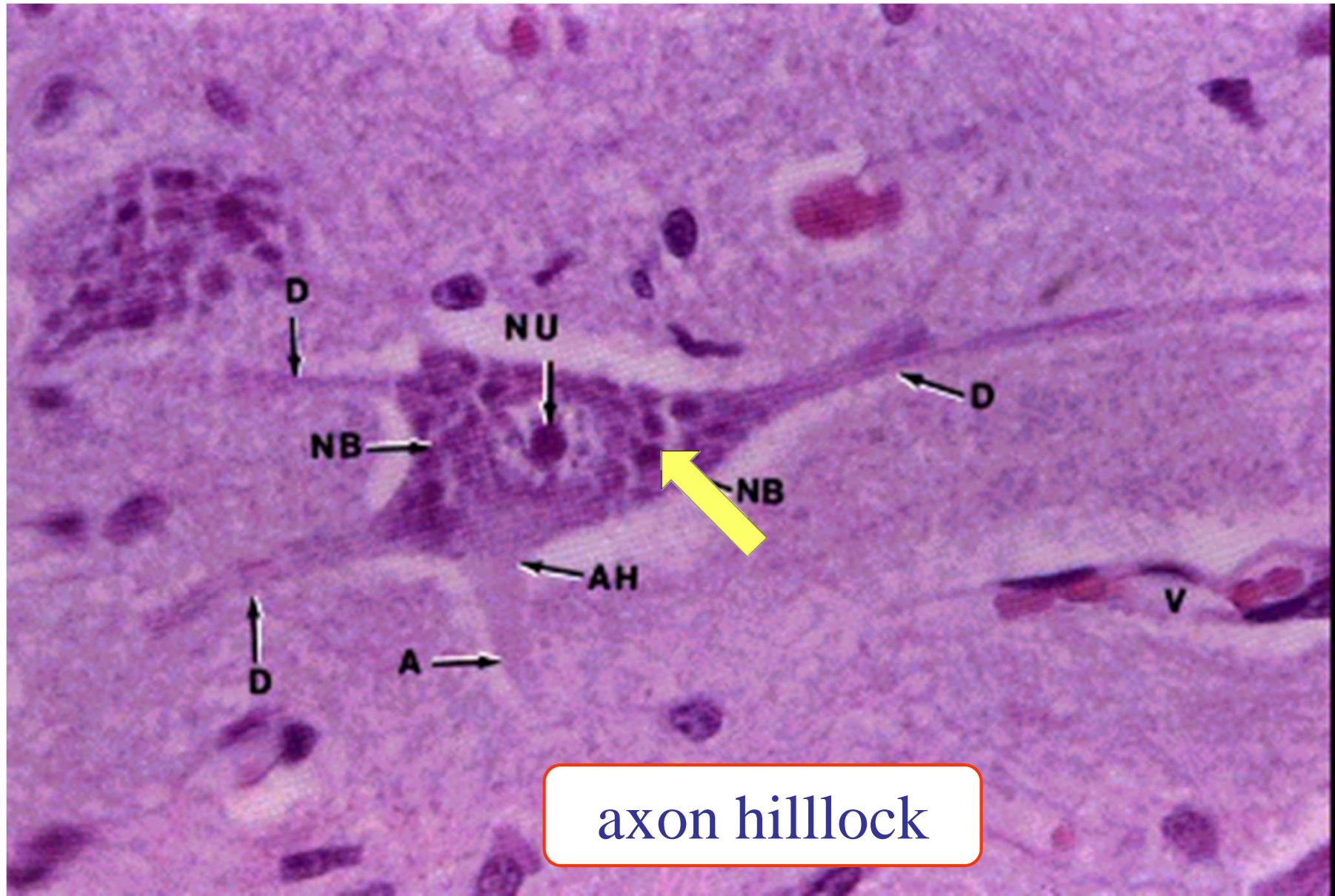
neuroglial
nuclei

nucleolus

nucleus

Nissl bodies

Nissil body



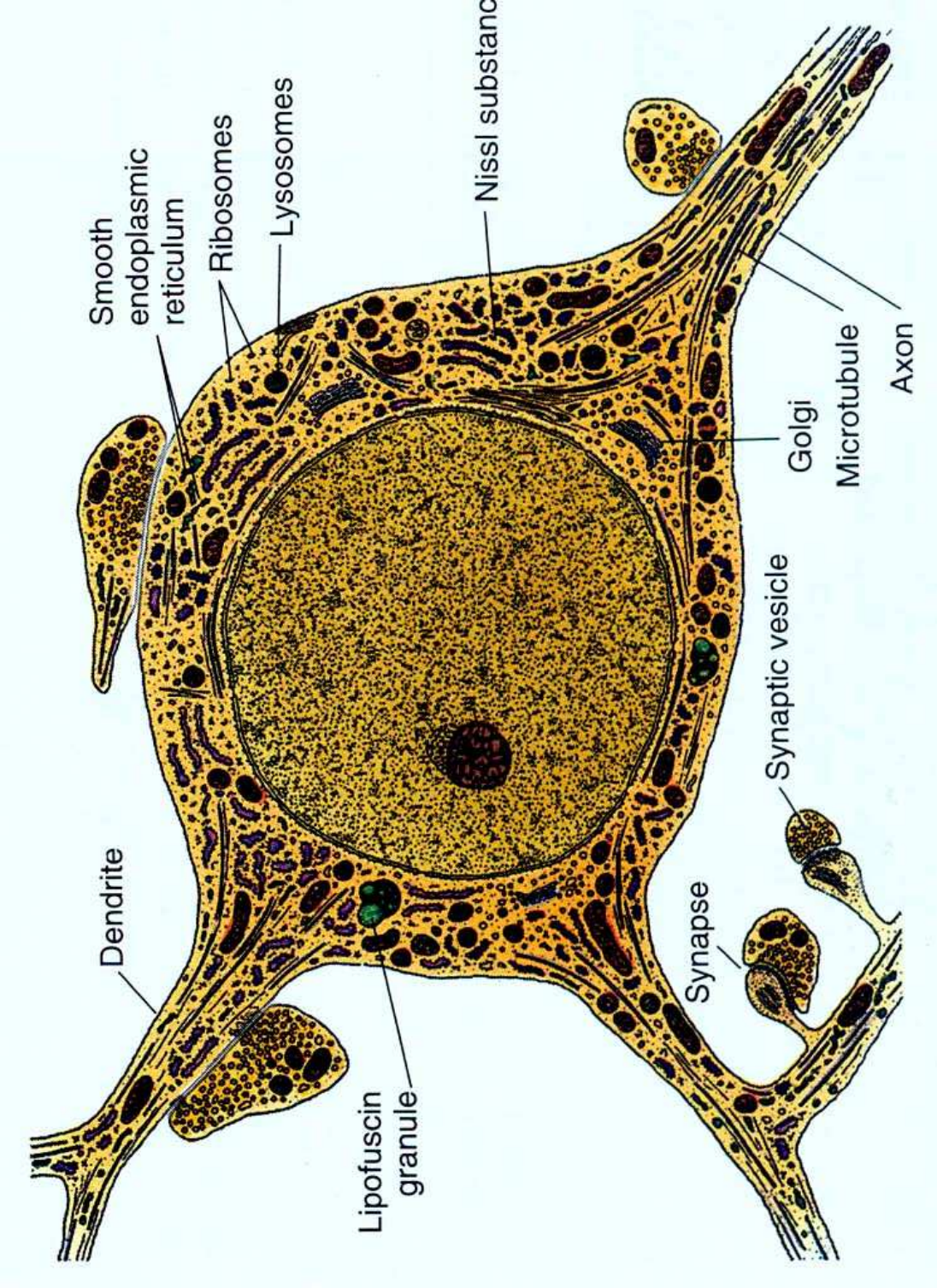
axon hillock

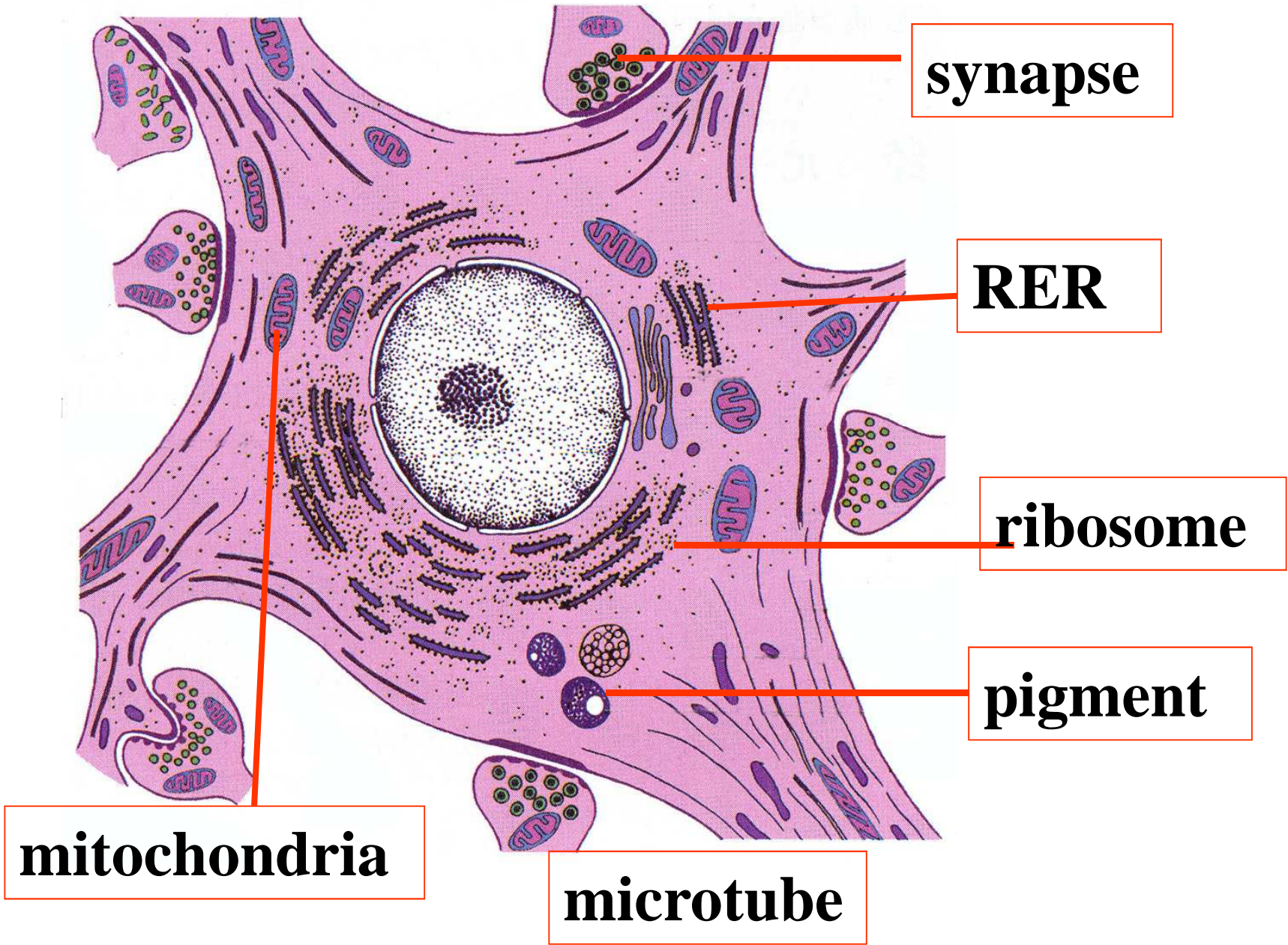
Neurofibrils

Cell body: Perikaryon

- **Neurofibrils are thin black fibers observed in LM with silver nitrate slides, which is composed of microtubule and filaments in EM.**

EM

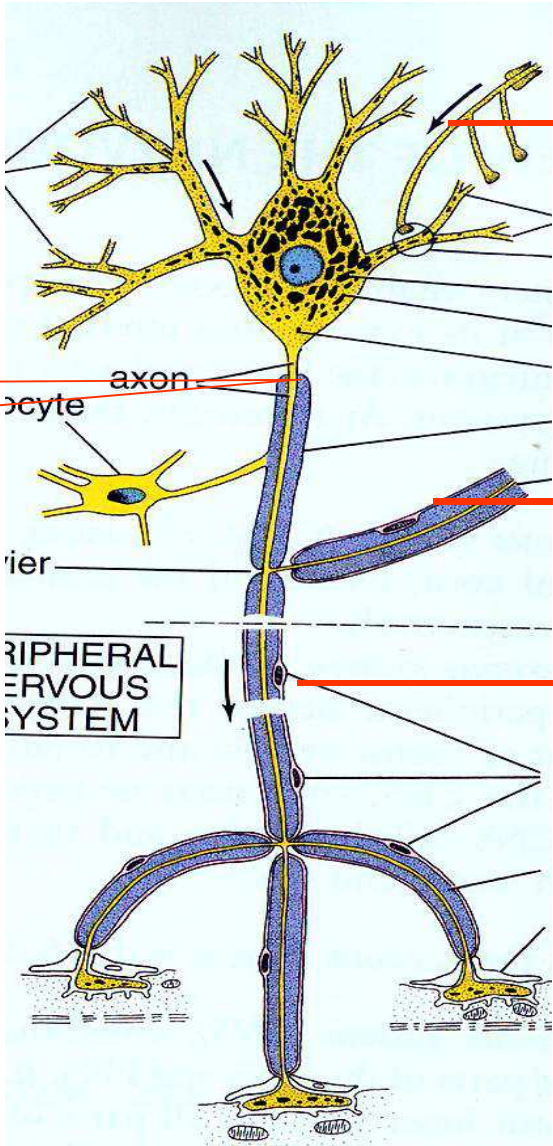




Neurites or processes

The processes arising from the cell body of a neuron are called **neurites**. Most neurons give off a number of short branching processes called **dendrites** and one longer process called **an axon**.

Cell body



Dendrites

collaterals

Axon

Nissl body

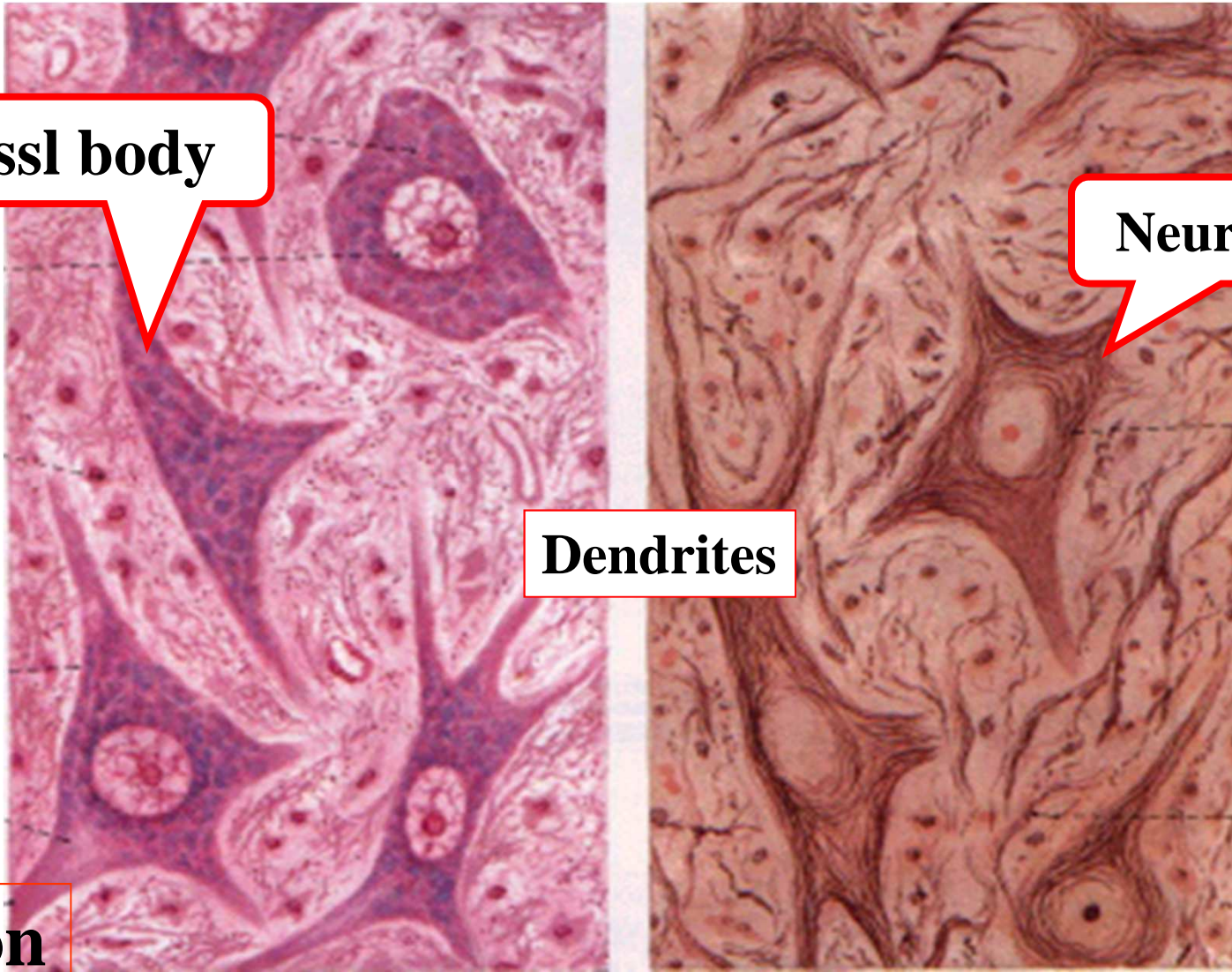
Neurofibril

Dendrites

Axon

H-E stains

Silver nitrate

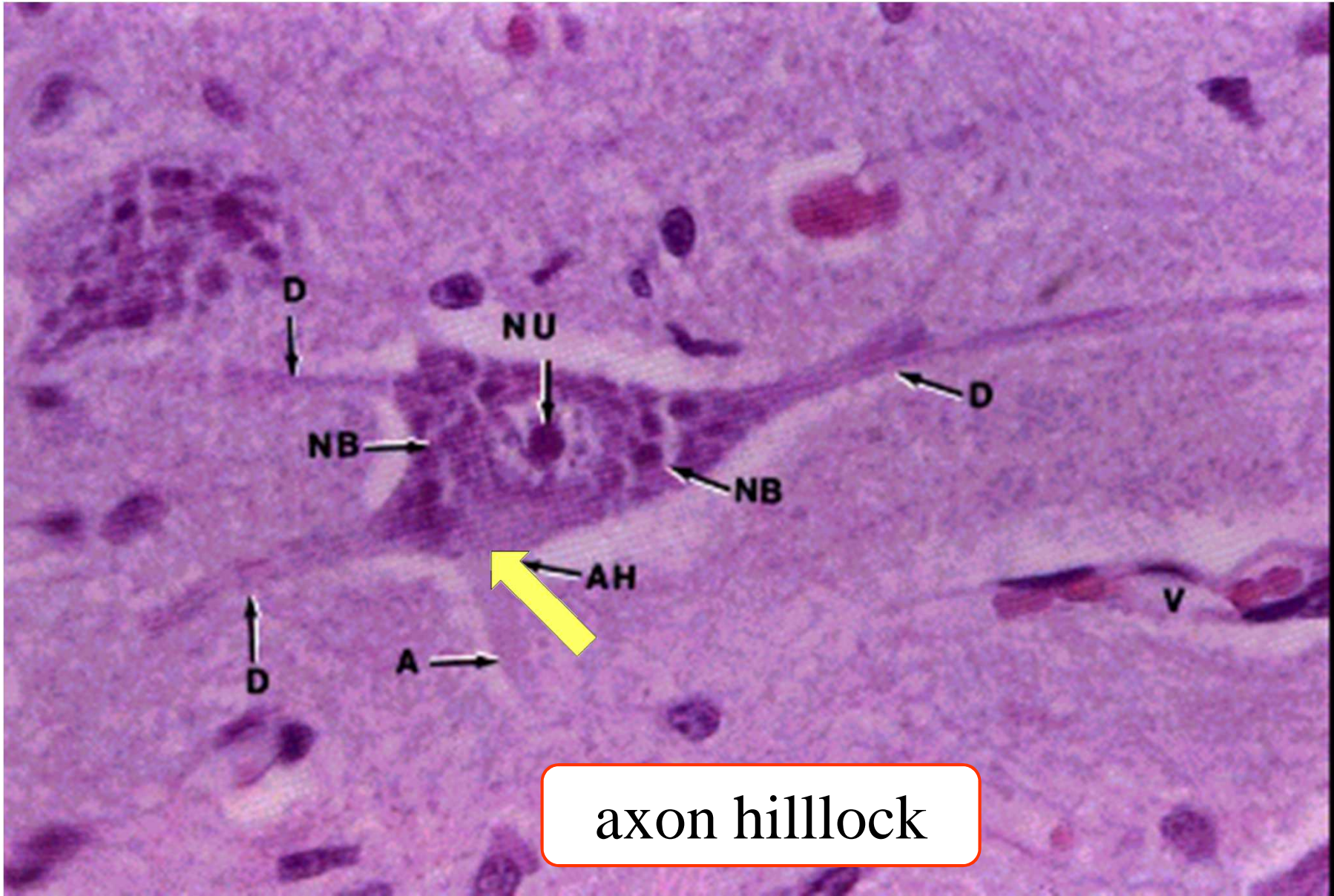


Dendrites

The dendrites are characterized by the fact that they terminate near the cell body. They are irregular in thickness, and Nissl granules extend into them. They bear numerous small spines which are of variable shape.

■ Axon

- Every neuron has only one long thin process or axon which arises from a special region or axon hillock, which is devoid of Nissl bodies. It carries the impulse received by the neuron to distant region.



axon hillock

An axon may have not much branches than that of dendrites. If branches, that arise near the cell body and lie at right angles to the axon are called **collaterals**. At its termination the axon breaks up into a number of fine branches called **telodendria** which may end in small swellings (terminal boutons).

The axon is identified according to the axon hillock with LM. The part of the axon just beyond the axon hillock is called the initial segment.

Neurites or processes

Dendrites

many

short

irregular in thickness

Nissl granules

spines

impulse towards the soma

Axons

one

long

uniform in diameter

No Nissl substance

axon hillock

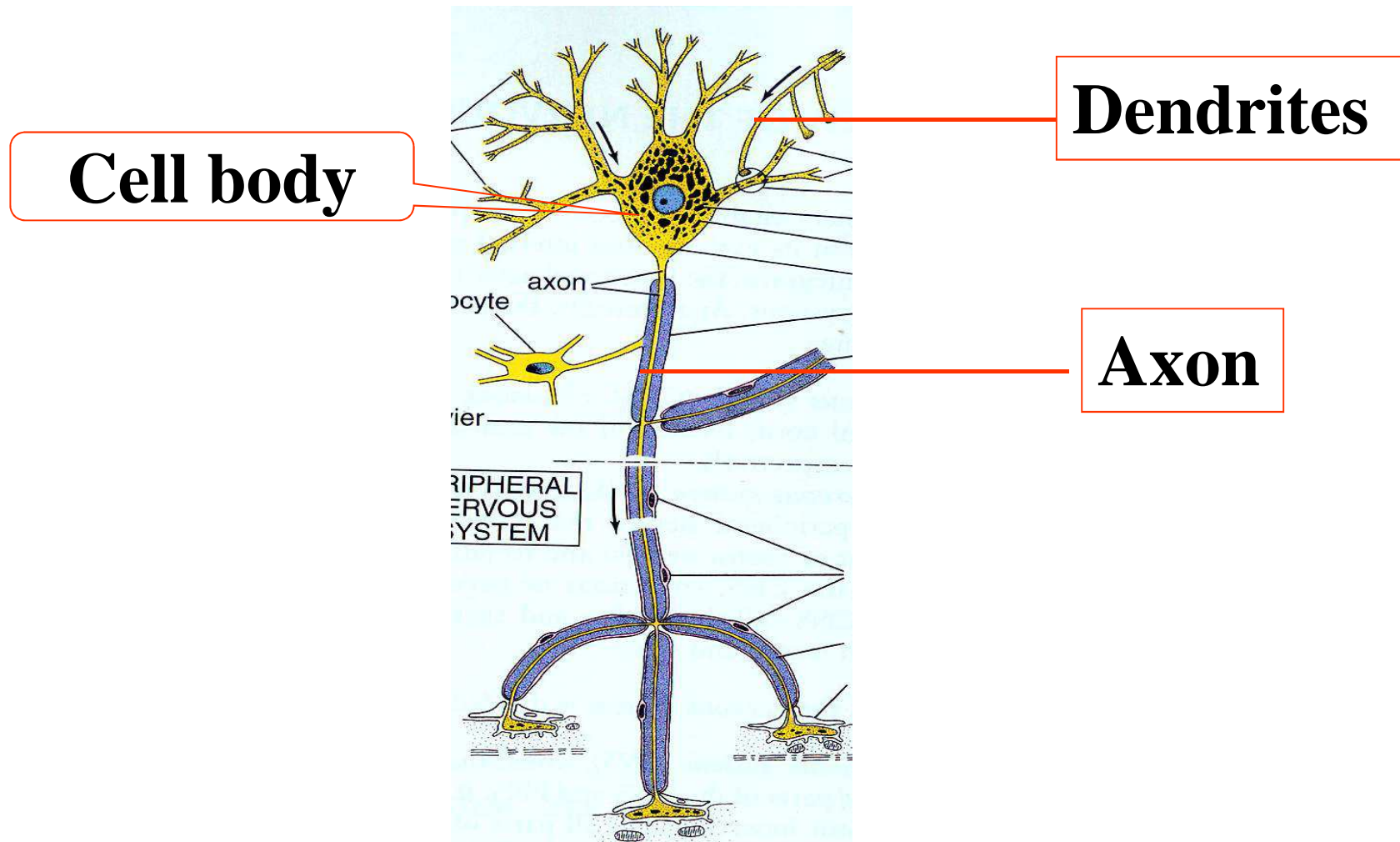
away from the cell body

Identification of dendrites from axon

- 1) morphology
- 2) Axon hillock in LM
- 3) Dendrites have microtubule associated protein (MAP-2) in immunocytochemically, not present in axons.

distinguished from axons

2. Classification of neuron



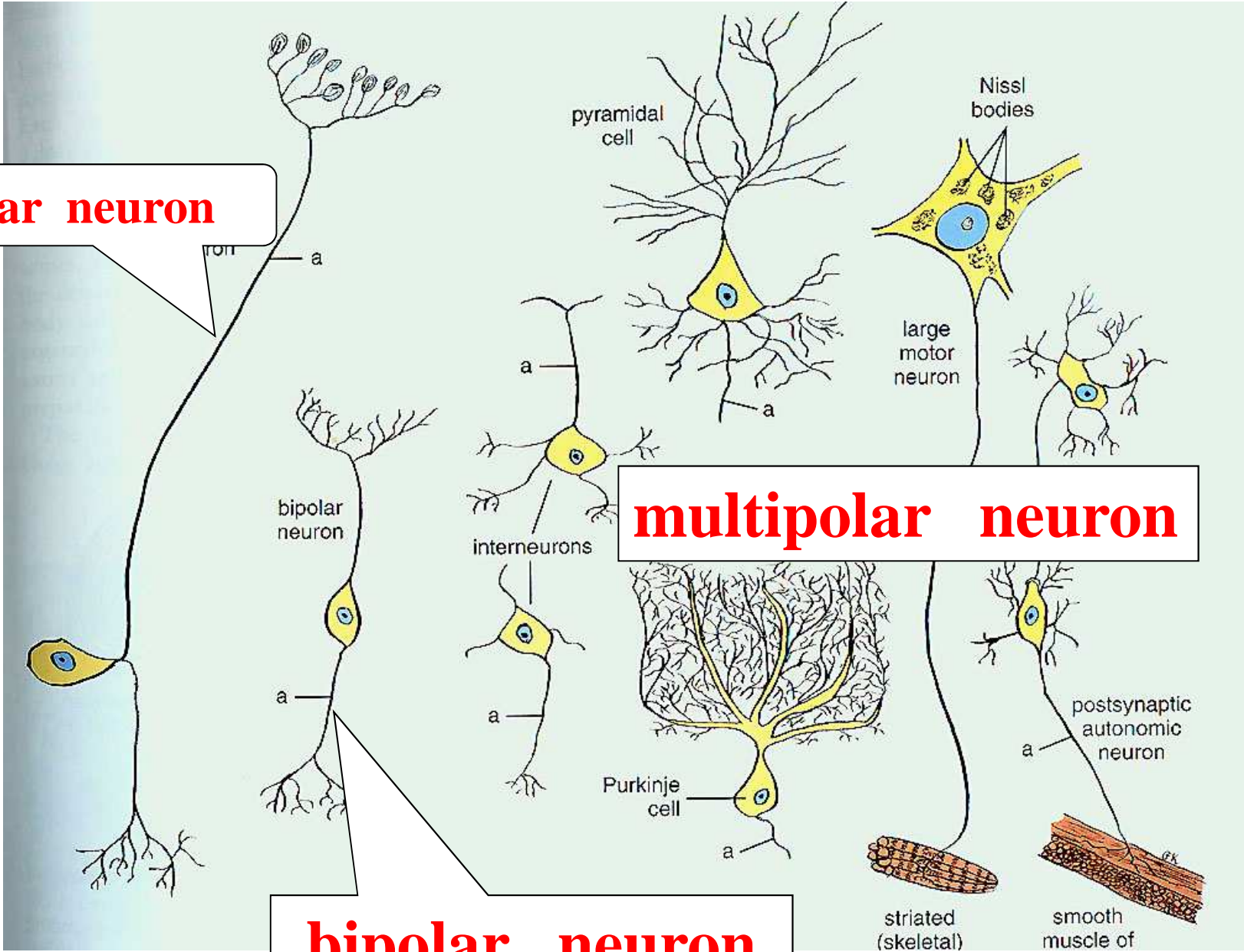
- **1) According to the number of the processes**

unipolar, or pseudounipolar neuron

bipolar neuron

multipolar neuron

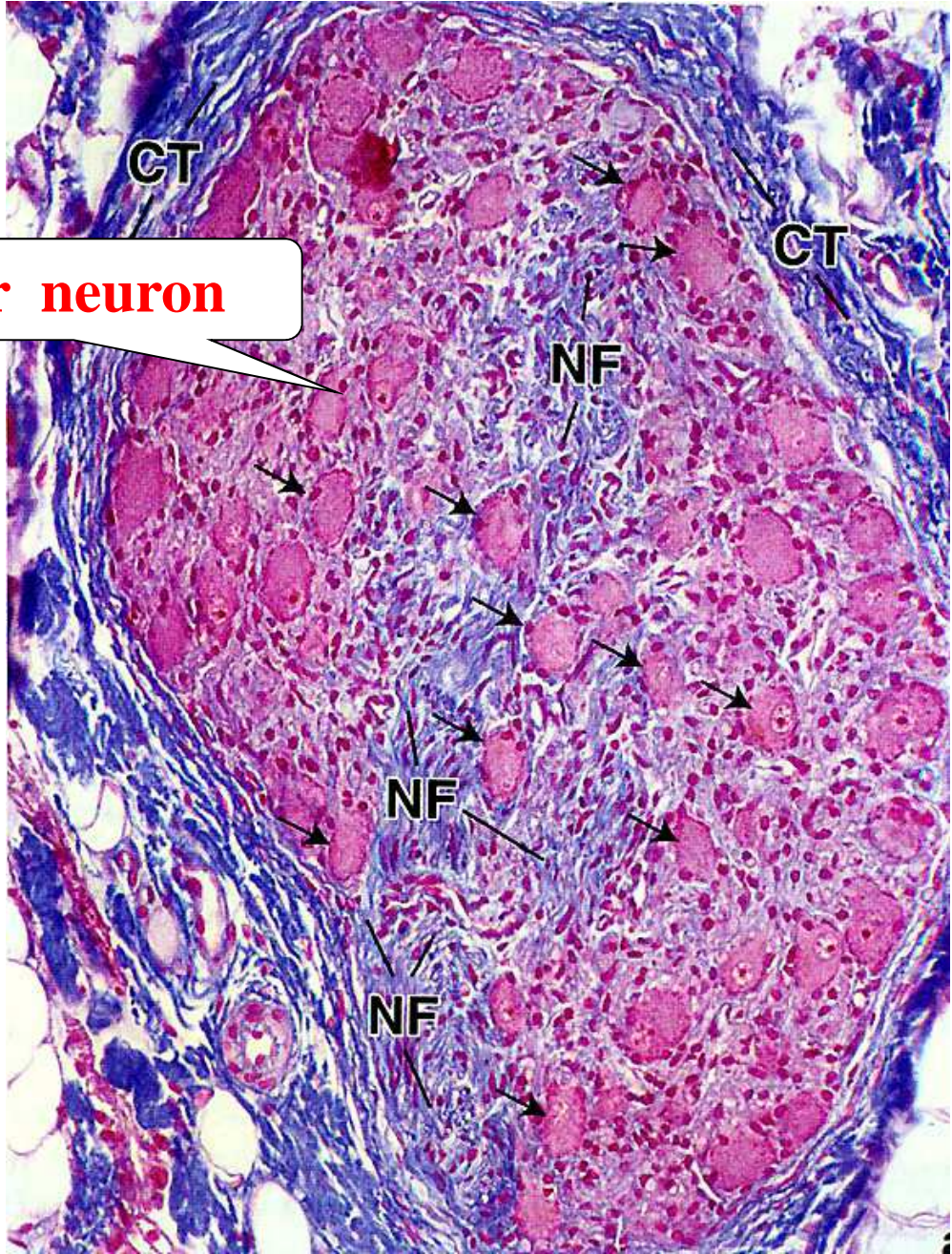
Unipolar neuron



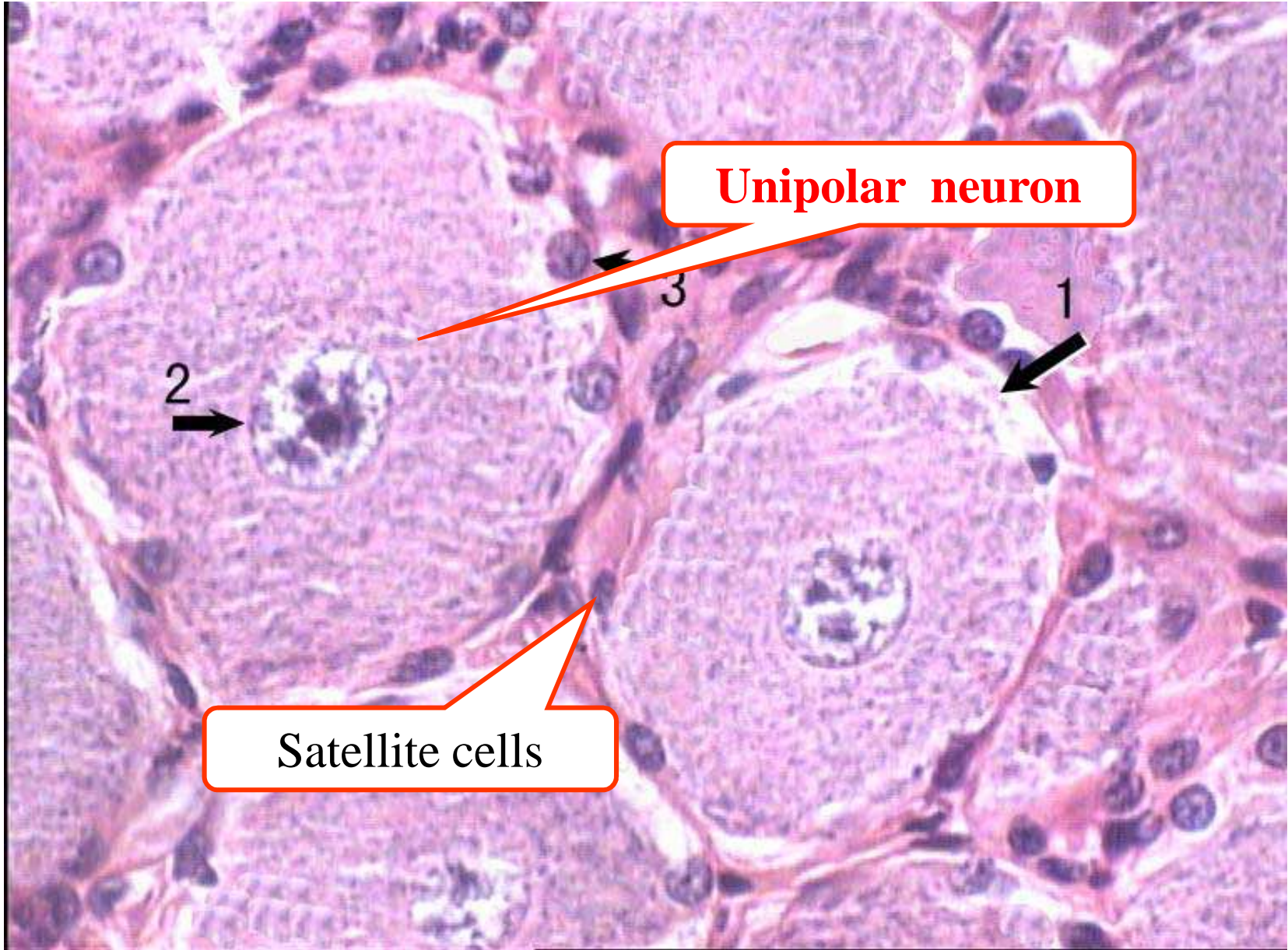
multipolar neuron

bipolar neuron

Unipolar neuron



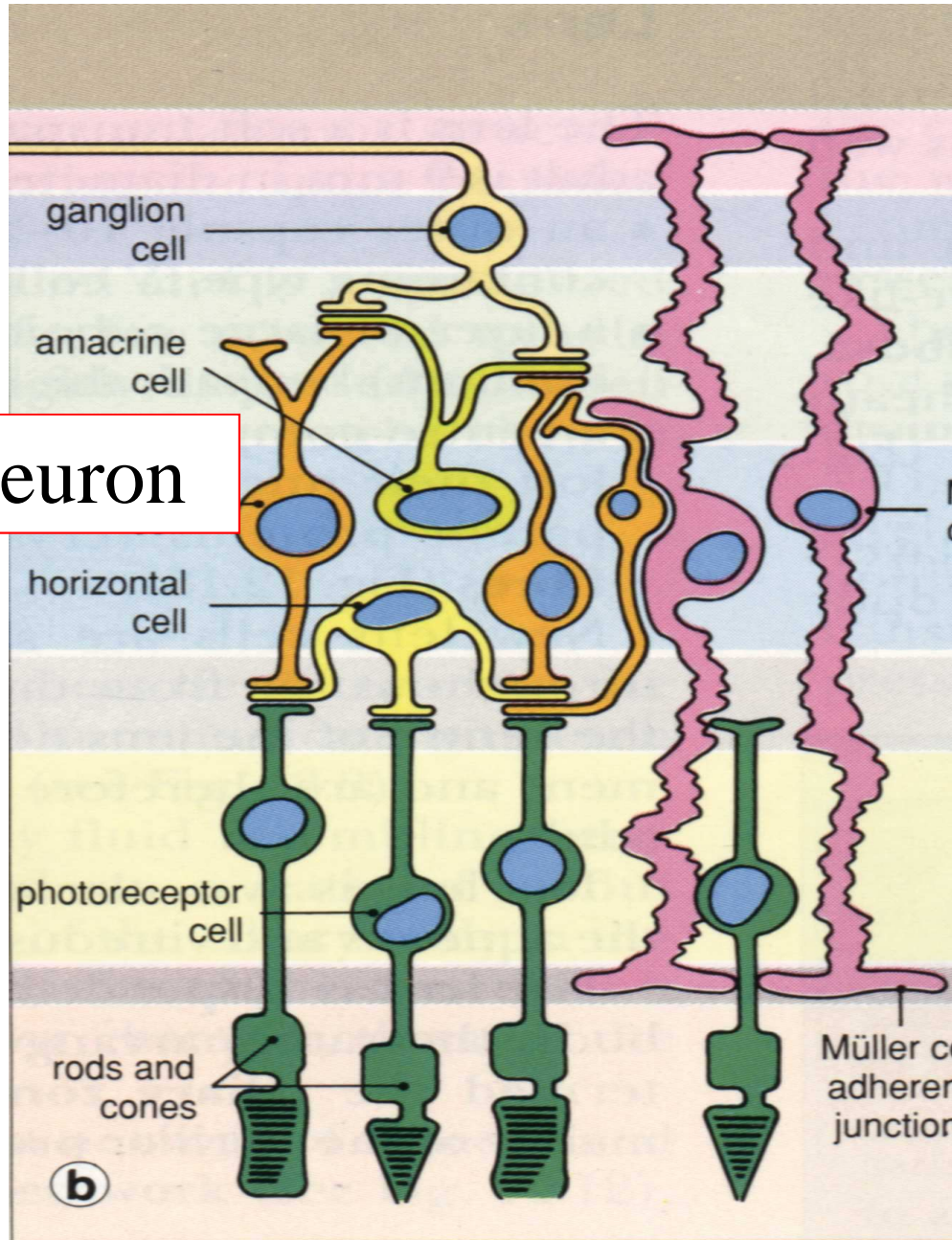
Spinal ganglia



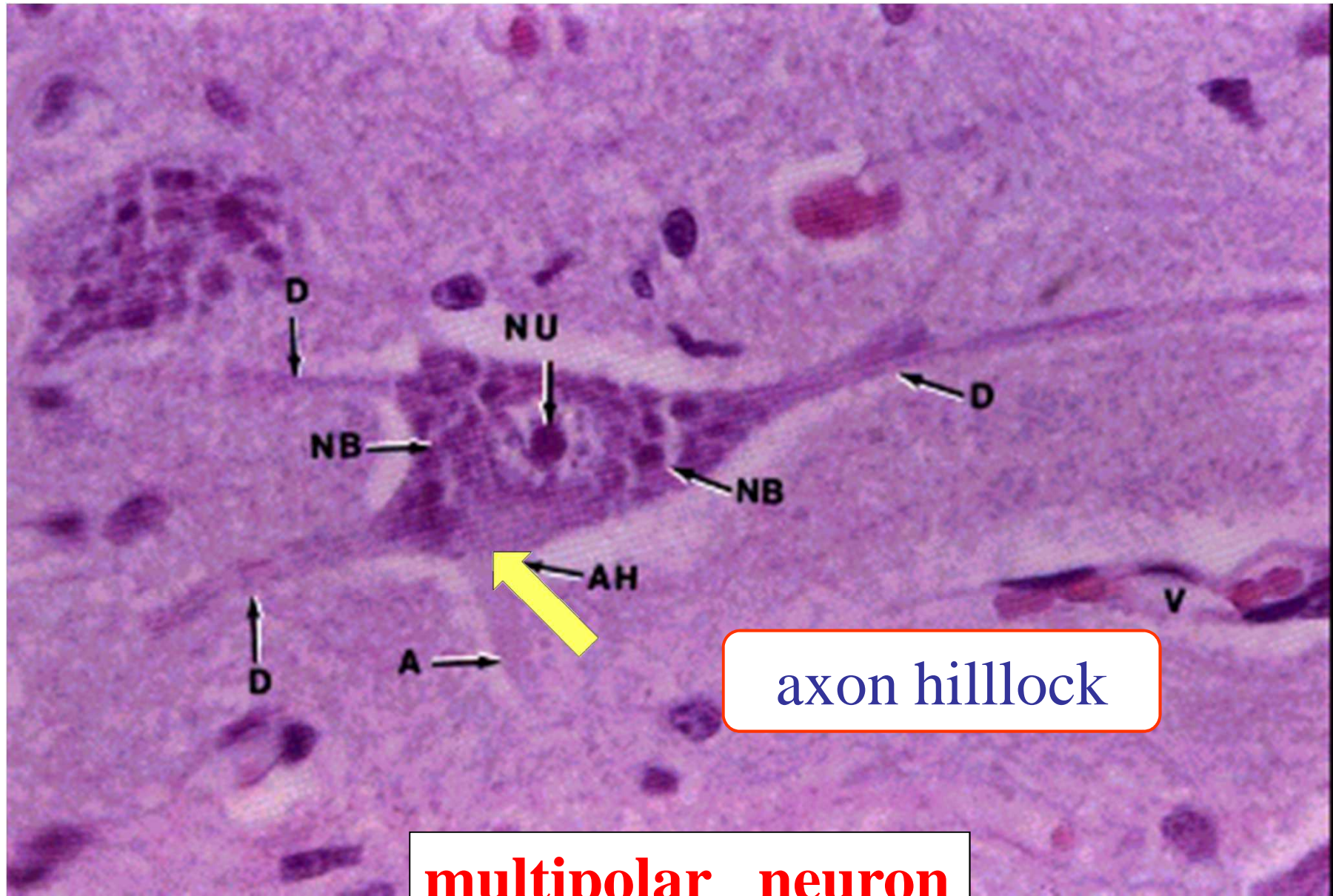
Unipolar neuron

Satellite cells

Bipolar neuron



Retina
of eye



axon hillock

multipolar neuron